

CASE REPORT

Permanent Bilateral Sudden Sensorineural Hearing Loss after Acute Abdominal Surgery under General Anesthesia

Erkan Soylu, Seyfi Emir, Yavuz Selim Yildirim

Medipol University Hospital, Department of Otorhinolaryngology Head and Neck Surgery, İstanbul, Turkey (ES)

Elazığ Research and Training Hospital, Department of General Surgery, Elazığ, Turkey (SE)

Bezmialem Vakıf University, Faculty of Medicine, Department of Otorhinolaryngology Head and Neck Surgery İstanbul (YSY)

Sudden sensorineural hearing loss can occur after both otolaryngological and non otolaryngological procedures. Sudden sensorineural hearing loss (SNHL) is a well-recognized phenomenon that is attributed to a variety of etiologies. After cardiopulmonary bypass surgery has been well reported. But this report adds to the literature additional case of sudden permanent bilateral SNHL after acute non-otology, non-cardiopulmonary, non-spine surgery. Possible etiologic factors and the management of sensorineural hearing loss following anesthesia are discussed.

Submitted : 14 April 2012

Accepted : 17 May 2012

Introduction

Sudden sensorineural hearing loss defined as hearing loss of at least 30 dB in three sequential frequencies in the standard pure-tone audiogram over 3 days or less.^[1] Idiopathic sudden sensorineural hearing loss (SNHL) is an unusual phenomenon with a reported incidence of five to 20 cases in 100,000 people per year. Sudden SNHL after cardiopulmonary bypass has been well described, with an estimated incidence of one in 1000 cases.^[2] However there are small than 50 cases of sudden SNHL after general anesthesia (excluding bypass cases) for nonotologic surgery in the English literature, to which we add one.^[3] Reports of bilateral permanent SNHL after non-otologic non-cardiac surgery are very rare. We review these cases and the proposed pathophysiology of hearing loss after general anesthesia.

Case Report

A 52 year-old woman who was admitted to the emergency room with nausea, vomiting and abdominal pain. Physical examination revealed abdominal distension and diffuse tenderness. Her past medical history was unremarkable, and her hematologic studies were normal except for an elevated white blood cell count of 14,600. Radiographic imaging demonstrated a view of “omega-ans”. Patient was diagnosed volvulus and admitted for emergency detorsion operation. There were no reports of previous general anesthesia. Preoperative history and laboratory studies were unremarkable. For induction anesthesia with thiopental sodium (5-6 mg / kg), fentanyl (1 µg / kg), lysothion (1 mg/kg) was performed. General anesthesia was maintained with a mixture of NO, oxygen and desflurane. The patient subsequently underwent open technique and sigmoid necrosis was removed then

Corresponding address:

Yavuz Selim Yildirim

Bezmialem Vakıf University, Faculty of Medicine, Department of Otorhinolaryngology

and Head and Neck Surgery İstanbul, Adnan Menderes Bulvarı Vatan Caddesi 34093 Fatih/İstanbul.

Phone: +90 212 453 17 10

Fax: +90 212 621 75 80 TURKEY

e-mail: dryavuzselim@yahoo.com

Copyright 2005 © The Mediterranean Society of Otolaryngology and Audiology

primary anastomosis was performed. There were no surgical complications. During the operation time 1000 cc saline and 1000 cc isolyte solutions were given. Estimated blood loss was 50 mL; operative duration was 220 minute. No episodes of hypotension were observed.

The course of the anesthetic was uneventful, and hemodynamic parameters remained within normal limits throughout the perioperative period. Her blood pressure in the operating room was never lower than 90/60 nor higher than 140/90. Her oxyhemoglobin saturation values via pulse oximetry (SpO₂) were from 99% to 100%, except upon his arrival to the operating room, when it was 95% while breathing room air.

Postoperative surgical examination was normal in the abdomen and surgical wound; however, the patient complained of hearing loss in her both ear tinnitus and aural fullness. An otolaryngology consultation was obtained. Examination revealed normal tympanic membranes and external auditory canals bilaterally, and a tuning fork test indicated that Weber no lateralized to the right side or left side and Rinne produced air better than bone conduction bilaterally, suggesting a sensorineural hearing loss on the bilaterally. A pure-tone audiogram was obtained, demonstrating bilateral severe SNHL across the entire frequency range (Fig. 1). Magnetic resonance imaging of the brain and internal auditory canal was normal. Postoperative neurologic examination was normal. Doppler ultrasound of carotid and vertebral artery was normal.

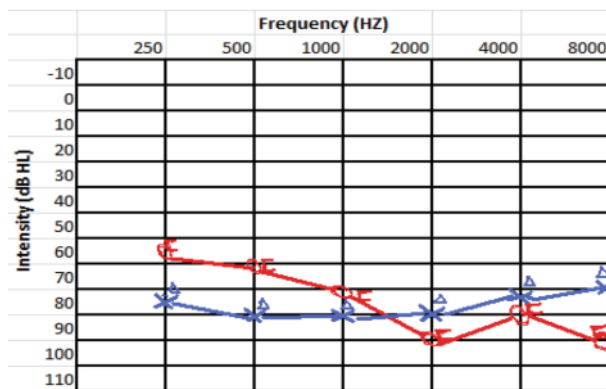


Fig 1: Audiogram at one year follow-up was the same as audiogram in early postoperative period. (Red: Right Ear, Blue: Left Ear, O: Right Ear Air Conduction, X: Left Ear Air Conduction, □: Right Ear Bone Conduction, ▲: Left Ear Bone Conduction)

A combined regimen of steroids (methylprednisone 1 mg/kg/day followed by gradual tapering of dose), plasma expander (low molecular weight dextran 500 ml/day), acyclovir (1 g/day), vitamin B1, B6, B12 complex (500 mg/day) and aspirin (100 mg/day) was administrated until two weeks. Serial audiograms were performed. Until day three, there was no improvement. Intratympanic steroid injections and hyperbaric oxygen therapy were considered, the patient accept this treatment. Intratympanic dexamethasone with grommet tube (4 times/two weeks) and hyperbaric oxygen therapy (20 sessions/two weeks) have been performed. Although all the current treatment strategies with Sudden SNHL, the patient had no subjective and objective improvement in his hearing at the time of discharge and at his follow-up visit 1 year later. Currently the patient uses digital hearing aid on the right ear.

Discussion

Although the etiology of hearing loss associated with general anesthesia often cannot be ascertained, there are a number of potential etiologies: changes in middle ear pressure, vascular pathology, CSF pressure changes, embolism, ototoxic drugs, and other miscellaneous causes.^[4]

Most postoperative nonotologic cases of SNHL occur in patients with cardiopulmonary bypass. In a series of 7000 patients with cardiopulmonary bypass, Plasse et al.^[5] observed a 1 of 1000 incidence of postoperative SNHL. Most postoperative cases non-otologic, non-cardiopulmonary SNHL attributed spine surgery.^[6] But our cases have non-otologic, non-cardiopulmonary and non- spine surgery, in addition to hearing loss permanent, bilateral and profound.

Excessive or sudden changes in middle ear pressure can disrupt the tympanic membrane, the round window, and the conducting structures. Excessive middle ear pressure can cause the round window to rupture, resulting in significant hearing loss. It was postulated that during vigorous mask ventilation, excessive pressure was suddenly transmitted through the Eustachian tube causing the middle ear injuries.^[4,7] The degree of intratympanic pressure fluctuation is a function of N2O concentration and its rate of change. Several cases of middle ear injury have been described as resulting from

sudden changes in intratympanic pressure during general anesthesia with N₂O. Further, the patency of the Eustachian tube may play a role in potential injury during N₂O anesthesia. During N₂O elimination, Eustachian tube obstruction can result in significant negative middle ear pressure and tympanic perforation.^[4]

A vascular pathogenesis is another possible mechanism for hearing impairment after general anesthesia. Injury to the inner ear's microcirculation, either in the stria vascularis or the vessels of the spiral ligament, leads to ischemic damage of the hair cells and hearing loss.^[8] Sudden sensorineural hearing loss is sometimes associated with; Meniere disease, Endolymphatic hydrops, immune-mediated inner-ear disorder and systemic immune-mediated diseases. Many drugs have been associated with ototoxicity, but the hearing loss is usually slowly evolving.^[9]

Patients with sudden sensorineural hearing loss often delay seeking medical attention, or might present to a range of specialties, including primary care, otolaryngology, audiovestibular medicine, and internal medicine. In primary care and non-specialist departments, patients can be inappropriately reassured, without investigation, in the mistaken view that the loss is attributable to middle-ear dysfunction secondary to upper respiratory tract infection. Detailed investigation will show a specific cause in about 10% of patients.^[10]

Oral corticosteroids are widely used, although the supporting evidence is weak. Steroids have many effects in the inner ear, and whether suppression of an immune response, changes in microvascular circulation, mineralocorticoid effects, or a decrease in endolymphatic pressure are beneficial is unclear.^[11] Intratympanic dexamethasone has been used in patients who did not respond to systemic steroid therapy. Evidence for the efficacy of intratympanic dexamethasone in the treatment of sudden sensorineural hearing loss is conflicting. A Cochrane systematic review is underway to address this issue.^[12]

In cases in which a vascular cause is not excluded, empiric low-dose oral aspirin could be of benefit. Several other treatments have been investigated because of speculation about pathogenesis. Treatment with antiviral agents (eg, aciclovir, valaciclovir) has not shown benefit in randomised controlled trials.^[13] A systematic review^[14]

showed no evidence of benefit with hyperbaric oxygen therapy. But Muazzi et al.^[15] showed that salvage hyperbaric oxygen therapy appeared to improve patients' pure tone hearing thresholds, particularly at low frequencies. In this reason; our patient who had received hyperbaric oxygen therapy for bilateral sudden SNHL.

This patient's hearing seemed to be normal prior to surgery. A review of the surgical procedure and anesthesia record revealed no predisposing events which might account for the hearing loss. No known ototoxic medications were used during or after surgery nor taken preoperatively.

Conclusions

Sudden sensorineural hearing loss following nonotologic, non-CPB, non-spine surgery is rare, and its cause remains unknown. The report of SSHL following non-otologic, non-CPB, and non-spine surgery raises the possibility that the apparent association can be known. If the specific etiology can be identified, treatment may be effective in certain cases.

Conflict of Interest: None Funding source, financial disclosures: none

References

1. Park P, Toung JS, Smythe P, Telian SA, La Marca F. Unilateral sensorineural hearing loss after spine surgery: Case report and review of the literature. *Surg Neurol*. 2006; 66:415-8; discussion 418-9.
2. Walsted A, Andreassen UK, Berthelsen PG, Olesen A. Hearing loss after cardiopulmonary bypass surgery. *Eur Arch Otorhinolaryngol*. 2000; 257:124-7.
3. Punj J, Pandey R, Darlong V. Sensorineural hearing loss after general anaesthesia: 52 cases reported until now! *Anaesthesia*. 2009; 64:226.
4. Sprung J, Bourke DL, Contreras MG, Warner ME, Findlay J. Perioperative hearing impairment. *Anesthesiology* 2003; 98:241-57.
5. Plasse H, Spencer FC, Mittleman M, et al. Unilateral sudden loss of hearing: an unusual complication of cardiac operation. *J Thorac Cardiovasc Surg* 1980; 79:822-6.
6. Park P, Toung JS, Smythe P, Telian SA, La Marca F. Unilateral sensorineural hearing loss after spine surgery: Case report and review of the literature. *Surg Neurol*. 2006; 66:415-8.

7. Girardi FP, Cammisa FP Jr, Sangani PK, Parvataneni HK, Khan SN, Grewal H, et al. Sudden sensorineural hearing loss after spinal surgery under general anesthesia. *J Spinal Disord.* 2001; 14:180-3.
8. Velazquez FA. Hearing loss after general anesthesia for cecectomy and small bowel resection. *AANA J.* 1992; 60:553-5.
9. Schreiber BE, Agrup C, Haskard DO, Luxon LM. Sudden sensorineural hearing loss. *Lancet.* 2010 3;375:1203-11.
10. Penido NO, Cruz OL, Zanoni A, Inoue DP. Classification and hearing evolution of patients with sudden sensorineural hearing loss. *Braz J Med Biol Res* 2009; 42: 712–16.
11. Garcia Berrocal JR, Ramirez-Camacho R. Immune response and immunopathology of the inner ear: an update. *J Laryngol Otol* 2000; 114: 101–07.
12. Plontke SK, Meisner C, Caye-Thomasen P, Parnes L, Agrawal S, Mikulec T. Intratympanic glucocorticoids for sudden sensorineural hearing loss (Protocol). *Cochrane Database Syst Rev* 2009; 4: CD008080.
13. Conlin AE, Parnes LS. Treatment of sudden sensorineural hearing loss: II. A Meta-analysis. *Arch Otolaryngol Head Neck Surg* 2007; 133: 582–86.
14. Bennett MH, Kertesz T, Yeung P. Hyperbaric oxygen for idiopathic sudden sensorineural hearing loss and tinnitus. *Cochrane Database Syst Rev* 2007; 1: CD004739.
15. Muzzi E, Zennaro B, Visentin R, Soldano F, Sacilotto C. Hyperbaric oxygen therapy as salvage treatment for sudden sensorineural hearing loss: review of rationale and preliminary report. *J Laryngol Otol.* 2010; 124:e2. Epub 2009 Nov 30.