

CASE REPORT

Posttraumatic Bilateral Carotid-Cavernous Fistula

Wiatr Maciej, Popiela Tadeusz, Brzegowy Pawel, Skladzien Jacek, Urbanik Andrzej, Strek Pawel, Morawska Agnieszka, Przeklasa-Muszynska Anna

Department of Otolaryngology, Head and Neck Surgery; Jagiellonian University, Cracow, Poland (WM, SJ, SP, MA)

Department of Radiology, Jagiellonian University, Cracow, Poland (PT, BP, UA)

Department of Anesthesiology, Jagiellonian University, Cracow, Poland (PMA)

The carotid-cavernous fistula is an abnormal connection between the internal carotid system and the cavernous sinus. The connection can be either spontaneous or resulting from a head injury. The clinical manifestation depends on the size and type of venous drainage. An effective method—and the safest one—is angiography with parallel embolisation of the visualised fistula. Because of difficult access and the risk of complications, neurosurgical treatment can be applied only to a limited extent.

We discuss symptoms and performed treatment in the patient with bilateral posttraumatic carotid-cavernous fistula. Intracranial embolisation with use of microembolisation coils is the first-choice treatment in the cases of carotid-cavernous fistulas. It is crucial to avoid increased vascular flow in the ophthalmic and cortical veins, as this would cause intensified ocular symptoms and greater risk of intracranial bleeding.

Bilateral carotid-cavernous fistulas evidently occur less frequently. The determinant of correct treatment of the bilateral changes is the maintenance of flow in the internal carotid arteries. For that reason, the procedure is connected with higher perioperative risk, and certain procedures, such as clipping the internal carotid arteries, are not considered. Obliterating the cavernous sinuses with microcoils seems to be the procedure of choice. Its effectiveness is very high, and functions are restored, an example of which is the patient described in our case.

Submitted : 29 October 2012

Revised : 02 February 2013

Accepted : 28 July 2013

Introduction

The carotid-cavernous fistula is an abnormal connection between the internal carotid system and the cavernous sinus. The connection can be either spontaneous or resulting from a head injury. In the vast majority of cases, it occurs spontaneously and its aetiology is unknown.

Spontaneous carotid-cavernous fistulas are connected to abnormalities in the cavernous sinus, atherosclerotic changes in the carotids, fibromuscular dysplasia, or

Ehlers-Danlos syndrome. Posttraumatic fistulas occur as a consequence of both blunt and penetrating injuries to the skull. The clinical manifestation depends on the size and type of venous drainage. Extensive symptomatology is observed, including visual disorder, exophthalmos, conjunctival congestion, malfunction of cranial nerves, intracranial bleeding (rarely) and others. Carotid-cavernous fistulas are not frequent complications resulting from head injury. The simultaneous bilateral occurrence of such an abnormality is extremely rare. Suspected fistula can be

Corresponding address:

Maciej Wiatr
Department of Otolaryngology
Head and Neck Surgery of the Jagiellonian University
Cracow, Poland, ul. Sniadeckich 2
Tel. 00 48 12 424 79 00
Fax 00 48 12 424 79 25
e-mail: mwiatr@mp.pl

Copyright 2005 © The Mediterranean Society of Otolaryngology and Audiology

diagnosed based on the typical clinical picture involving head trauma in the patient's medical history, unallocated buzzing noise in the head, exophthalmos, conjunctival congestion and visual disorder. The occurrence of the conditions specified above should incline the medical team towards diagnostics based mainly on vascular imaging for the purpose of exposing the abnormality and possibly also treating it at the same time. An effective method—and the safest one—is angiography with parallel embolisation of the visualised fistula. Because of difficult access and the risk of complications, neurosurgical treatment can be applied only to a limited extent. Carotid-cavernous fistulas rarely result from surgical treatment of the bony face; they are also infrequent in otorhinolaryngological practice. The fistulas have been described as a consequence of endoscopic surgery of the paranasal sinuses^[1-3].

Case Report

In mid-September 2009, a 42-year-old forester sustained head injury from a fall at work. A CT scan of the patient's head performed on the day of the accident did not reveal any abnormalities. Since that time, the patient reported a persistent buzzing noise in the head. In the following days, he was diagnosed with left

exophthalmos. A CT scan of the orbits exposed a broadened and lengthened superior ophthalmic vein on the right (in diameter, as compared to 0.23 cm on the left). Soft tissue thickening was observed as well (0.98 x) in the region of the superior orbital fissure. The CT image suggested varicose changes combined with posttraumatic thrombosis.

Three to four weeks following the injury, the patient began to complain of headache, growing left exophthalmos and pulsating noise that radiated to the left ear. Additionally, the patient reported impaired vision in the left eye and protanomalopia in the left eye when looking in all directions. The ophthalmological examination revealed left exophthalmos and diplopia in all directions except for looking straight. The patient was diagnosed with paresis of the cranial nerves III and VI on the left-hand side and dysfunction of the cranial nerve II on that side. Additional swelling and reddening of the left upper eyelid occurred.

An angio-CT of the head revealed asymmetrical broadening of the superior ophthalmic vein on the left to c.a. and bilateral expansion of the cavernous sinuses. Symptoms of thrombosis were not observed. The image aroused suspicion of a left-side carotid-cavernous fistula.

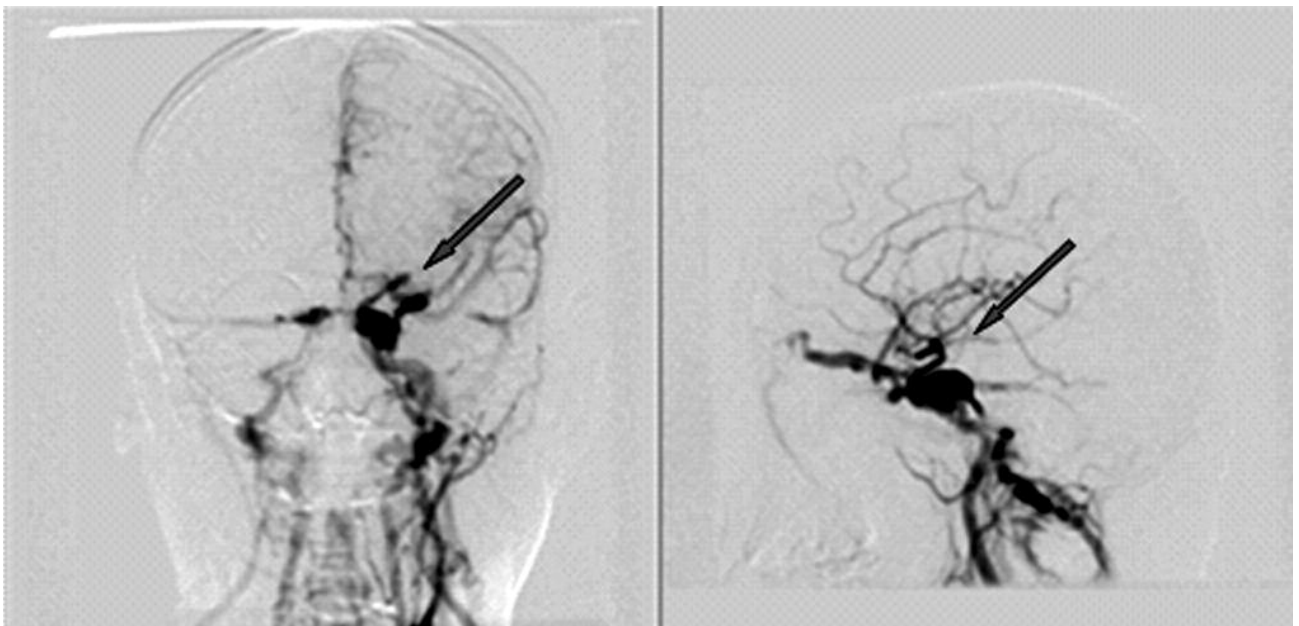


Figure 1. Bilateral carotid-cavernous fistulas (arrow) before treatment (frontal and sagittal plane). Right side—DSA.

In light of the obtained result, the diagnostic tests were extended to include the cerebral pan-angiography. The examination was carried out using the Seldinger technique, with puncturing of the right femoral artery. The contrast medium was applied selectively to both internal carotid arteries and to the vertebrobasilar system through the left vertebral artery. Bilateral carotid-cavernous fistulas were exposed in the initial endocavernous sections of the internal carotid arteries.

It was observed that the left-side fistula was much larger than the right-side fistula, with an entrance width of ca in the wall of the internal carotid artery. The outflow of blood from the broadened cavernous sinus on that side went into the ophthalmic vein through the basilar plexus and the petrosal sinuses to the internal carotid artery (Fig. 1).

The width of the entrance of the fistula on the right was estimated to be 4 mm. The outflow of blood on that side was mainly through the basilar plexus and the petrosal sinuses, and to a much lesser degree into the right ophthalmic vein (Fig. 2).

In light of the above information, the carotid-cavernous fistulas were embolised with coils.

The 5-F guiding catheter was introduced into the proximal region of the left internal carotid artery

through the right femoral artery using the Seldinger technique. Next, the coaxial microcatheter was introduced inside the left cavernous fistula through the internal carotid artery and the fistula in the artery wall. The cavernous sinus was filled with five embolisation microcoils (Matrix2). The broadened right cavernous sinus was embolised with 4 microcoils using an analogous procedure.

The control angiography revealed complete closure of the carotid-cavernous fistulas without inflow of the contrast medium into the cavernous sinuses or into the basilar plexus and the ophthalmic veins. The control angiography performed 6 months after the embolisation of the carotid-cavernous fistulas did not reveal any bilateral abnormalities (Fig. 3, Fig. 4).

The control ophthalmological examination did not show evidence of visual disorder; the patient regained recognition of the colour red, while the exophthalmos decreased. Diplopia was not observed.

Discussion

In the majority of cases, carotid-cavernous fistulas are caused by damage to the internal carotid artery in its endocavitary section. The fistula is observed in the cases of blunt head injuries, with or without skull base fracture, as well as after sustaining penetrating injuries.

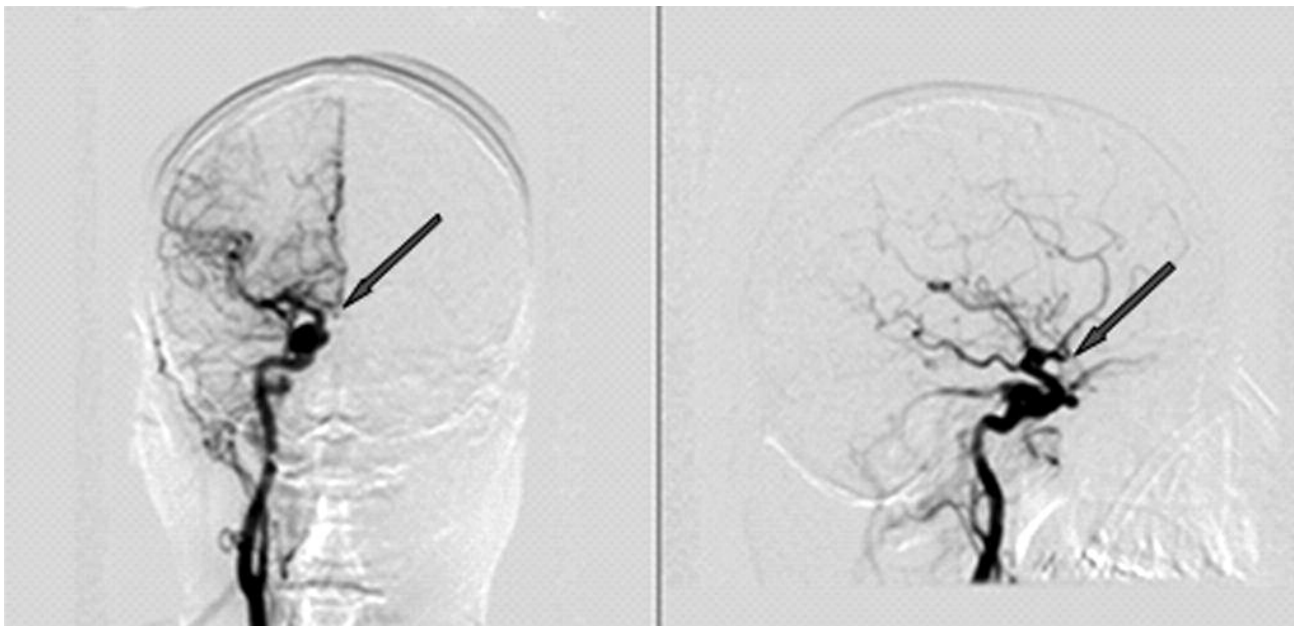


Figure 2. Bilateral carotid-cavernous fistulas (arrow) before treatment (frontal and sagittal plane). Right side—DSA.

Occasionally, the abnormality is preceded by a small aneurysm in the internal carotid artery, which breaks (e.g., from a sneeze), and consequently, the patient develops a fully symptomatic carotid-cavernous fistula. The condition occurs in syndromes related to collagen disorders. The cause is often iatrogenic

(thrombectomy, biopsy of the epipharynx, surgical treatment of the pituitary gland through the sphenoidal sinus). The occurrence of a fistula leads to a rise in pressure in the intraorbital veins and the adjoining vascular sinuses. A consequence of that condition is the development of haemodynamic and functional

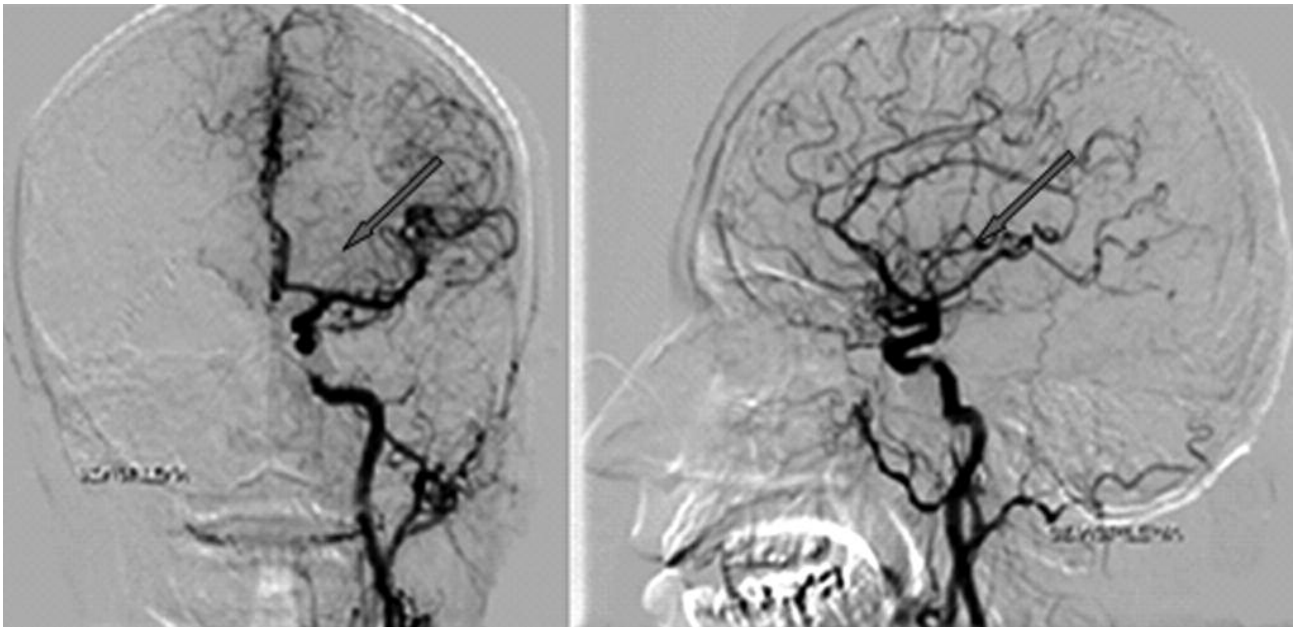


Figure 3. Left side—control angiography performed 6 months after the embolisation (frontal and sagittal plane). DSA (arrow – location of fistula before embolisation).

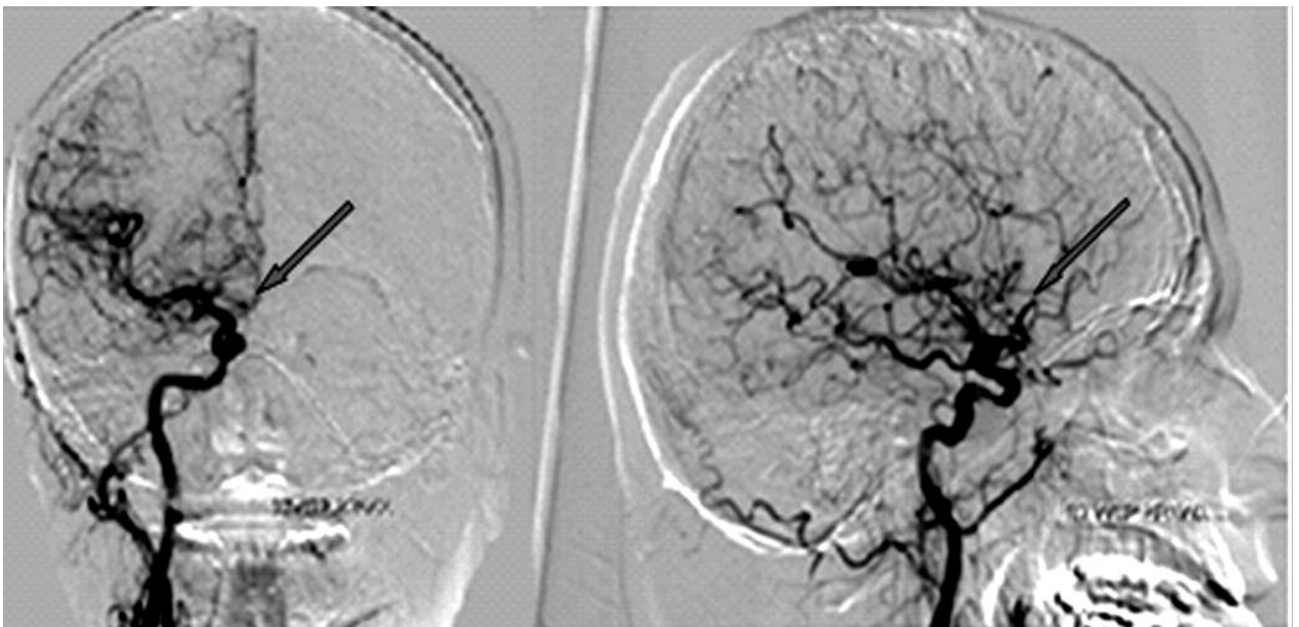


Figure 4. Right side—control angiography performed 6 months after the embolisation (frontal and sagittal plane). DSA (arrow – location of fistula before embolisation).

disorders that build up the specific clinical picture described above.

The natural course of the condition is unfavourable. The symptoms include binocular visual disorder, cerebral stroke and a substantial risk of intracranial bleeding. The indications for urgent treatment include rapid intensification of symptoms, violent outbreak of the condition, visual disorder, symptoms of increased intracranial pressure, and intense retrobulbar pain^[4,5].

The aim of treatment is not only to close the fistula, but also to maintain patency of the internal carotid artery and the ophthalmic artery.

Surgical clipping of the internal carotid artery above or below the break closes the carotid-cavernous fistula, but it also eliminates the flow in the internal carotid artery. In the tests carried out by Goto et al. with regard to ca 150 cases of carotid-cavernous fistulas, occlusion of the internal carotid artery was necessary in approximately 5% of patients^[6].

Intracranial embolisation with use of microembolisation coils is the first-choice treatment in the cases of carotid-cavernous fistulas. According to the available literature on the subject, the closure of extensive fistulas is often hampered; in such cases, the result is considered satisfactory when the clinical symptoms of the vascular abnormality subside. It is crucial to avoid increased vascular flow in the ophthalmic and cortical veins, as this would cause intensified ocular symptoms and greater risk of intracranial bleeding^[7-9].

An alternative embolisation approach is the use of the Onyx Liquid Embolic System. Onyx is a liquid factor applicable in the treatment of large aneurysms and arteriovascular malformations^[10,11]. Onyx has short history as a material used in embolisations, and there are no evident reports in the literature about its effectiveness.

Bilateral carotid-cavernous fistulas evidently occur less frequently. The clinical picture and aetiology do not differ from what is observed in the cases of a unilateral abnormality. The determinant of correct treatment of the bilateral changes is the maintenance of flow in the internal carotid arteries. For that reason, the

procedure is connected with higher perioperative risk, and certain procedures, such as clipping the internal carotid arteries, are not considered^[12-14].

Conclusion

Obliterating the cavernous sinuses with microcoils seems to be the procedure of choice. Its effectiveness is very high, and functions are restored, an example of which is the patient described in our case.

References

1. Barrow DL, Spector RH, Braun IF, et al. Classification and treatment of spontaneous carotid-cavernous sinus fistulas. *J Neurosurg* 1985;62:248–56.
2. Berenstein A, Kricheff II, Ransohoff J. Carotid-cavernous fistulas: intrarterial treatment. *Am J Neuroradiol* 1980;1:449–57.
3. Higashida RT, Halbach VV, Tsai FY, et al. Interventional neurovascular treatment of traumatic carotid and vertebral artery lesions: results in 234 cases. *Am J Roentgenol* 1989;153:577–82.
4. Halbach VV, Higashida RT, Hieshima GB, et al. Transvenous embolization of direct carotid cavernous fistulas. *Am J Neuroradiol* 1988;9:741–7.
5. Halbach VV, Higashida RT, Barnwell SL, et al. Transarterial platinum coil embolization of carotid-cavernous fistulas. *Am J Neuroradiol* 1991;12:429–33.
6. Goto K, Hieshima GB, Higashida RT et al. Treatment of direct carotid cavernous sinus fistulae. Various therapeutic approaches and results in 148 cases. *Acta Radiol Suppl.* 1986;369:576-9.
7. Debrun GM, Ausman JI, Charbel FT, et al. Access to the cavernous sinus through the vertebral artery: technical case report. *Neurosurgery* 1995;37:144–7.
8. Wilms G, Demaerel P, Lagae L, et al. Direct carotidocavernous fistula and traumatic dissection of the ipsilateral internal carotid artery: endovascular treatment. *Neuroradiology* 2000;42:62–5.
9. Coley SC, Pandya H, Hodgson TJ, et al. Endovascular trapping of traumatic carotid-cavernous fistulae. *Am J Neuroradiol* 2003;24:1785–8.
10. Mawad ME, Cekirge S, Ciceri E, et al. Endovascular treatment of giant and large intracranial

aneurysms by using a combination of stent placement and liquid polymer injection. *J Neurosurg* 2002;96:474–82.

11. Kocer N, Kizilkilic O, Albayram S, et al. Treatment of iatrogenic internal carotid artery laceration and carotid cavernous fistula with endovascular stent-graft placement. *Am J Neuroradiol* 2002;23:442–6.

12. Weber W, Henkes H, Berg-Dammer E, et al. Cure of a direct carotid cavernous fistula by endovascular stent deployment. *Cerebrovasc Dis* 2001;12:272–5.

13. Gomez F, Escobar W, Gomez AM, et al. Treatment of carotid cavernous fistulas using covered stents: midterm results in seven patients. *Am J Neuroradiol* 2007;28:1762–8.

14. Uysal E, Kızılkılıç O, Ulusay M, et al. Endovascular trapping of direct carotid-cavernous fistula. *J Clin. Neurosc.* 17 (2010) 392–394.