



Original Article

Radiological Dehiscence of the Mastoid Portion of the Facial Nerve after Posterior Tympanotomy: Does It Lead to Increased Risk of Nerve Injury?

Ambrose Lee, Steve Connor, James R Tysome, Alec Fitzgerald-O'Connor, Dan Jiang

Clinic of Otolaryngology-Head and Neck Surgery, St. Thomas Hearing Implant Centre, Guy's and St. Thomas' NHS Foundation Trust, London, UK (DJ, ALM, JRT, AFO)

Department of Radiology, Guy's and St. Thomas' NHS Foundation Trust, London, UK (SC)

OBJECTIVE: We aimed to establish the frequency of postoperative bony dehiscence overlying the mastoid portion of the facial nerve after round window membranous cochleostomy using high-resolution computer tomography, and to ascertain whether this was associated with a higher incidence of facial nerve injury compared with other studies. We also evaluated the usefulness of the St Thomas' classification in predicting the possibility of performing round window insertions.

Study Design: Retrospective case series.

Setting: Tertiary auditory implant centre.

MATERIALS and METHODS: Twenty-five patients who underwent cochlear implantation at our institution, two of whom were operated on bilaterally, yielding 27 ears for analysis. We conducted submillimetric analysis of postoperative high-resolution computer tomography images to ascertain the prevalence of bony dehiscence overlying the mastoid portion of the facial nerve. The type of round window found during surgery was also determined in medical records.

RESULTS: We found a radiological dehiscence rate of 40%. None of the patients in our series sustained a facial palsy. We propose some possible reasons for differences between our findings and those of others. All 18 patients with a Type Ia round window, two of the three patients with a Type IIa round window, and none of the four patients with a Type III round window had a successful round window insertion. The classification was found to be a useful predictor of performing round window membranous cochleostomy.

CONCLUSION: Thinning of the bony cover of mastoid portion of the facial nerve to the point of radiological dehiscence does not put it at risk. Novice cochlear implant surgeons can therefore be reassured that unroofing the bone overlying the nerve does not pose undue danger.

KEY WORDS: Cochlear implantation, nerve injury, facial, tomography, X-ray computed tomography

INTRODUCTION

Iatrogenic facial nerve (FN) paralysis is one of the most feared complications in otological surgery. During cochlear implantation (CI), the surgeon works very close to the mastoid portion of the facial nerve (MPFN) while creating the posterior tympanotomy (PT). Nevertheless, CI is a safe procedure, with an estimated rate of facial nerve paralysis of 0.3%^[1]. We routinely use the round window membrane (RWM) cochleostomy approach for electrode insertion because it enables the surgeon to see the scala tympani directly and is a well-established method of electrode insertion^[2]. It has also been shown to cause less damage to remaining cochlear neuronal tissue than a bony cochleostomy anterior and superior to the round window (RW)^[3,4].

Round window membrane cochleostomy cannot be performed unless the surgeon is able to see enough of the RWM, which lies more posterior than in a conventional cochleostomy. Achieving this degree of exposure requires a 'perfect' PT with an intact tympanic annulus and posterior canal wall, with maximum thinning of the bone overlying the chorda tympani and the MPFN. This enables optimum surgical access to the RWM. The extent of exposure is graded using a classification system developed at St. Thomas' Hospital, which assists in deciding between conventional electrode insertion and RW cochleostomy (Figure 1 and Table 1)^[5]. To date, our success rate with Type I and Type IIa exposure of the RWM is more than 85% of cases.

The aim of this study was to establish the frequency of postoperative bony dehiscence overlying the MPFN after RWM cochleostomy using high-resolution computed tomography (HRCT), and to ascertain whether this was associated with a higher incidence of facial nerve injury compared with figures from the literature. We also wished to evaluate the St Thomas' Hospital

Corresponding Address:

Dan Jiang, Clinic of Otolaryngology-Head and Neck Surgery, St. Thomas Hearing Implant Centre, Guy's and St. Thomas' NHS Foundation Trust, London, UK
Phone: 44-(0) 207 1880716; Fax: 44-(0) 207 1882192; E-mail: d.jiang.uk@gmail.com

Submitted: 22.10.2013 Revision Received: 07.01.2014 Accepted: 26.01.2014

Copyright 2014 © The Mediterranean Society of Otolaryngology and Audiology

classification to assess its usefulness in predicting the possibility of performing RW insertions.

MATERIALS and METHODS

A practical classification to ascertain the accessibility of the RWM through the PT was developed at St Thomas' Hospital (Table 1), which was used in our study^[4]. We performed a retrospective review of our cochlear implant database from 2004 to 2008. Relevant images were reviewed, and 25 patients had appropriate submillimetric source data for analysis. HRCT examinations were performed using a Philips Brilliance 40 scanner (Philips Healthcare, Surrey, United Kingdom; 100 mA, 120 kV, 768 × 768 matrix, 0.8 mm slice thickness with 0.4 mm z-axis reconstruction). Operated and unoperated ears were analysed to determine the incidence of natural bony dehiscence. Imaging extended from the posterior genu to the stylomastoid foramen. A facial nerve canal defect was defined as the presence of a breach in the bony canal wall in at least one section, with multiplanar reformats used to aid decision-making. This was assessed by two raters (a

consultant neuroradiologist and an otologist) and a consensus was reached in all cases. Figure 2 shows an example of radiological dehiscence of the MPFN.

Informed consent was obtained from all study participants. This study was undertaken with approval from the clinical audit and research department at the Guy's and St. Thomas' Hospitals NHS Foundation Trust.

RESULTS

Twenty-five patients were involved in this study, two of whom were operated on bilaterally. Hence, scans of 27 ears from 25 patients were reviewed (Table 2). The median age at the time of implantation was 34 years (range 2-81 years). Eighteen patients (72%) were classified as having a Type I RW (Table 3). Of the remaining seven cases, three were classified as having a Type IIa RW, four as having a Type III RW. Twenty-one (84%) patients underwent an RW insertion.

Dehiscence of the MPFN in the unoperated ear was present in two patients. The radiological dehiscence of MPFN was identified in 10 implanted ears, resulting in a radiological dehiscence rate of 40% (Table 3). The radiological dehiscence rate was 39% (7 out of 18 patients) for Type I RWs, 33% (1 out of 3) for Type IIa RWs, and 50% for Type III

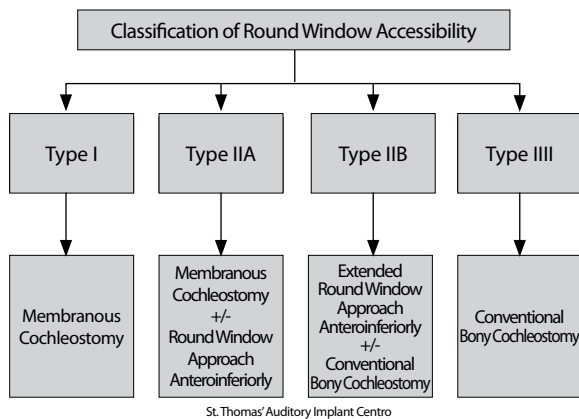


Figure 1. St. Thomas' Classification of round window accessibility with recommended type of surgical approach^[5]

Table 1. St Thomas's classification of round window accessibility with recommended type of surgical approach^[5]

Classification	Description
Type I	The round window area is fully exposed after the bony overhang is removed and the entire round window membrane can be seen.
Type II a	The bony overhang can be partially removed exposing between 50 and 99% of the round window membrane.
Type II b	Between 1 and 49% of the round window is exposed.
Type III	No round window membrane can be seen despite best surgical efforts.

Table 3. Classification of the round window membrane by MPFN status

MPFN status	Patients (%)				Total
	I	IIa	IIb	III	
Dehiscent	7 (28)	1 (4)	0 (-)	2 (8)	10 (40)
Not dehiscent	11 (44)	2 (8)	0 (-)	2 (8)	15 (60)
Total	18 (72)	3 (12)	0 (-)	3 (12)	25 (100)

MPFN: mastoid portion of the facial nerve

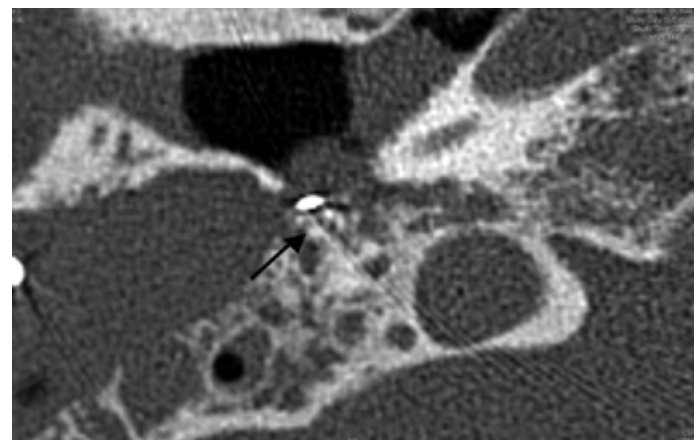


Figure 2. Axial HRCT of a right-sided temporal bone showing an example of a dehiscence of the MPFN (indicated by →)

HRCT: high-resolution computed tomography

Table 2. Demographics

Number of patients	25 (100.0%)
Age at implantation (years)	
Mean±SD	36.4±29.0
Median (range)	33.6 (2-81)
Men	15 (60%)

RWs. There did not appear to be a correlation between the type of RW and the radiological dehiscence rate. All 18 patients classified as having a Type I RW underwent a successful RW insertion, whereas two out of three patients with a Type IIa RW and none out of four patients with a Type III RW had a successful RW insertion.

The surgical notes for the 25 patients were retrieved and analysed. Amongst the cases where the status of the MPFN was mentioned, there were three where the surgeon specifically stated that he had uncovered the bone overlying the MPFN, and they were also captured on HRCT. None of the 25 patients developed any facial nerve palsy.

DISCUSSION

Synopsis of Key/New Findings

We aimed to assess the postoperative radiographic incidence of MPFN dehiscence in RWM cochleostomy and found a postoperative MPFN dehiscence rate of 40% without facial palsy. In contrast, Fayad et al.^[6] reported a rate of facial palsy after CI of 0.71%. De Stefano et al.^[7] provided various pathophysiological mechanisms to explain why delayed palsy occurs. These include ischaemia, vasospasm, neural devascularisation, immune reactions, and viral reactivation, which might lead to neural oedema^[7]. In a retrospective study in 11 patients with iatrogenic facial nerve palsy, Marina et al.^[8] reported that the commonest site of injury was at the second genu. In these cases, the aditus ad antrum had been drilled too inferior and posterior in relation to its actual position. Ten out of 11 cases were classified as HB Class V or lower, and they all improved to HB Class III or better after decompression^[8].

It is currently believed that natural dehiscence of the MPFN is low relative to the tympanic portion^[9]. Using unoperated ears as controls, we found natural dehiscence of the MPFN in two of our 25 patients. This may be an underestimation because defects smaller than 1 mm are not usually visible with HRCT^[10]. Yu et al.^[11] found that the MPFN was pathologically exposed in 3.3% of cases, with a range of between 1.2 and 6.4 mm. The incidence of MPFN dehiscence was 12% in another series^[12]. Both of these studies were in subjects with pre-existing middle ear diseases, which implies that they may not be comparable to our patients.

The St Thomas' Hospital Classification was found to be useful in predicting RW insertions because all Type I RWs underwent successful RW insertions. However, there was no correlation between the Type of RW and the radiological dehiscence rate. This might have been due to an inadequate sample size but it appears that regardless of the classification used, there is a greater than one in three chance of creating a radiological dehiscence over the MPFN.

The best approach to cochleostomy is controversial, and cochleostomies made anteroinferior to the RW are still widely practised. As with RWM cochleostomy, Briggs et al.^[3] have shown that inferior cochleostomy requires increased access to the region of the RW niche, involving complete facial recess dissection, with complete skeletonisation of the nerve and wide dissection of the chorda tympani. The drilling required occurs very close to the chorda tympani-facial nerve angle, thus putting both nerves at risk. Although this should be pos-

sible with a thorough knowledge of anatomy, the same author has stated that many CI surgeons are not confident enough to perform complete facial recess dissection^[13]. On the other hand, there is much evidence that an anterior cochleostomy can result in scala media or vestibuli insertions^[14]. Cochleostomies placed without visualising the RW are likely to be anterior, and hence more likely to enter the scala vestibuli^[3].

Comparisons with Other Studies

The facial nerve dehiscence rate in our study was lower than that in a self-reported survey of surgeons published by Adunka et al.^[15], who reported that 65% of respondents routinely identified the facial nerve in the facial recess during CI. The reason for this difference is that we assessed radiographic dehiscence and not identification of the facial nerve, which can be done either based on anatomical knowledge, actual visual confirmation via uncapping of the bony covering (surgical dehiscence), or facial nerve monitoring. The bony cover overlying the MPFN can be drilled off without formally having identified the facial nerve, which may or may not be recorded in surgical notes.

The importance of skeletonising the FN during CI surgery can also be explained histologically. In Meshik's study, computed tomographic analyses of human temporal bones were studied, with the sole purpose of determining the best CI insertion trajectory. Many different insertion vectors were examined. In cases where the most favourable trajectory was to the scala tympani, the path often touched the lateral surface of the mastoid segment of the facial nerve, or even intersected the nerve. This emphasises that the facial recess must be adequately enlarged, with removal of all but a thin shell of bone anterolateral to the facial nerve to assure an implantation trajectory as close as possible to the centreline of the scala tympani. The facial nerve is therefore a critical landmark and must be well skeletonised within the Fallopian canal to assure the straightest vector of insertion^[16]. In another study using a similar model, it was shown that the posterior border of the RWM was often obscured by the MPFN. Therefore, starting the PT just above the level of the MPFN would provide the best opportunity for RWM accessibility^[17]. Moreover, RWM cochleostomy can be achieved in a vast majority of CI cases. A study by Gudis et al.^[18] with 130 patients demonstrated a RW insertion success rate of 85%. Only 11 patients underwent a bony cochleostomy because the RW was positioned too far posteriorly relative to the MPFN^[18]. We would commence our posterior tympanotomy routinely just above the MPFN, with the aim to thin the bone overlying the MPFN to less than 1 mm. Although we do not uncap it deliberately, we dissect fairly close to it, to a point where it can be seen through the bone. Hence, the likelihood of achieving radiological MPFN dehiscence is higher with our approach. This, however, does not equate to surgical dehiscence and a distinction should be made between the two. Also, it is our practice to remove the bony overhang of the RW niche, because it increases the exposure of the RWM. This facilitates the usage of the St. Thomas' Hospital Classification and electrode insertion along the scala tympani lumen rather than towards the modiolus^[19].

Strengths and Weaknesses of the Study

Our study benefited from the objective use of HRCT. All subjects were scanned using a uniform protocol.

A number of weaknesses need to be addressed. First, only 25 CT images of sufficient resolution were retrieved for analysis. To reproduce the rate of iatrogenic FN paralysis of 0.3% quoted in the introduction, an a-priori sample size of at least 300 scans would have to be reviewed to discover one case. This was not possible as we used HRCT routinely only between 2004 and 2009. HRCT was used to visualise the number of intracochlear electrodes to facilitate mapping by the audiology staff, but was abandoned due to concerns of excessive radiation^[20]. Despite this, we consider the cases retrieved to be representative of the general CI population, with a reasonable case mix of adults and children, so we believe that our study gives a valid snapshot of the surgical anatomy. Second, pre-operative HRCTs were not routinely done to establish the presence of natural MPFN dehiscence. However, it is reasonable to conclude that iatrogenicity was the main contributing factor based on the rate of 8% for MFPN dehiscence calculated on the contralateral ears and our postoperative MPFN radiological dehiscence rate of 40%. Larger studies with pre- and postoperative HRCT scans are required to investigate the relationship between iatrogenic FN dehiscence and palsy. A third limitation is that the MPFN status was often not recorded in the patients' surgical notes. We estimated that between 12% and 40% of bony coverings were unroofed during PT (three cases of clinically recorded dehiscence and nine cases of radiological dehiscence in our sample).

The present HRCT resolution is too low to enable the chorda tympani nerve to be identified. We also did not use the radiological scoring system for scala tympani insertion to investigate the relationship between the St Thomas' Hospital Classification and scala tympani insertion, because it has not been validated and can only be used to compare two Groups. It would be worthwhile to conduct adequately powered prospective studies of patients undergoing RWM cochleostomy to further quantify the risks involved.

In conclusion, The St Thomas' Hospital Classification was found to be a useful predictor in RWM cochleostomy. Our radiological MPFN dehiscence rate was lower than that in the literature. Thinning of the MPFN to the point of radiological dehiscence does not put the facial nerve at risk. The results of the current study suggest that creating the perfect posterior tympanotomy where the bone overlying the MPFN has to be maximally thinned does not pose undue danger to the facial nerve.

Ethics Committee Approval: The study was a part of clinical evaluation project approved by Guy's and St. Thomas Hospitals NHS Foundation Trust Audit Committee. Improved cochlear implant insertion position with a round window centered approach (Project Number: 1228).

Informed Consent: Written informed consent was obtained from patients who participated in this study.

Peer-review: Externally peer-reviewed.

Author Contributions: Concept - D.J., A.L., S.C.; Design A.L., S.C.; Supervision - D.J., S.C., A.F.O.; Materials - D.J., S.C., A.F.O.; Data Collection and/or Processing - A.L., J.T.; Analysis and/or Interpretation S.C., A.L.; Literature Review - A.L., J.T.; Writing - A.L.; Critical Review - D.J., S.C., A.F.O., J.T.

Acknowledgements: Authors thank to Professor Robert Briggs for his contribution to this study.

Conflict of Interest: No conflict of interest was declared by the authors.

Financial Disclosure: The authors declared that this study has received no financial support.

REFERENCES

- Kim C, Oh S, Chang S, Kim H, Hur D. Management of complications in cochlear implantation. *Acta Oto-Laryngologica* 2008; 128: 408-14. [\[CrossRef\]](#)
- Lehnhardt E, Laszig R. Specific surgical aspects of cochlear implant- soft surgery. In: Desoyer I, Hochmair E (ed.). *Advances in Cochlear Implant*. Wien: Manz; 1994.p.228-9.
- Briggs R, Tykocinski M, Stidham K, Roberson J. Cochleostomy site: implications for electrode placement and hearing preservation. *Acta Oto-Laryngologica* 2005; 125: 870-76. [\[CrossRef\]](#)
- Richard C, Fayad JN, Doherty J, Linthicum FH Jr. Round window versus cochleostomy technique in cochlear implantation: histologic findings. *Otology & Neurotology* 2012; 33: 1181-7. [\[CrossRef\]](#)
- Leong A, Jiang D, Agger A, Fitzgerald-O'Connor AF. Evaluation of round window accessibility to cochlear implant insertion. *Eur Arch Otorhinolaryngol* 2013; 270: 1237-42. [\[CrossRef\]](#)
- Fayad J, Wana G, Micheletto J, Parisier S. Facial nerve paralysis following cochlear implant surgery. *Laryngoscope* 2003; 113: 1344-6. [\[CrossRef\]](#)
- De Stefano A, Neri G, Kulamarva G. Delayed facial nerve paralysis post middle ear surgery:herpes simplex virus activation. *B-ENT* 2009; 5: 47-50.
- Asma A,Marina M, Mazita A, Fadzilah I,Mazlina S, Saim L. Iatrogenic Facial Nerve Palsy: Lessons to Learn. *Singapore Med J* 2009; 50: 1154-7.
- Baxter A. Dehiscence of the fallopian canal. *J. Laryngol Rhinol Otol* 1971; 85: 587-94.
- Dimopoulos P, Muren C, Smedly O, Wadin K. Anatomical variations of the tympanic and mastoid portions of the facial nerve canal. *Acta Radiol* 1996; 37: 49-59.
- Yu Z, Han D, Dai H, Zhao S, Zheng Y. Diagnosis of the Pathological Exposure of the Mastoid Portion of the Facial Nerve by CT Scanning. *Acta Oto-Laryngologica* 2007; 127: 323-7. [\[CrossRef\]](#)
- Selesnick S, Lynn-Macrae A. The Incidence of Facial Nerve dehiscence at surgery for cholesteatoma. *Otol Neurotol* 2001; 22: 129-32. [\[CrossRef\]](#)
- Brigg R, Tykocinski M, Xu J, Risi F, Svehla M, Cowan R, et al. Comparison of Round Window and Cochleostomy Approaches with a prototype Hearing Preservation Electrode. *Audio Neurotol* 2006; 11: 42-8. [\[CrossRef\]](#)
- Todt I, Basta D, Ernst A. Does the surgical approach in cochlear implantation influence the occurrence of postoperative vertigo. *Otolaryngol Head Neck Surg* 2008; 138: 8-12. [\[CrossRef\]](#)
- Adunka O, Buchman C. Scala Tympani Cochleostomy I: Results of a Survey. *Laryngoscope* 2007; 117: 2187-94. [\[CrossRef\]](#)
- Meshik X, Holden T, Chole R, Hullar T. Optimal cochlear implant insertion vectors. *Otol Neurotol* 2010; 31: 58. [\[CrossRef\]](#)
- Li P MMC, Wang H, Northrop C, Merchant S, Nadol J, Jr. Anatomy of the Round Window and Hook Region of the Cochlea With Implications for Cochlear Implantation and Other Endocochlear Surgical Procedures *Otol Neurotol* 2007; 28: 641-8.
- Gudis DA, Montes M, Bigelow D, Ruckenstein M. The Round Window: is it the 'cochleostomy' of choice? Experience in 130 consecutive cochlear implants. *Otol Neurotol* 2012; 33: 1497-501. [\[CrossRef\]](#)
- Roland PS, Wright CG, Isaacson B. Cochlear implant electrode insertion: the round window revisited. *Laryngoscope* 2007; 117: 1397-402. [\[CrossRef\]](#)
- Torizuka T, Hayakawa K, Satoh Y, Tanaka F, Saitoh H, Okuno Y. High Resolution CT of the Temporal Bone: A Modified Baseline. *Radiology* 1992; 184: 109-11.