
CASE REPORT

Otologic Features of Apert's Syndrome: A Case Report

Diego Zanetti, MD., Michela Piccioni, MD.,

From the Otolaryngology
Department, University of Brescia,
Brescia, Italy

Correspondence

Dr. Diego Zanetti
Clinica ORL, Università di Brescia
Piazzale Spedali Civili 1 - 25100
Brescia, Italy
Tel: +39(30) 3995320
FAX: +39(30) 2422818
E-mail: diego_zanetti@iol.it

Submitted: 27 December 2005

Revised: 25 January 2006

Accepted: 30 January 2006

Mediterr J Otol 2006; 2: 83-87

Copyright 2005 © The Mediterranean
Society of Otolology and Audiology

Apert's syndrome, or acrocephalosyndactyly, type I, is a rare cranioskeletal disorder, inherited through a dominant trait, with frequent involvement of the middle ear. The most frequent audiologic presentation is a conductive hearing loss, the etiopathogenesis of which is attributable to congenital ossicular malformations, stapes ankylosis, or the common recurrent middle ear effusion.

The authors review the literature and present the case of a 13-year-old girl with Apert's syndrome in whom repeated myringotomies with grommet insertions achieved a significant hearing gain but were unable to close the air-bone gap. A computerized tomography scan of the temporal bones evidenced several malformations of the skull and petrous pyramid. An exploratory tympanotomy was not performed out of concern for the high, dehiscent jugular bulb and dehiscent fallopian canal. No progression of conductive hearing loss was observed during an 8-year follow-up, but complete closure of the conductive gap was never obtained.

Apert's syndrome, or acrocephalosyndactyly, type I, first described in 1906, is one of the most severe craniosynostosis syndromes. It is characterized by symmetrical cutaneous and bony syndactyly of the hands and feet, bilateral coronal synostosis associated with midface hypoplasia, exophthalmia, and hypertelorism.^[1]

It is inherited through an autosomal dominant trait, which involves the fibroblast growth factor receptor 2 (FGFR2)^[1-3]. It occurs in about 1 out of 160,000 live births.^[4] Clinical manifestations include seizures, spina bifida, and ankylosis of major joints. Middle ear malformations are present in two thirds of patients. The most frequent audiologic presentation is a conductive hearing loss, whose etiopathogenesis is otherwise controversial.^[5]

We review the literature and present the case of a 13-year-old girl with Apert's syndrome. The management of her hearing loss is also discussed.

CASE REPORT

TC is a 13-year-old adolescent girl with Apert's syndrome and a clinical history of multiple orthopedic and maxillofacial procedures for cranial, facial, and fingers dysostosis. From age 12, she had seizures that were controlled with barbiturates. At age 12 years, she was diagnosed with bilateral conductive hearing loss. In July 1997, the patient presented with a recent worsening of her hearing loss.

Clinical examination revealed brachicephaly with prominent frontal and malar bones, hypertelorism, asymmetric bilateral ocular proptosis, arcuate hard palate, and dental malocclusion (Figure 1).

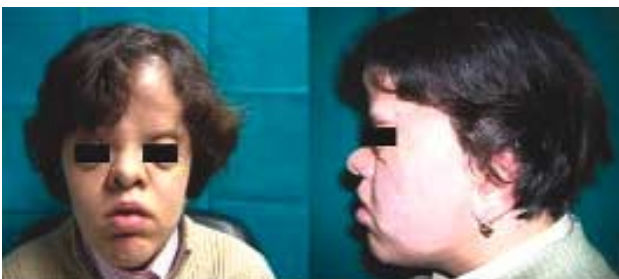

Figure 1: Frontal and lateral view of the 21 year-old patient.

Her fingers were congenitally fused; they regained a cosmetically acceptable look and a satisfactory motile function after repeated surgical interventions (Figure 2).

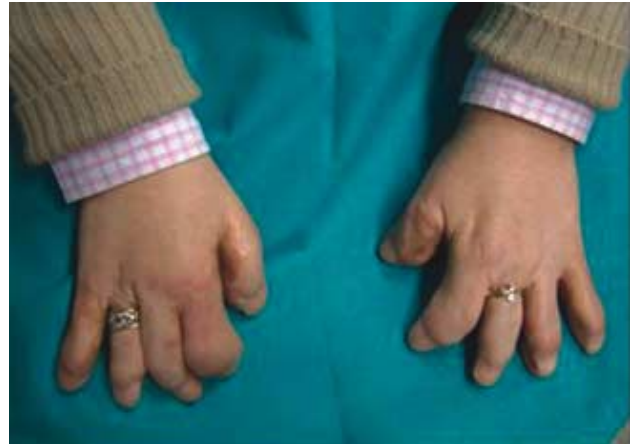

Figure 2: Patient's hands after multiple operations.

The auricle was normal in appearance; the external ear canal was funnel shaped with its medial end consistently narrowed. On micro-otoscopy, a middle ear effusion was evident bilaterally, with a bluish prominence in the hypotympanum.

Pure tone audiometry assessed a conductive loss averaging 37.4 dB HL and 58.3 dB HL at 500-1000-2000-3000 Hz in the right and left ears, respectively. A flat tympanogram was obtained bilaterally with absent acoustic stapedial reflexes.

Bisyllabic word and sentence recognition scores in an open set reached 100% at 80 dB HL. Auditory brainstem responses showed increased latencies of all peaks bilaterally, with preserved, within-normal-limits interpeak intervals, indicating a conductive loss. Transient-evoked otoacoustic emissions were absent bilaterally. Electronistagmographic recordings of rotatory chair testing demonstrated a bilaterally normal symmetric vestibular response.

A computerized tomography (CT) scan of the temporal bones demonstrated a high jugular bulb bilaterally (especially on the left side) and a dilated vestibule with large asymmetric vestibular aqueduct (Figure 3). Although no ossicular malformations were detected, congenital fixation of the stapes could not be ruled out.

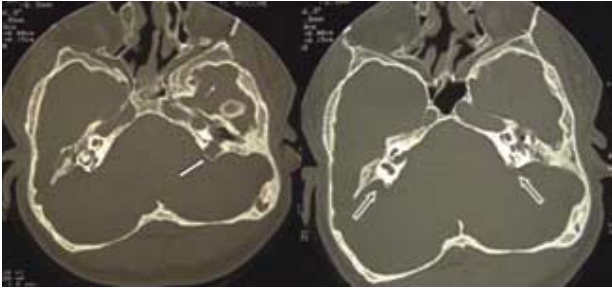


Figure 3: Computerized tomography scan of the temporal bone in the axial projection, showing the left high jugular bulb (white arrow) and the effusion in the tympanic cavity. The vestibule is dilated and the vestibular aqueduct is enlarged, especially on the right (empty arrows). Note also the malformation of the occipital bones and the congenital deviation of the nasal septum.

The patient underwent a myringotomy with insertion of fluoroplastic ventilation tubes (VTs). A significant improvement of air-conducted hearing threshold was achieved (Figure 4), although a mean air-bone gap (ABG) of 16 dB HL and 22 dB HL at 500-1000-2000-3000 Hz still persisted. After extrusion of the grommets 6 months later, and despite a normal tympanogram, an average 25-dB ABG was still observed. The suspicion of a partial stapedial ankylosis was raised. Due to the limited degree of residual hearing loss and the anatomic difficulties, stapes surgery was initially postponed.

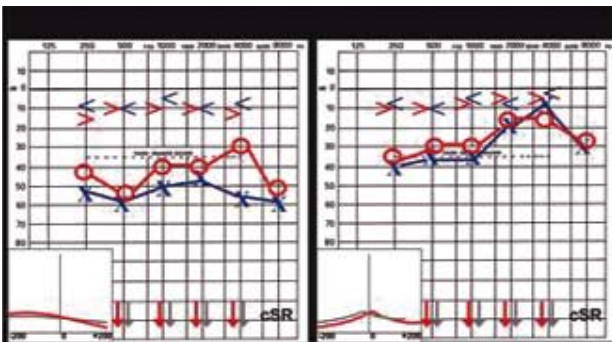


Figure 4: Premyringotomy (left) and postmyringotomy (right) audiograms of the young woman at age 21 years. Note the persisting air-bone gap and the absence of contralateral acoustic stapedial reflexes despite a normalized tympanogram (bottom right).

During the years following, the patient had recurrent episodes of otitis media with effusion and worsening of conductive hearing loss. It was necessary to treat the patient twice with myringotomies and VTs. Currently,

the patient is 22 years old, and she carries VTs with an average 20-dB residual ABG. Atrophic scars and a slight retraction of the pars tensa of the eardrum are visible bilaterally.

DISCUSSION

The eponym of the syndrome comes from the researcher who first described it in 1906. It is the first variant of the 5 craniosynostosis syndromes (Apert's syndrome, Pfeiffer syndrome, Crouzon's disease, Saethre-Chotzen syndrome, and Carpenter's syndrome) and is also referred to as acrocephalosyndactyly, type I. It consists of skull and facial malformation associated with syndactyly of the extremities.

Bilateral symmetric fusion of the fingers is associated with ankylosis of major joints. The skull malformation is often related with seizures and spina bifida.^[6] Other inconstant anomalies include neurologic disturbances such as expressive language difficulties^[7]; mental retardation of variable degree^[8]; autism^[9]; and cardiovascular, respiratory, ophthalmic, gastrointestinal, and tegumentary malformations.

Great advances in clinical genetic, biochemical and structural approaches have highlighted the molecular basis for Apert's syndrome. It is caused by allelic mutations of the gene for FGFR2, mainly through autosomal dominant transmission.^[1-3] Although Apert's syndrome shows the least genetic heterogeneity among craniosynostoses, it manifests with a high variability of clinical pictures.^[1,6] Its incidence is estimated between 9.9 and 15.5 per million live births, accounting for 4.5% of all craniosynostoses.^[4]

External, middle, and inner ear malformations are present in three quarters of patients.^[5] External ear deformities include macrotia, microtia, posterior rotation, and outer surface morphologic abnormalities. Almost all of these patients have low-set ears, such as those seen in our patient (Figure 1).

Conductive or mixed hearing loss is the most frequent audiologic manifestation of Apert's syndrome.^[5] The conductive component can derive either from middle ear effusion, congenital

malformation of the ossicular chain, otosclerotic fixation of the stapes, or their combination.^[5,10] Phillips and Miyamoto found 1 patient with Apert's syndrome out of 3 to have bilateral stapes fixation, and another one with a fixed incus.^[11]

In a relevant series of 70 Apert's syndrome patients seen during 30 years, the incidence of congenital hearing impairment was 3% to 6%.^[5] Almost all had recurrent otitis media with effusion up to adulthood, and half of them developed permanent low-frequency conductive hearing loss by their teens.

The frequent middle ear effusion is related to eustachian tube dysfunction secondary to the malformations in nasopharyngeal region and palatopharyngeal incompetence, or to the less frequent cleft palate.^[5]

Another possible explanation of the conductive loss could be the presence of a large vestibular aqueduct (LVA). In the series of 10 patients followed by Govaerts and colleagues, the hearing loss had a conductive component of pure cochlear type, steadily decreasing at an average rate of 4 dB/year.^[12] In our patient, we were unable to determine the nature of the persisting ABG after myringotomy, because she refused to undergo an exploratory tympanotomy. According to the degree of residual conductive loss (ABG <25 dB), stapes fixation would be unlikely. On the other hand, the absence of progression over a decade does not exclude, per se, the hypothesis of a causative role of the LVA.

An isolated sensorineural hearing loss is seldom encountered; its etiology had been related in the past with a compression of the acoustic nerve from the frequent deformation of the skull base anomaly or a narrow internal auditory canal.^[13] Patients do not usually complain of vestibular symptoms, such as the teenager presented here.

The standard evaluation of patients with Apert's syndrome should include pure tone audiometry, middle ear impedance testing, and auditory brainstem responses. CT of the temporal bones is essential to assess the middle and inner ear status. Associated abnormalities have been described, such as a dehiscent jugular bulb,^[14] upward tilting of the petrous pyramid,

abnormally large horizontal semicircular canal, or subarcuate fossa.^[15]

The management of middle ear effusion in patients with Apert's syndrome with myringotomy and VTs is advisable. Caution must be exerted because of the possible high or dehiscent jugular bulb in the hypotympanum. The surgeon should also beware a dehiscent facial canal, such as in the patient reported by Huang and colleagues.^[10]

The need for repeated grommet insertion is a common event; 1 of 3 patients have postoperative purulent otorrhea. As already mentioned, the persistence of conductive hearing loss through adulthood is common, and the VTs do not statistically affect the risk of developing it.^[16] An exploratory tympanotomy to examine the ossicular chain could otherwise prove dangerous in the presence of the aforementioned middle ear malformations.^[14] It could be indicated when poor conductive hearing gain is achieved by VTs or the persistence of a wide ABG raises the suspicion of a congenital ossicular malformation. Ankylosis of the stapes is the most likely finding in such instances^[16]; it is difficult to assess by CT scan, as in our young patient, in whom the ossicular chain appeared normal in coronal and axial planes.

Initial histopathologic studies of the temporal bone detecting undifferentiated cartilage surrounding the stapedia annular ligament and postulating a disorder of maturation of embryonic cartilage of the first branchial arch have not been replicated.^[17]

More than 20 years ago, Gould discouraged the surgical treatment of stapedia fixation for the possible complications, namely the risk of unexpected gusher when drilling the footplate,^[15] although there are only scanty reports in this respect. Phillips and Miyamoto achieved a significant hearing improvement, without evidence of labyrinthitis, following a simple stapes mobilization technique.^[11] Huang and colleagues reported on an adult with progressive conductive loss in one ear, in whom surgical exploration failed to reveal an ossicular malformation or fixation.^[10]

Despite the possibility of improvement in hearing and in light of the potential complications during

stapedotomy, it is inappropriate, in our opinion, to offer this surgical option immediately to patients with Apert's syndrome, unless the hearing loss is progressive and a wide ABG is present, with no middle and inner ear anomalies on CT scans. General anesthesia should be avoided when possible, because respiratory complications have been reported.^[17,18]

Early optimization of hearing with hearing aids should be considered.

CONCLUSIONS

Apert's syndrome is a rare cranioskeletal disorders with frequent involvement of the middle ear. Life-long micro-otoscopic follow-up is advisable to monitor the frequent exacerbations of middle ear effusion. Repeated myringotomies with grommet insertions are commonly required. If an exploratory tympanotomy is planned for a wide ABG, it must be performed cautiously, due to the possible high, dehiscent jugular bulb and/or aberrant, dehiscent fallopian canal. The occurrence of gusher has been reported in the literature when drilling the footplate. In our young patient, no progression of the conductive hearing loss was observed over an 8-year follow-up, but complete closure of the ABG was never achieved despite multiple myringotomies.

REFERENCES

1. Carinci F, Pezzetti F, Locci P, Becchetti E, Carls F, Avantaggiato A, et al. Apert and Crouzon syndromes: clinical findings, genes and extracellular matrix. *J Craniofac Surg* 2005;16:361-8.
2. Wilkie AO. Fibroblast growth factor receptor mutations and craniosynostosis: three receptors, five syndromes. *Ind J Ped* 1996;63:351-6.
3. Ibrahimi OA, Chiu ES, McCarthy JG, Mohammadi M. Understanding the molecular basis of Apert syndrome. *Plast Reconstr Surg* 2005;115:264-70.
4. Cohen MM Jr, Kreiborg S, Lammer EJ, Cordero JF, Mastroiacovo P, Erickson JD, et al. Birth prevalence study of the Apert syndrome. *Am J Med Genet* 1992;42:655-9.
5. Rajenderkumar D, Bamiou DE, Sirimanna T. Audiological profile in Apert syndrome. *Arch Dis Child* 2005;90:592-3.
6. Lajeunie E, Cameron R, El Ghouzzi V, de Parseval N, Journeau P, Gonzales M, et al. Clinical variability in patients with Apert syndrome. *J Neurosurg* 1999;90:443-7.
7. Shipster C, Hearst D, Dockrell JE, Kilby E, Hayward R. Speech and language skills and cognitive functioning in children with Apert syndrome: a pilot study. *Int J Lang Commun Disord* 2002;37:325-43.
8. Da Costa AC, Savarirayan R, Wrennall JA, Walters I, Gardiner N, Tucker A, et al. Neuropsychological diversity in Apert syndrome: a comparison of cognitive profiles. *Ann Plast Surg* 2005;54:450-5.
9. Artigas-Pallares J, Gabau-Vila E, Guitart-Feliubadalo M. Syndromic autism: II. Genetic syndromes associated with autism [in Spanish]. *Rev Neurol* 2005;40(suppl 1):S151-62.
10. Huang F, Sweet R, Tewfik TL. Apert syndrome and hearing loss with ear anomalies: a case report and literature review. *Int J Pediatr Otorhinolaryngol* 2004;68:495-501.
11. Phillips SG, Miyamoto RT. Congenital conductive hearing loss in Apert syndrome. *Otolaryngol Head Neck Surg* 1986;95:429-33.
12. Govaerts PJ, Casselman J, Daemers K, De Ceulaer G, Somers T, Offeciers FE. Audiological findings in large vestibular aqueduct syndrome. *Int J Pediatr Otorhinolaryngol* 1999;51:157-64.
13. Bergstrom L, Neblett LM, Hemenway WG. Otologic manifestations of acrocephalosyndactyly. *Arch Otolaryngol* 1972; 96: 117-23.
14. Gartenschlager S, Olze H, Stroszczynski C. Notable bulb of jugular vein in Apert syndrome [in German] *Rofo*. 2005;177:903-4.
15. Gould HJ, Caldarelli DD. Hearing and otopathology in Apert syndrome. *Arch Otolaryngol*. 1982;108:347-9.
16. Rajenderkumar D, Bamiou D, Sirimanna T. Management of hearing loss in Apert syndrome. *J Laryngol Otol* 2005;119:385-90.
17. Lindsay JR, Black FO, Donnelly WH Jr. Acrocephalosyndactyly (Apert's syndrome): Temporal bone findings. *Ann Otol Rhinol Laryngol* 1975;84(part 1):174-8.
18. Elwood T, Sarathy PV, Geiduschek JM, Ulma GA, Karl HW. Respiratory complications during anaesthesia in Apert syndrome. *Paediatr Anaesth* 2001; 11:701-3.
19. Isada T, Miwa T, Hiroki K, Fukuda S. The management of the difficult pediatric airway [in Japanese]. *Masui* 2005; 54:490-5.