



Case Report

A Composite Foley Catheter Stent Used to Successfully Manage Recurrent Canal Stenosis Caused by Fibrous Dysplasia of the Temporal Bone

Chao-Yin Kuo, Hsin-Chien Chen, Cheng-Ping Shih, Chih-Hung Wang

Department of Otolaryngology-Head and Neck Surgery, Tri-Service General Hospital, National Defense Medical Center, Taiwan, Republic of China (CYK, HCC, CPS)
Graduate Institute of Medical Sciences, National Defense Medical Center, Taiwan, Republic of China (CHW)

External auditory canal (EAC) stenosis is commonly seen in patients with fibrous dysplasia of the temporal bone. Postoperative canal restenosis is more likely to be encountered after initial surgical management. We present a case of monostotic fibrous dysplasia of the temporal bone with EAC invasion in a 37-year-old man who presented with recurrent canal stenosis and resultant conductive hearing loss after several rounds of revision surgery. The technique of using a composite Foley catheter as a stent gave promising results in terms of improving the canal's patency and closing the preoperative air-bone gap in the hearing threshold after 18 months of follow-up. This suggests that long-term stent use with a Foley catheter offers a treatment of choice to prevent such troublesome canal restenosis.

KEY WORDS: External auditory canal, stenosis, fibrous dysplasia, temporal bone, Foley catheter, stent, conductive hearing loss

INTRODUCTION

Fibrous dysplasia affecting the temporal bone is unusual, measuring less than 10% of all patients^[1]. Stenosis of the external auditory canal (EAC) is the most common finding, complicating at least 80% of all cases^[2]. Patients with fibrous dysplasia-related EAC stenosis often require repeated revision surgeries after initial surgical management because of a high rate of recurrent postoperative EAC stenosis. Therefore, postoperative stent placement has been identified as a treatment of choice to prevent such possible canal restenosis. Although numerous stenting materials have been applied^[3-5], these applications usually demand intensive postoperative management by a surgeon and require multiple clinic visits to ensure sustained support of the applied materials. In addition, some kinds of applications may totally obstruct the ear canal and result in exacerbated hearing impairment, tinnitus, or aural fullness during the stenting period, which may compromise patients' compliance in long-term use. Using a composite Foley catheter as a stent and applying it in the most recent revision surgery, a successful outcome was demonstrated in a case of monostotic fibrous dysplasia of the temporal bone with recurrent EAC stenosis, showing a patent ear canal and significant closure of the preoperative air-bone gap in the pure-tone average.

CASE PRESENTATION

A 37-year-old male presented at our institution with complaints of hearing impairment and canal stenosis in the left ear for about 10 years. He noted a progressive asymmetrical facial bony contour in his early 20s. Unilateral monostotic fibrous dysplasia of the temporal bone was diagnosed, and he underwent surgery to correct his asymmetrical facial contour. Thereafter, he had received otological surgical treatments three times over the past 2 years to correct the fibrous dysplasia-resultant EAC stenosis and conductive hearing loss; however, the surgical outcomes were not satisfactory. Recent clinical and radiological follow-up evaluation showed that the EAC had completely restenosed (Figure 1) and could complicate with cholesteatoma in the ear canal. As the associated hearing deficit was exacerbated, the patient decided to undergo another revision surgery at our hospital.

In this revision, we performed a more adequate canaloplasty by widening the ear canal with drilling. The conchal cartilage was partially resected through the transcanal incision, leaving the overlying skin intact to enlarge the meatal opening. A full-thickness skin graft (FTSG) harvested from the inner thigh was cut into three strips to completely cover the bony raw surface with the lateral edges of the strips sutured to the meatal skin. The EAC was then packed with Gelfoam and petroleum-tetracycline ointment-impregnated gauze strips. At 5 weeks after surgery, a specifically designed Foley catheter stent made by connecting the distal and the proximal ends of a 16-French Foley catheter was inserted into the EAC (Figure 2a). The size of the Foley catheter was determined according to the diameter of the patient's ear canal. The distal end of the catheter was designed to fit into the bony EAC, and the proximal

Corresponding Address:

Chih-Hung Wang, Graduate Institute of Medical Sciences, National Defense Medical Center, Taiwan, Republic of China.
Phone: +886 2 87927192; E-mail: chw@ms3.hinet.net

Submitted: 23.02.2014 Accepted: 04.06.2014 Available Online Date: 11.07.2014

Copyright 2014 © The Mediterranean Society of Otology and Audiology

end-the cartilaginous EAC. The exact length of each portion could be measured and adjusted under microscopic observation to ensure that it was properly assembled and plugging the ear canal.

The patient was instructed to remove and reinsert the stent by himself for cleaning at home 1 month following stent placement. Pure-tone audiometry performed at 18 months postoperatively revealed significant improvement with an average hearing gain (500 to 4000 Hz) of 40 dB. A gross view of the auricle showed satisfactory aesthetic results (Figure 2b) with excellent canal patency, as shown in a follow-up temporal bone computed tomography scan (Figure 3).

DISCUSSION

Unlike most surgical wounds in the body, which heal by primary intention, surgical wounds in the EAC following canaloplasty often heal by secondary intention and seldom benefit by means of primary closure because of their structural limitations. Similar to the use of ear packing at the end of surgery, which creates a pressure effect to minimize the swelling and inflammation, the application of a stent in a newly made EAC is believed to modulate the remodeling process of both the extracellular matrix and bone through the pressure effect. Thus, stent placements have benefits in terms of preventing excessive granulation tissue formation, in addition to maintaining the width of the meatus until adequate epithelialization has been achieved.

Soliman et al.^[4] used a rubber tube as a stent within the EAC to treat patients with acquired aural atresia. Recently, Moon et al.^[3] used an acrylic-made ear mold and hearing aid as a stent to prevent postoperative EAC stenosis in patients with congenital aural atresia. Both studies reported favorable results with stent placements. Although traditional sponges or gauze can also provide some supportive strength to prevent stenosis of the EAC, those stenting materials must be firmly packed for adequate maintenance of the canal patency, thus resulting in an occlusion effect and poor drainage and ventilation. We found that ear occlusion-related aural fullness is the most common complaint for patients using traditional sponges and gauze. The technique we used in this case was to design a composite Foley catheter as a stent. As a result, several advantages by using a Foley catheter stent can be demonstrated: (1) it causes minimal tissue reaction due to its flexibility but is more resistant when it comes to exerting a pressure effect; (2) Foley catheters are inexpensive and easily accessible; (3) there is a wide selection available, as different French units can be used for different widths of the EAC; (4) such a hollow tube not only provides a channel for ventilation and drainage but also attenuates the occlusion effect when employed in the EAC; and (5) this approach elicits good patient compliance. More importantly, the cone shape of the proximal end of the Foley catheter acts just like a stopper on a bottle, such that it can be plugged into the cartilaginous EAC. Thus, the composite Foley catheter not only supports the cartilage portion of the EAC but also stabilizes stent placing in the EAC as a whole to diminish friction, trauma, and subsequent tissue reaction and inflammation.

Additional inflammation may be further triggered or exacerbated by the stent procedure if epithelialization is inadequate. Therefore, resurfacing of the newly made EAC should be carried out before stent placement is conducted. There are many ways to resurface the EAC. Local flaps may have some disadvantages, including inadequate length for

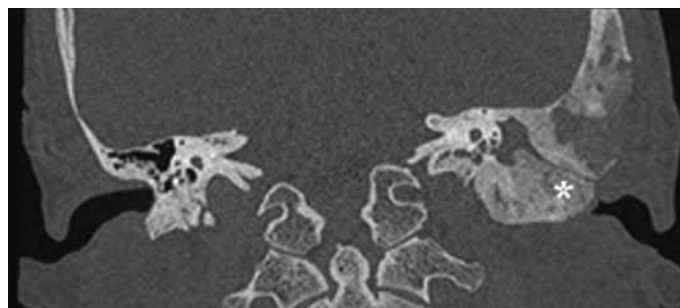


Figure 1. A high-resolution coronal computed tomography scan shows sclerotic and expansile fibrous dysplasia lesions invading the external auditory canal (asterisk). Complete stenosis of the ear canal is noted

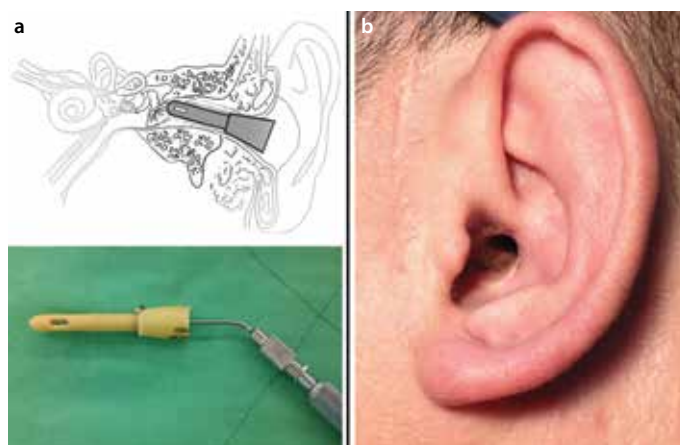


Figure 2. a, b. Schematic illustration of a composite Foley catheter stent plugging the external auditory canal (upper). Such a hollow tube, made by assembling the proximal end and the distal end of the Foley catheter to allow ventilation and suction, was meticulously designed according to the width and length of the patient's canal (lower) (a). Excellent postoperative canal patency and aesthetic results were achieved (b)

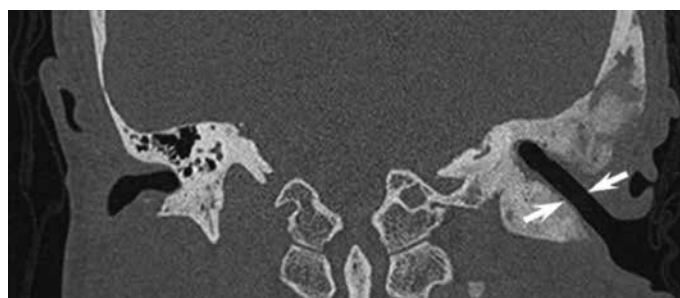


Figure 3. Computed tomography scan obtained after surgery with composite Foley catheter stenting shows a patent ear canal (arrows)

the medial part of the EAC, bulkiness, and prolonged operating time. Split-thickness skin grafts remain the most commonly used technique for resurfacing the EAC in canaloplasty^[6]. However, due to potential problems related to this approach, such as postoperative contracture and less resistance to trauma caused by the later stent placement to expose epithelialized bone, we chose an FTSG to line the external auditory canal during canaloplasty. As a result, the integrated skin layer of the FTSG following long-term Foley catheter placement exhibited a successful survival outcome and great durability.

Since the duration of epithelialization for surgical wound healing may vary and depends on the size of the wound, the timing of stent

placement also varies. It has been suggested that the stent placement should be started 4 to 8 weeks after re-epithelialization, as this period is also important for controlling granulation tissue in the immature stage, and it is expected that the overlying epithelium will be just intact ^[3, 7, 8]. Given that healing by secondary intention is a protracted course, the maintenance of the stent placement for 6 months or more has been recommended in previous reports ^[3], which is consistent with our case.

In conclusion, this is the first case report demonstrating the use of a composite Foley catheter as a stent following canaloplasty as a useful method of preventing canal restenosis. Besides its easy access, a ready-made Foley catheter with a broad size range would be a great benefit for custom design and application in auditory canal stenting.

Informed Consent: Written informed consent was obtained from patient who participated in this case.

Peer-review: Externally peer-reviewed.

Author Contributions: Concept - C.H.W.; Design - C.Y.K., C.H.W.; Supervision - C.H.W.; Data Collection and/or Processing - C.Y.K.; Analysis and/or Interpretation - H.C.C.; Literature Review - C.P.S.; Writing - C.Y.K.; Critical Review - C.H.W.

Conflict of Interest: No conflict of interest was declared by the authors.

Financial Disclosure: This case was supported in part by grants from Tri-Service General Hospital (TSGH-C103-044) and the Teh-Tzer Study Group for Human Medical Research Foundation.

REFERENCES

1. Zanetti D, Gamba P. Cholesteatoma and fibrous dysplasia of the temporal bone: case report and review of the literature. *J Otolaryngol* 2007; 36: 59-63. [\[CrossRef\]](#)
2. Megerian CA, Sofferman RA, McKenna MJ, Eavey RD, Nadol JB Jr. Fibrous dysplasia of the temporal bone: ten new cases demonstrating the spectrum of otologic sequelae. *Am J Otol* 1995; 16: 408-19.
3. Moon IJ, Cho YS, Park J, Chung WH, Hong SH, Chang SO. Long-term stent use can prevent postoperative canal stenosis in patients with congenital aural atresia. *Otolaryngol Head Neck Surg* 2012; 146: 614-20. [\[CrossRef\]](#)
4. Soliman T, Fatt-Hi A, Abdel Kadir M. A simplified technique for the management of acquired stenosis of the external auditory canal. *J Laryngol Otol* 1980; 94: 549-52. [\[CrossRef\]](#)
5. Teufert KB, De la Cruz A. Advances in congenital aural atresia surgery: effects on outcome. *Otolaryngol Head Neck Surg* 2004; 131: 263-70. [\[CrossRef\]](#)
6. McCary WS, Kryzer TC, Lambert PR. Application of split-thickness skin grafts for acquired diseases of the external auditory canal. *Am J Otol* 1995; 16: 801-5.
7. Atiyeh BS. Nonsurgical management of hypertrophic scars: evidence-based therapies, standard practices, and emerging methods. *Aesthetic Plast Surg* 2007; 31: 468-92. [\[CrossRef\]](#)
8. Mustoe TA, Cooter RD, Gold MH, Hobbs FD, Ramelet AA, Shakespeare PG, et al. International clinical recommendations on scar management. *Plast Reconstr Surg* 2002; 110: 560-71. [\[CrossRef\]](#)