



Clinical Report

Alternative Techniques in Cochlear Implantation

Özgür Sürmelioglu, Süleyman Özdemir, Özgür Tarkan, Ülkü Tuncer, Fikret Çetik, Karahan Kara, Mete Kiroğlu

Department of Otorhinolaryngology, Çukurova University School of Medicine, Adana, Turkey

OBJECTIVE: To review the alternative techniques in cochlear implantation and to compare the complications with different techniques.

MATERIALS and METHODS: Patients who had undergone cochlear implantation were reviewed. Those patients who were operated using alternative techniques were selected and evaluated for the cause of their hearing loss and for the type of alternative technique that was utilized. Complication types and rates in these patients were evaluated.

RESULTS: In total, 38 patients were operated using alternative techniques following preoperative or intraoperative findings. The mean age of the patients was 8.3 (1-51) years. There were 20 male and 18 female patients. Thirteen patients were operated with a suprameatal approach and 18 with a transcanal approach. Resection of the bony part of the external ear canal and reconstruction (canal wall down technique) was performed in seven patients. Postoperative complications included wound infection, hematoma, chorda tympani injury, and tympanic membrane perforation.

CONCLUSION: Cochlear implantation is an effective method in the rehabilitation of sensorineural hearing loss. Complications are rare but can sometimes cause hematoma, taste impairment, tympanic membrane perforation, or wound infections. The standard procedure is not always suitable for patients with temporal bone abnormalities. Surgeons performing cochlear implantation should be aware of these variations and should be able to perform alternative implant techniques in these cases.

KEYWORDS: Alternative technique, cochlear implantation, hearing loss

INTRODUCTION

Cochlear implantation is an effective method for the rehabilitation of bilateral total hearing loss. The standard technique was first described by House in 1976^[1]. This remains to be one of the most commonly used technique. Mastoidectomy followed by posterior tympanotomy makes the promontorium or round window visible and allows cochleostomy to be performed for placing the electrode. This procedure can be easily and safely performed by experienced surgeons; however, the external auditory canal, chorda tympani, and facial nerve are all at a risk of injury^[2]. An unusual anterior course of the sigmoid sinus, high-riding jugular bulb, or dura mater placed at a lower position can also be some challenges faced during the operation. In such cases, the classic cochlear implantation procedure may not be suitable: thus, the Veria operation technique for these type of cases has been described by Kiratzidis et al^[3], Hehar et al.^[4] and Kronenberg et al.^[5] described a technique in which the electrode is placed in the cochlea using a suprameatal approach. The transcanal approach is another option for difficult cases. This method is reported by some authors to be an easier way to identify the landmarks in the middle ear^[6-8]. Resection of the bony part of the external ear canal can also be performed when visualization of the round window is difficult. The aim of this study is to discuss the advantages of the alternative techniques used in cochlear implantation in unusual cases when the standard procedure is not suitable. Patients who underwent the cochlear implant procedure in our clinic between 2000 and 2013 were reviewed, and those operated with alternative techniques were included in this study.

MATERIALS and METHODS

In this study, the charts of patients who underwent the cochlear implantation procedure for bilateral total sensorineural hearing loss in the Department of Otorhinolaryngology, School of Medicine, Çukurova University, Turkey, between 2000 and 2013 were reviewed. This study was approved by the local ethics committee. Before surgery, audiologic, psychiatric, neurologic, and radiologic evaluations were performed on all patients. Three different cochlear implant models were used in the operations. Patients operated with alternative implant techniques (such as the suprameatal approach, transcanal approach, or canal wall down approach) were included in the study. Written informed consents from the patients or their parents were obtained for the audiologic, radiologic, and clinical evaluations as well as for operations. The patients' age, gender, hearing loss etiology, radiological findings, intraoperative findings, and implant techniques were noted. Complications because of surgical procedure in the postoperative period were also evaluated. SPSS, version 15.0, was used for the evaluation of demographic features (SPSS Inc.; Chicago, IL, USA).

Presented in: This study was presented as a poster at the 7th Cochlear Implantation and Otology/Neurotology Congress, 5-8 September 2013, Gaziantep, Turkey.

Corresponding Address: Özgür Sürmelioglu, E-mail: surmeli2004@yahoo.com

Submitted: 17.03.2015

Revision received: 20.10.2015

Accepted: 22.10.2015

©Copyright 2016 by The European Academy of Otology and Neurotology and The Politzer Society - Available online at www.advancedotology.org

RESULTS

The charts of 675 patients who had cochlear implants fitted for bilateral total sensorineural hearing loss in the Department of Otorhinolaryngology, School of Medicine, Çukurova University, Turkey, between 2000 and 2013 were reviewed. Of these, 38 patients were operated using alternative implant techniques following preoperative or intraoperative findings. The mean age of the patients was 8.3 (1–51) years. There were 20 male and 18 female patients. The cochlear implant was fitted on the right side in 24 patients and on the left side in 14 patients. In the evaluation of hearing loss, progressive hearing loss was noted in eight patients, ototoxic drug use was reported in one patient, traumatic hearing loss was seen in one patient, and congenital hearing loss was reported in 28 patients (Figure 1). Thirteen patients were operated using the suprameatal approach and 18 patients with the transcanal approach. Resection of the bony part of the external ear canal and reconstruction (canal wall down technique) was performed in seven patients.

The suprameatal approach was used in patients with an unusual anterior course of the sigmoid sinus, narrow facial recess, or narrow antrum, or patients whose round window was hidden. The transcanal approach was used in patients with a narrow facial recess, narrow antrum, high jugular bulb, or hidden round window. Resection of the bony part of the external ear canal was performed when round window visualization was not possible with the standard procedure, and in patients with a narrow facial recess or narrow antrum. Twenty

patients had a high jugular bulb or sclerotic mastoid bone. Eight patients had an abnormal course of the facial nerve or a narrow facial recess. In 10 patients, the round window was not seen with classic posterior tympanotomy (Table 1).

Complications in the 38 patients who underwent alternative techniques involved four cases of tympanic membrane perforation (10.5%), three of chorda tympani injury (7.9%), two of electrode extrusion (5.3%), three of hematoma (7.9%), and one of wound infection (2.6%).

In the suprameatal approach group, the postoperative complications were wound infection in one patient, hematoma in one patient, and tympanic membrane perforation in one patient. In two patients, electrode extrusion was seen after the 3rd and 5th years. Wound infection was cured with parenteral antibiotics. Hematoma was resolved in 1 week by using a tight bandage. The patient with tympanic membrane perforation underwent transcanal tympanoplasty in the postoperative first month. Patients who had electrode extrusion were re-implanted.

In the transcanal approach group, the postoperative complications were hematoma in one patient, chorda tympani injury in one patient, and tympanic membrane perforation in three patients. Hematoma was resolved with a bandage in 4 days. A tympanoplasty operation was performed on three patients.

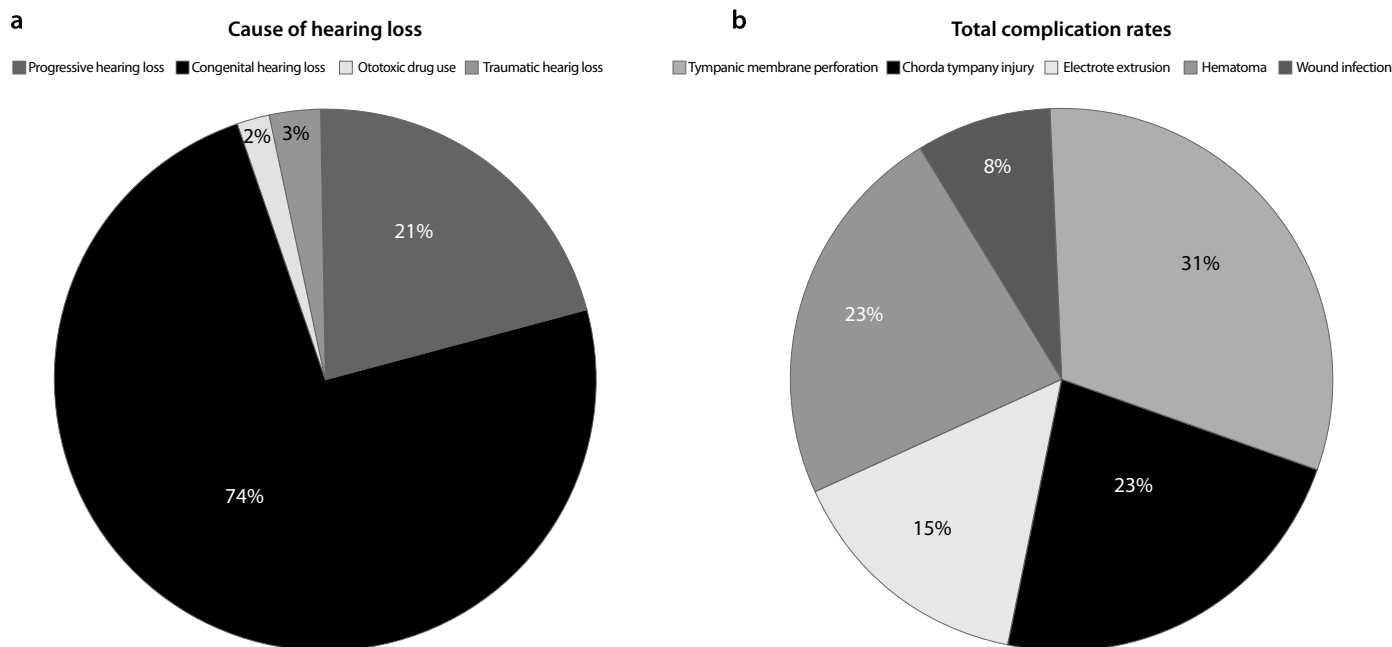


Figure 1. a, b. Causes of hearing loss in patients treated with alternative cochlear implantation techniques

Table 1. Reasons for choosing different cochlear implantation techniques

	Hidden round window	Narrow and sclerotic mastoid antrum	Narrow facial recess	Anterior course of sigmoid sinus
Transcanal approach	7	4	6	1
Suprameatal approach	0	10	1	2
Canal wall down technique	3	3	1	0

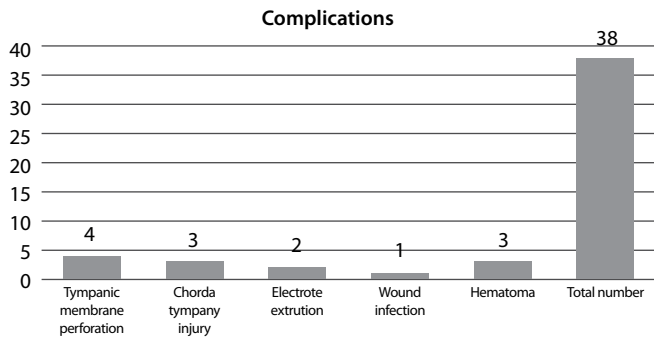


Figure 2. Total complication rates after alternative cochlear implantation techniques

Table 2. Complication rates for different cochlear implantation techniques

	Transcanal approach	Suprameatal approach	Canal wall down technique
Tympanic membrane perforation	3	1	0
Chorda tympani injury	1	0	2
Extrusion of electrode	0	2	0
Hematoma	1	1	1
Wound infection	0	1	0

In patients operated with the canal wall down approach, the post-operative complications were chorda tympani injury in two patients and hematoma in one patient. The hematoma was resolved spontaneously (Table 2).

Overall, complications involved four cases of tympanic membrane perforation (10.5%), three of chorda tympani injury (7.9%), two of electrode extrusion (5.2%), three of hematoma (7.9%), and one of wound infection (2.6%) (Figure 2, Table 2).

DISCUSSION

Cochlear implantation with mastoidectomy followed by posterior tympanotomy and cochleostomy is a safe surgical procedure with low complication rates when performed by experienced surgeons. Although this technique has been widely used, it has several disadvantages and may cause several complications, such as limited accessibility to the cochlea, facial nerve paralysis or paresis, injury to the chorda tympani, or cholesteatoma [3]. Nevertheless, alternative approaches may be required in cases with temporal bone abnormalities or with difficulties with visualization of the round window.

Using the transcanal approach, the middle ear cavity can be seen clearly; this allows the surgeon to place the electrode without difficulty through cochleostomy. A smaller mastoidectomy cavity, posterior tympanotomy, and lower risk of facial nerve injury are the advantages of this technique [9,10]. In contrast, chorda tympani injury, tympanic membrane perforation, and iatrogenic cholesteatoma risks are higher due to elevation of the external ear canal. Lavinsky and Lavinsky did not report any major complications with this technique [8]. Tympanic membrane perforations, injury to the chorda tympani, and hematoma were seen in our patients.

In the suprameatal approach, the tympanomeatal flap is elevated and the middle ear is reached without mastoidectomy. The round window or cochleostomy area is identified. The suprameatal region is drilled to reach the incus and the electrode is sent through the tunnel rather than being placed in the cochleostomy. Not performing a mastoidectomy or posterior tympanotomy and no risk of facial nerve injury are the advantages of this technique. Dura mater and chorda tympani injury, and tympanic membrane perforation are possible complications [11]. Postelmans et al. [11] reported a major complication rate of 3.7% (4 of 107 patients) and a minor complication rate of 23.4% (25 of 107 patients). In our study, tympanic membrane perforation was seen in one patient and electrode extrusion was seen in two patients.

Another technique used in difficult cases is resection of the bony part of the external ear canal followed by reconstruction [12]. In this technique, mastoidectomy is followed by tympanomeatal flap elevation, and then the bony part of the external ear canal is resected. The round window and promontorium are visualized, the electrode is placed, and finally, the posterior wall of the external ear canal is reconstructed with bone or cartilage grafts. Tympanic membrane perforation and retraction, cholesteatoma, and facial nerve injury are the possible complications. In our series, major complications, such as facial nerve injury and meningitis, were not seen. Chorda tympani injury was seen in two patients and hematoma was reported in one patient. Cholesteatoma was not seen in our patients who were operated with these three types of alternative implant technique.

The middle fossa approach is another technique that can be performed in patients with an ossified cochlea, chronic suppurative otitis media, or inner ear abnormalities. In this method, the electrode is placed in the basal turn of the cochlea. After the preparations, the superolateral part of the petrous portion of the temporal bone is identified. The middle meningeal artery is found and separated from the dura mater. The roof of the middle cranial fossa, the superficial petrous nerve, arcuate eminence, and the superior petrosal sinus are identified. After that, cochleostomy is performed through the basal turn of the cochlea. This procedure is challenging, even in experienced hands. Facial nerve and cerebrovascular injuries are possible complications of this procedure [13].

Subtotal petrosectomy and middle cavity obliteration is another alternative technique for cochlear implantation. This technique can be used, particularly in patients who have chronic otitis media [14].

With the use of endoscopes becoming more widespread, otoendoscopes have taken their place in ear surgery. They are also used in cochlear implantation. After elevation of the tympanomeatal flap, middle ear structures, such as the round window and promontorium, can be identified clearly with 0- or 30-degree endoscopes. Cochleostomy can also be performed safely with endoscopic assistance. Endoscopes can also be used in alternative implant techniques.

In conclusion, cochlear implantation is an effective method in the rehabilitation of sensorineural hearing loss. Complications are rare but can include hematoma, taste impairment, tympanic membrane perforation, cholesteatoma, facial paralysis, electrode extrusion, or wound infection. The standard procedure is not suitable for patients with temporal bone abnormalities. Surgeons performing cochlear implantation should be aware of these variations and be able to perform alternative implant techniques.

Ethics Committee Approval: Ethics committee approval was received for this study from the ethics committee of Çukurova University, Adana.

Informed Consent: Written informed consent was obtained from patients who participated in this study.

Peer-review: Externally peer-reviewed.

Author Contributions: Concept - Ö.S., Ü.T.; Design - Ö.S., Ü.T.; Supervision - M.K., F.Ç., Ü.T.; Resources - Ö.S., Ö.T., S.Ö., K.K.; Materials - Ö.S., Ö.T., S.Ö., K.K.; Data Collection and/or Processing - Ö.S., K.K.; Analysis and/or Interpretation - Ö.S., S.Ö., Ö.T., Ü.T.; Literature Search - Ö.S., K.K.; Writing Manuscript - Ö.S., Ü.T.; Critical Review - M.K., F.C.

Conflict of Interest: No conflict of interest was declared by the authors.

Financial Disclosure: The authors declared that this study has received no financial support.

REFERENCES

1. House WF. Cochlear implants. *Ann Otol Rhinol Laryngol* 1976; 85: 1-93.
2. Cohen NL, Hoffman RA. Complications of cochlear implant surgery in adults and children. *Ann Otol Rhinol Laryngol* 1991; 100: 708-11. [\[CrossRef\]](#)
3. Kiratzidis T, Arnold W, Iliades T. Veria operation updated. I. The trans-canal wall cochlear implantation. *ORL J Otorhinolaryngol Relat Spec* 2002; 64: 406-12. [\[CrossRef\]](#)
4. Hehar SS, Nikolopoulos TP, Gibbin KP, O'Donoghue GM. Surgery and functional outcomes in deaf children receiving cochlear implants before age 2 years. *Arch Otolaryngol Head Neck Surg* 2002; 128: 11-4. [\[CrossRef\]](#)
5. Kronenberg J, Migirov L, Dagan T. Suprameatal approach: new surgical approach for cochlear implantation. *J Laryngol Otol* 2001; 115: 283-5. [\[CrossRef\]](#)
6. Kiratzidis T, Iliades T, Arnold W. Veria operation. II. Surgical results from 101 cases. *ORL J Otorhinolaryngol Relat Spec* 2002; 64: 413-6. [\[CrossRef\]](#)
7. Lavinsky L, Lavinsky M. Implante coclear - vias de acesso. In: Lavinsky L. *Tratamento em otologia*. 1st ed. Rio de Janeiro: Revinter; 2006: 466-72.
8. Lavinsky L, Lavinsky M. Combined approach technique to cochlear implantation. *Otolaryngol Head Neck Surg* 2006; 135 (2S): 258-9. [\[CrossRef\]](#)
9. Lavinsky L, Lavinsky-Wolff M, Lavinsky J. Transcanal cochleostomy in cochlear implantation: experience with 50 cases. *Cochlear Implants Int* 2010; 11: 228-32.
10. Wolf ML, Lawinsky L, Setogutti E. Transcanal cochleostomy in cochlear implant surgery: long-term results of a cohort study. *Braz J Otorhinolaryngol* 2012; 78: 118-23.
11. Postelmans JT, Tange RA, Stokroos RJ, Grolman W. The suprameatal approach: a safe alternative surgical technique for cochlear implantation. *Otol Neurotol* 2010; 31: 196-203. [\[CrossRef\]](#)
12. Carfrae MJ, Foyt D. Intact meatal skin, canal wall down approach for difficult cochlear implantation. *J Laryngol Otol* 2009; 123: 903-6. [\[CrossRef\]](#)
13. Bittencourt AG, Tsuji RK, Tempestini JPR, Alfredo Luiz Jacomo AL, Bento RFB. Cochlear implantation through the middle cranial fossa: a novel approach to access the basal turn of the cochlea. *Braz J Otorhinolaryngol* 2013; 79: 158-62. [\[CrossRef\]](#)
14. Issing PR, Schonemark MP, Winkelmann S, Kempf HG, Ernst A, Lenarz T. Cochlear implantation in patients with chronic otitis: Indications for subtotal petrosectomy and obliteration of the middle ear. *Skull Base Surg* 1998; 8: 127-31. [\[CrossRef\]](#)