



Original Article

Does Diffusion-Weighted MR Imaging Change the Follow-Up Strategy in Cases with Residual Cholesteatoma?

Yusuf Dündar, Fatih Alper Akcan, Alper Dilli, Emel Tatar, Hakan Korkmaz, Ali Özdek

Department of Otolaryngology, Ministry of Health, Rize Çayeli State Hospital, Rize, Turkey (YD)

Department of Otolaryngology, Ankara Children's Hematology and Oncology Training and Research Hospital, Ankara, Turkey (FAA)

Department of Radiology, Ministry of Health, Dışkapı Yıldırım Beyazıt Training and Research Hospital, Ankara, Turkey (AD)

Department of Otolaryngology, Ministry of Health, Dışkapı Yıldırım Beyazıt Training and Research Hospital, Ankara, Turkey (ET)

Department of Otolaryngology, Yıldırım Beyazıt University Medical School, Ankara, Turkey (HK)

Department of Otolaryngology, Karabük University Medical School, Karabük, Turkey (AO)

OBJECTIVE: To analyze the effectiveness of diffusion-weighted magnetic resonance imaging (DW-MRI) in the evaluation of recurrent cholesteatomas.

MATERIALS and METHODS: Twenty-three patients undergoing second-look surgery were included in our study. There were 14 men and 9 women with ages ranging from 10 to 50. All patients underwent DW-MRI prior to second-look surgery. All magnetic resonance imaging (MRI) examinations were performed with a 1.5-T MRI unit using a standard 8-channel neurovascular coil. DW-MRI and apparent diffusion coefficient maps were included in the examination. Cholesteatoma was diagnosed on the DW-MRI as a marked hyperintense signal in comparison with brain tissue. All cases were classified as positive or negative.

RESULTS: The sensitivity and specificity of DW-MRI were 86% and 87%, respectively. The positive predictive value of DW-MRI was 92%, while the negative predictive value was 77%.

CONCLUSION: The DW-MRI technique is an important and effective technique in the evaluation of residual cholesteatoma. It can be an alternative method to second-look surgery, which can spare patients repeat operations.

KEYWORDS: Cholesteatoma, diffusion-weighted imaging, second look surgery

INTRODUCTION

Cholesteatoma is a collection of keratin in the temporal bone, which can be congenital or acquired ^[1]. Acquired cholesteatomas are mainly seen in the middle ear or mastoid; otherwise, congenital cholesteatoma can be observed anywhere in the temporal bone, such as the cerebellopontine angle and petrous apex. The treatment of cholesteatoma is surgical excision, the technique of which depends on the location and size of the cholesteatoma. Small-sized attic cholesteatomas can be excised through transcanal atticotomy, but many times, surgeons need a large exposure. Canal wall up (CWU) or canal wall down (CWD) tympanoplasty techniques provide large exposure in the widespread disease. Both techniques have special characteristics according to intraoperative exposure level, recurrence rates, hearing level, and self-cleansing ability. The CWU technique mainly consists of the posterior tympanotomy approach for the purpose of preserving the posterior ear canal. This technique provides a self-cleansing ability and better hearing results with higher recurrence rates ^[2]. The CWD technique requires intensive post-operative care due to the loss of self-cleansing ability. This technique has lower recurrence rates than the CWU technique. Recurrence occurs within 2 years, with 60% of them in the first post-operative year ^[3]. The recurrence rates of CWU and CWD techniques are 9%-70% and 4%-15%, respectively ^[2]. Each technique has strong advocates, many of them being experienced surgeons. The relatively high recurrence rate of the CWU technique leads to staged second-look procedures as a part of the operation.

The current traditional approach is two-stage surgeries in extensive disease. Second-look surgery is often performed 6-18 months after the first operation ^[4,5]. The percentage of recurrent cholesteatoma findings in second-look surgeries is changing between 10%-44% ^[2]. More than one-half of second-stage operations are being only performed for the evaluation of the middle ear. This situation leads to unnecessary operations performed in half of the second-stage surgeries. Computerized tomography (CT) is important for preoperative evaluation, but it can not sufficiently distinguish between post-operative granulation tissue and cholesteatoma.

Corresponding Address:

Yusuf Dündar, Ministry of Health, Rize Çayeli State Hospital, Otolaryngology, Rize, Turkey

Phone: +1(801)809-4290; E-mail: ysfndr@gmail.com

Submitted: 13.11.2014

Accepted: 16.11.2014

Available Online Date: 26.02.2015

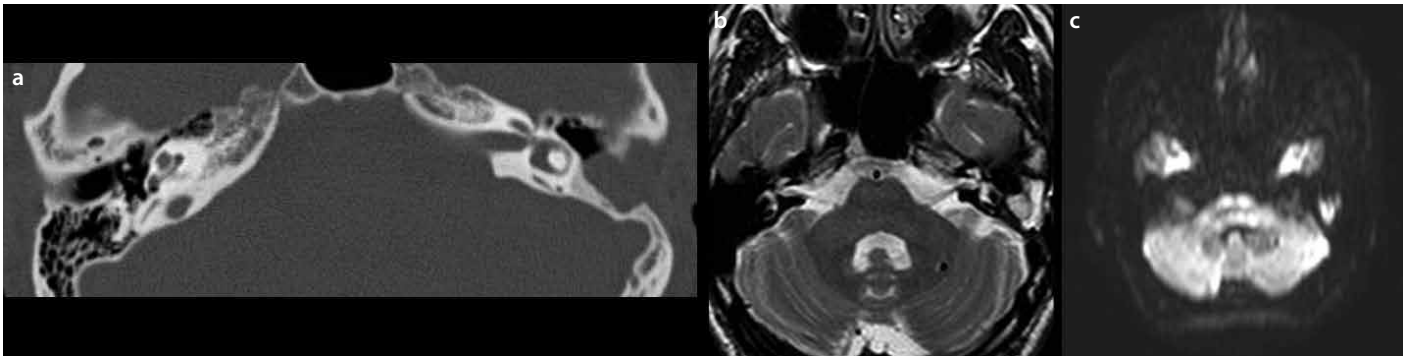


Figure 1. a-c. a. CT of soft tissue density in the operated cavity. b. MRI-T2 of soft tissue density in the operated cavity. c. DW-MRI of a hyper-intense signal in the mastoidectomy cavity

Diffusion-weighted magnetic resonance imaging (DW-MRI) has been advocated as an alternative to second-look operations in the evaluation of recurrent/residual disease [6, 7]. Granulation tissues become more conspicuous following contrast administration in DW-MRI because of the poorly vascularized structure versus cholesteatomas. This technique is an important and the newest method in cholesteatoma imaging. This new technique may provide us satisfactory data and may replace the classical second-stage operations. The current data support the strong predictive value of DW-MRI in the detection of recurrent disease.

We aimed to analyze the effectiveness of diffusion-weighted MR imaging in the evaluation of recurrent cholesteatomas.

MATERIALS and METHODS

Study Design

Our prospective study was performed in a tertiary referral center in Turkey. Second-look surgery, planned for 43 patients, was conducted between 2006 and 2010. Ethics committee approval was obtained from the ethic committee of Dışkapı Yıldırım Beyazıt Training and Research Hospital. All patients were informed about the study, and informed/signed consent forms were collected prior to the study. Eleven patients who did not attend regular follow-up visits were excluded from the study. Thirty-two patients were detected by CT and pure tone audiograms. CT findings did not raise a suspicion of residual cholesteatoma, and the pure tone audiogram test was associated with normal hearing levels in 9 patients. Second-look surgery and routine follow-up options were considered for these 9 patients in light of the current data; however, they did not accept second-look surgery. The rest of the 23 patients who underwent second-look surgery were included the study. Twenty patients had soft tissue in the operated cavity, but 3 patients' CT findings were not associated with a suspicion of residual cholesteatoma. Second-look surgery was considered in 2 of 3 patients with the indication of hearing reconstruction (Patients 15-17). The other patient (Patient 7) was included in the study due to suspected otoscopic findings. Then, 23 patients were detected preoperatively by DW-MRI. DW-MRI was performed 1 to 3 weeks before the second surgery. As the gold standard method, second-look surgery was performed 7-28 months after the first operation for the evaluation of the presence of recurrent/residual cholesteatoma. The validity of imaging techniques against second-look surgery for ruling out recurrent cholesteatoma was analyzed.

Patients

Thirty-two second-look surgery-planned patients were evaluated. Twenty-three patients were included in the study. There were 14 men and 9 women, with ages ranging from 10 to 50 (average age: 33.6 yrs) years.

Imaging Technique

All MRI examinations were performed with a 1.5-T MRI unit (Philips Achiva, Philips Medical Systems, Eindhoven, Netherlands) using a standard 8-channel neurovascular coil. DWI and ADC maps were included in the examination. DWI (FOV, 230×230 mm; Epi factor, 61; thickness/gap, 5/1 mm; acquisition matrix, 112×89) was performed by using b values of 0 and 1000 s/mm² in axial, multisection, single-shot, echo-planar imaging sequence. TE was taken as short as possible for the acquisition of the highest signal-to-noise ratio. Diffusion gradients were applied in 3 orthogonal directions simultaneously. The ADC maps were reconstructed with commercially available software.

Imaging Evaluation

An experienced neuroradiologist reported the DW-MRIs. Cholesteatoma was diagnosed on DWI as a marked hyperintense signal in comparison with brain tissue. All cases were classified as positive or negative.

Statistical Analysis

Data were analyzed using Statistical Package for Social Sciences 11.0 for Windows (SPSS Inc., Chicago, IL, USA). The sensitivity, specificity, and negative and positive predictive values were calculated.

RESULTS

Temporal CT was associated with soft tissue in the middle ear and post-operative cavity in 20 of 23 patients (Figure 1a). DW-MRI indicated the presence of a cholesteatoma in 14 of 23 patients (Figure 1c). There were true positive findings in 13 patients. The residual cholesteatoma rate was 56% of 23 patients. These 13 true positive patients had hyperintense signals in comparison with brain tissue in MRI sequences (Figure 1b). The size of the cholesteatomas was between 2 to 12 mm. One patient was a false positive, and cholesteatoma was not detected in second-look surgery.

Nine patients were evaluated as a negative DW-MRI finding; 7 of 9 were true negatives, and 2 of 9 were false negatives (Table 1). Two false negative patients had residual cholesteatomas smaller than

Table 1. Patients' imaging and intra-operative findings

Patient	CT	DW-MRI	Surgery	
1.S.B.	+	+	-	False positive
2.İ.H.	+	-	-	True negative
3.B.T.	+	+	+	True positive
4.R.Ş	+	-	-	True negative
5.E.K.	+	+	+	True positive
6.B.B.	+	+	+	True positive
7.F.A.	-	-	-	True negative
8.N.A.	+	-	-	True negative
9.M.T.	+	+	+	True positive
10.G.S.	+	-	+	False negative
11.A.Ç.	+	+	+	True positive
12.E.E.	+	+	+	True positive
13.N.A.	+	+	+	True positive
14.A.A.	+	+	+	True positive
15.M.A.	-	-	+	False negative
16.Y.D.	+	+	+	True positive
17.F.M.	+	-	-	True negative
18.S.Ü.	+	-	-	True negative
19.Z.Ö.	-	-	-	True negative
20.A.Ö.	+	+	+	True positive
21.A.O.	+	+	+	True positive
22.İ.A.	+	+	+	True positive
23.A.T.	+	+	+	True positive

Table 2. Statistical findings

	DW-MRI (+)	DW-MRI (-)	
Surgery (+)	13 (true positive)	2 (false negative)	15
Surgery (-)	1 (false positive)	7 (true negative)	8
	14	9	

3 mm detected during surgery. Interestingly, patient 15, who was operated on for hearing reconstruction, did not demonstrate any suspected CT, MRI, or otoscopic findings. About 2 mm of residual cholesteatoma was detected in the middle ear of the patient.

The sensitivity and specificity of DW-MRI were 86% and 87%, respectively (Table 2). The positive and negative predictive values of DW-MRI were 92% and 77%, respectively (Table 2). If we excluded the patients who had residual cholesteatomas smaller than 3 mm, the negative predictive value was 100%.

DISCUSSION

Cholesteatoma is an epidermoid cyst that contains desquamating stratified squamous epithelium. It destroys the neighboring bony structures by mass effect and osteolytic enzymes. The treatment of cholesteatoma depends on surgical excision. Radical mastoidectomy was the only therapeutic option at the beginning of the 20th century. This technique mainly avoids intracranial complications, which lead

to profound hearing loss. After describing microsurgical techniques, preservation of hearing was aimed with the removal cholesteatoma. Extraction of the cholesteatoma with preserved aeration of the middle ear and functional ossicular chain is known as modified radical mastoidectomy. The current surgical approach to the cholesteatoma can be divided into two main categories according to posterior auditory canal wall situation. The CWU technique saves the posterior auditory canal wall and consists of a posterior tympanotomy approach. The CWD technique does not preserve the posterior auditory canal wall with wide exposure. The CWD technique has lower recurrence rates, requiring more intensive post-operative care, due to loss of the self-cleaning ability. The CWU technique preserves the self-cleaning ability, with higher recurrence rates. The recurrence rates of the CWD technique were reported as 4% to 15% in the English medical literature [2]. The rate of recurrence is 9% to 70% in the CWU technique [2]. These rates indicate that the CWU technique carries more than twice the recurrence risk of the CWD technique. That is why two-staged surgeries are commonly used in CWU techniques. Second-stage surgery helps to detect and treat recurrent disease. Some surgeons prefer ossicular chain reconstruction in the second stage. But, many times, second-look surgeries are used for only excluding recurrent disease. We performed second-look surgeries in this study in the case of a suspected residual/recurrent cholesteatoma and for ossicular chain reconstruction. Suspected residual/recurrent cholesteatoma was considered according to a clinical examination and CT findings.

High-resolution CT is widely used for pre-operative evaluation and planning of second-look procedures. It may give lots of information about bony structures but has significant soft tissue limitations. The soft tissue density in high-resolution CT should be distinguished between cholesteatoma and granulation tissue. The pre-operative imaging techniques may help us to detect disease severity and possible intra-operative complications. Additional imaging techniques have an essential role in the post-operative evaluation. Recurrent cholesteatoma can not be distinguished from inflammation or post-operative granulation tissue [8, 9]. The CT imaging results were evaluated as positive for soft tissue density in 20 of 23 patients in our study. However, 14 of 20 cholesteatomas were detected intraoperatively. In addition, one cholesteatoma was detected during the operation despite negative CT findings. Our results support that CT imaging is not an effective way to detect cholesteatoma relative to surgery. MRI is an effective imaging technique for soft tissues. Recent reports advocate DW-MRI as an alternative to second-look procedures [6, 10, 11]. Cholesteatomas do not have a vascular supply and do not enhance after contrast administration. However, granulation tissues have a poor vascular supply and enhance on delayed images. DW-MRI uses this contrast for distinguishing cholesteatomas from granulation tissues. There are many DW-MRI techniques for evaluating cholesteatoma, ranging from traditional spin-echo planar imaging to turbo spin-echo-based techniques, such as HASTE and BLADE [12]. These techniques have variable sensitivity and specificity rates based on slice thickness and their resolution. Vercruysse et al. investigated the utility of echo planar DWI in 100 patients, including 55 primary cases with acquired cholesteatoma and 45 with residual cholesteatomas [13]. The sensitivity of echo planar DWI was reported as 81% for primary acquired cholesteatomas and 12.5% of residual cholesteatomas in this study. The sensitivity of echo planar DWI is very variable in the English medical literature, ranging from 12.5% to 86% [13-17].

The specificity of echo planar DWI ranges from 73% to 100% [13-17]. Our results support the current data. We detected positive DWI findings in 14 of 23 patients. There were 13 true positive subjects, and the sensitivity of the test was 86%. There were 2 false negative results in our study, and the specificity of the test was 87%. Both of these false negative cholesteatomas were less than 3 mm in diameter. Recent studies reported that echo planar imaging may miss recurrent disease smaller than 5 mm in size [16,18]. In addition, very small (2 mm) residual/recurrent cholesteatomas could not be detected in our study. The main limitation of DWI was small cholesteatomas (less than 3 mm); however, the clinical significance of this finding is controversial. Follow-up with serial DWI may solve this problem. Hence, residual disease can be detected when it reaches a size of 3 mm. Unfortunately, there is no study that has focused on this problem. Non-echo planar DWI has advantages in detecting cholesteatomas as small as 2 mm, but still, it is not perfect [13,18]. A recently published systematic review of 8 studies with 207 subjects reports 91% sensitivity and 96% specificity [19] for non-echo planar DWI. DWI may be an effective way to detect recurrent/residual cholesteatomas in light of our results and the current literature.

The incidence of residual cholesteatoma as detected in the second-look surgeries is about 10% to 15% in adults and 23% to 44% in children [20,21]. It means that more than two-thirds of all second-look surgeries have been performed only inspection. Revision surgery causes increased morbidity and hospitalization. An alternative and effective imaging technique is important in these patients. A recently published meta-analysis has reported that DW-MRI is a useful and effective imaging technique [22] in the detection of recurrent cholesteatomas. According to all current data, second-look surgeries are not cost-effective, with probable morbidities [23,24] in the detection of recurrent cholesteatomas.

The main limitation of the study is that 23 patients were included in this investigation. A large series may be needed for more powerful results. Another limitation is that we excluded 9 patients from the study according to their pure tone audiogram and CT findings, and also, they did not accept second-look surgery. We can never know whether these cases were really true negatives without doing surgery in consideration of the current data.

Diffusion-weighted magnetic resonance imaging is a helpful and effective method for distinguishing cholesteatomas from other soft tissues in operated patients. It reduces the surgical risks and cost. The DW-MRI technique should be used in second-look surgery, which can spare patients from recurrent operations. Case series and sub-group investigations are important for a routine follow-up technique. The use of DW-MRI will likely reduce the need for second-look surgery, with a potential decrease in associated morbidity and surgical costs.

We would like to contribute to the literature on this topic.

Ethics Committee Approval: Ethics committee approval was obtained for this study from the ethics committee of Dışkapı Yıldırım Beyazıt Training and Research Hospital.

Informed Consent: Written informed consent was obtained from the patients who participated in this study.

Peer-review: Externally peer-reviewed.

Author Contributions: Concept - Y.D., F.A.A., A.D., A.O.; Design - Y.D., F.A.A., A.O.; Supervision - H.K., A.O.; Materials - Y.D., F.A.A., A.D., A.O.; Data Collection and/or Processing - F.A.A., E.T.; Analysis and/or Interpretation - F.A.A., H.K., A.O.; Literature Review - Y.D., F.A.A.; Writer - Y.D.; Critical Review - H.K., A.O.

Conflict of Interest: No conflict of interest was declared by the authors.

Financial Disclosure: The authors declared that this study has received no financial support.

REFERENCES

- Swartz JD. Temporal bone inflammatory disease. In: Som PM, Curtin HD, eds. Head and Neck Imaging. 3rd ed. St. Louis: Mosby; 1996: 1391-424.
- Ho SY, Kveton JF. Efficacy of the 2-staged procedure in the management of cholesteatoma. Arch Otolaryngol Head Neck Surg 2003; 129: 541-5. [CrossRef]
- Migirov L, Tal S, Eyal A, Kronenberg J. MRI, not CT, to rule out recurrent cholesteatoma and avoid unnecessary second-look mastoidectomy. Isr Med Assoc J 2009; 11: 144-6.
- Shelton C, Sheehy JL. Tympanoplasty: review of 400 staged cases. Laryngoscope 1990; 100: 679-81. [CrossRef]
- Gyo K, Sasaki Y, Hinohira Y, Yanagihara N. Residue of middle ear cholesteatoma after intact canal wall tympanoplasty: surgical findings at one year. Ann Otol Rhinol Laryngol 1996; 105: 615-9. [CrossRef]
- Martin N, Sterkers O, Nahum H. Chronic inflammatory disease of the middle ear cavities: Gd-DTPA-enhanced MR imaging. Radiology 1990; 176: 399-405. [CrossRef]
- Williams MT, Ayache D, Alberti C, Heran F, Lafitte F, Elmaleh-Berges M, et al. Detection of postoperative residual cholesteatoma with delayed contrast-enhanced MR imaging: initial findings. Eur Radiol 2003; 13: 169-74.
- Kosling S, Bootz F. CT and MRI imaging after middle ear surgery. Eur Radiol 2001; 40: 113-8. [CrossRef]
- Blaney SP, Tierney P, Oyarazabal M, Bowdler DA. CT scanning in second look combined approach tympanoplasty. Rev Laryngol Otol Rhinol 2000; 121: 79-81.
- Lela M, Sigal T, Ana E, Jona K. MRI, not CT, to rule out recurrent cholesteatoma and avoid unnecessary second-look mastoidectomy. Isr Med Assoc J 2009; 11: 144-6.
- De Foer B, Vercruysse JP, Spaepen M, Somers T, Pouillon M, Offeciers E, et al. Diffusion-weighted magnetic resonance imaging of the temporal bone. Neuroradiology 2010; 52: 785-807. [CrossRef]
- Schwartz KM, Lane JI, Bolster BD Jr, Neff BA. The utility of diffusion-weighted imaging for cholesteatoma evaluation. AJNR Am J Neuroradiol 2011; 32: 430-6. [CrossRef]
- Vercruysse JP, De Foer B, Pouillon M, Somers T, Casselman J, Offeciers E. The value of diffusion-weighted MR imaging in the diagnosis of primary acquired and residual cholesteatoma: a surgical verified study of 100 patients. Eur Radiol 2006; 16: 1461-7. [CrossRef]
- Venail F, Bonafe A, Poirrier V, Mondain M, Uziel A. Comparison of echo-planar diffusion-weighted imaging and delayed postcontrast T1-weighted MR imaging for the detection of residual cholesteatoma. AJNR Am J Neuroradiol 2008; 29: 1363-8. [CrossRef]
- Jeunen G, Desloovere C, Hermans R, Vandecaveye V. The value of magnetic resonance imaging in the diagnosis of residual or recurrent acquired cholesteatoma after canal wall-up tympanoplasty. Otol Neurotol 2008; 29: 16-8. [CrossRef]
- Aikele P, Kittner T, Offergeld C, Kaftan H, Hüttenbrink KB, Laniado M. Diffusion-weighted MR imaging of cholesteatoma in pediatric and adult patients who have undergone middle ear surgery. AJR Am J Roentgenol 2003; 181: 261-5. [CrossRef]
- Stasolla A, Magliulo G, Parrotto D, Luppi G, Marini M. Detection of post-operative relapsing/residual cholesteatoma with diffusion-weighted echo-planar magnetic resonance imaging. Otol Neurotol 2004; 25: 879-84. [CrossRef]

18. De Foer B, Vercruysse JP, Bernaerts A, Maes J, Deckers F, Michiels J, et al. The value of single-shot turbo spin-echo diffusion-weighted MR imaging in the detection of middle ear cholesteatoma. *Neuroradiology* 2007; 49: 841-8. [\[CrossRef\]](#)
19. Jindal M, Riskalla A, Jiang D, Connor S, O'Connor AF. A systematic review of diffusion-weighted magnetic resonance imaging in the assessment of postoperative cholesteatoma. *Otol Neurotol* 2011; 32: 1243-9. [\[CrossRef\]](#)
20. Dubrulle F, Souillard R, Chechin D, Vaneecloo FM, Desautly A, Vincent C. Diffusion-weighted MR imaging sequence in the detection of postoperative recurrent cholesteatoma. *Radiology* 2006; 238: 604-10. [\[CrossRef\]](#)
21. Schilder AG, Govaerts PJ, Somers T, Offeciers FE. Tympano-ossicular allografts for cholesteatoma in children. *Int J Pediatr Otorhinolaryngol* 1997; 42: 31-40. [\[CrossRef\]](#)
22. Li PM, Linos E, Gurgel RK, Fischbein NJ, Blevins NH. Evaluating the utility of non-echo-planar diffusion-weighted imaging in the preoperative evaluation of cholesteatoma: a meta-analysis. *Laryngoscope*. 2013; 123: 1247-50. [\[CrossRef\]](#)
23. Mateos-Fernández M, Mas-Estellés F, de Paula-Vernetta C, Guzmán-Calvete A, Villanueva-Martí R, Morera-Pérez C. The role of diffusion-weighted magnetic resonance imaging in cholesteatoma diagnosis and follow-up. Study with the diffusion PROPELLER technique. *Acta Otorrinolaringol Esp* 2012; 63: 436-42. [\[CrossRef\]](#)
24. Corrales CE, Blevins NH. Imaging for evaluation of cholesteatoma: current concepts and future directions. *Curr Opin Otolaryngol Head Neck Surg* 2013; 21: 461-7. [\[CrossRef\]](#)