



Original Article

Diameter of the Medial Side of the Cochlear Aqueduct Is Narrower in Meniere's Disease: A Radiologic Analysis

Chan Il Song, Woo Seok Kang, Jeong Hyun Lee, Jong Woo Chung

Department of Otorhinolaryngology Head and Neck Surgery, Jeju National University School of Medicine, Jeju, Korea (CIS)

Department of Otorhinolaryngology Head and Neck Surgery, Asan Medical Center, University of Ulsan College of Medicine, Seoul, Korea (WSK, JWC)

Department of Radiology, Asan Medical Center, University of Ulsan College of Medicine, Seoul, Korea (JHL)

OBJECTIVE: This study aimed to measure the radiological dimensions of the cochlear aqueduct in Meniere's disease and in low-frequency hearing loss (LFHL) patients and control patients.

MATERIALS and METHODS: Groups of 26 patients (32 ears, including 6 with bilateral involvement) with Meniere's disease, 14 patients (18 ears) with LFHL, and 23 patients with unilateral chronic otitis media, as controls, were enrolled. For the measurements, high-resolution computed tomography (HRCT) of the temporal bone was performed. The cochlear aqueduct was evaluated for the following six parameters: medial opening (MO), petrous apex (PA), otic capsule (OC), lateral opening (LO), distance of the cochlear aqueduct (DC), and length of the cochlear aqueduct (LC).

RESULTS: The PA, OC, DC, and LC were not significantly different between the groups. LO could not be measured because the LO was not visible in all cases. The MO diameter was narrower in the Meniere's disease group than in the LFHL group ($p=0.001$) and in the controls ($p=0.035$). When the dimensions of both ears were measured in patients with unilateral Meniere's disease, no statistically significant difference was found.

CONCLUSION: Compared to LFHL and controls, the MO of the cochlear aqueduct was significantly smaller in the Meniere's disease group.

KEYWORDS: Cochlear aqueduct, Meniere disease, radiology, perilymph

INTRODUCTION

Increased endolymphatic volume is a pathological characteristic of Meniere's disease. A pressure difference exists between the endolymph and perilymph^[1]. Because the perilymph of the inner ear can be derived from the cerebrospinal fluid (CSF), gaining an understanding of the role of the cochlear aqueduct, i.e., the connection between the subarachnoid space and scala tympani, is important. There have been sporadic reports of temporary and permanent hearing loss after lumbar puncture, spinal anesthesia, and neurosurgeries^[2–5]. Recently, Lim et al.^[6] reported an increased hearing threshold after elective VP shunt surgery. They argued that pressure changes in the CSF can induce pressure changes in the inner ear. One possible connective route between the CSF space and inner ear is the cochlear aqueduct. Additionally, animal studies have indicated that CSF loss can influence the inner ear physiology^[7,8]. Indeed, a reduction in CSF volume can induce hearing loss. Walsted collected data from 32 patients who had undergone neurosurgical procedures under general anesthesia. In half of the 32 patients, hearing was decreased by at least 15 decibels (dB) for more than one frequency after surgery^[9]. Based on this observation, it was proposed that CSF pressure transmitted to the perilymph via the cochlear aqueduct could induce transitory endolymphatic expansion^[9].

In guinea pigs, CSF pressure changes could induce non-linear changes in perilymphatic pressure^[7]. If a similar relationship between CSF and perilymph pressure exists in humans, the dimension of the cochlear aqueduct may be an important contributing factor for maintaining a stable perilymph pressure. Accordingly, our current study aimed to measure the radiological dimensions of the cochlear aqueduct in Meniere's patients, and to compare these values with those obtained from low-frequency hearing loss (LFHL) subjects and control subjects.

MATERIALS and METHODS

Subjects

A total of 26 consecutive patients with Meniere's disease who visited the Department of otorhinolaryngology-Head and Neck Surgery at a tertiary medical center between January 2007 and December 2010 were enrolled and their medical records were analyzed. The patients with Meniere's disease included 7 male and 19 female subjects, whose ages ranged from 18 to 70 years (mean, 41.5 years). The symptomatic periods before the diagnosis of Meniere's disease ranged from 2 to 396 months (mean, 43 months). Among the 26 subjects, 6 patients had bilateral Meniere's disease. As a control group, 23 consecutive patients with unilateral chronic otitis

Corresponding Address: Jong Woo Chung E-mail: jwchung@amc.seoul.kr

Submitted: 27.06.2016

Accepted: 18.07.2016

©Copyright 2016 by The European Academy of Otology and Neurotology and The Politzer Society - Available online at www.advancedotology.org

media who visited between January 2010 and December 2010 were enrolled. The control group included 8 male and 15 female patients, whose age ranged from 15 to 64 years (mean, 39.3 years). They experienced neither vertigo nor tinnitus, and the contralateral ear showed a normal hearing level (i.e., a mean pure tone audiometry threshold <25 dB HL). Fourteen patients with LFHL who visited between January 2007 and December 2010 were also enrolled. Because 4 subjects had bilateral LFHL among the 14 patients, the total number of ears measured was 18 in the LFHL group.

The diagnosis of Meniere's disease was based on a history of vertigo attacks, tinnitus, fluctuating hearing loss, and ear fullness. All the patients were diagnosed with definite Meniere's disease in accordance with the American Academy of Otolaryngology-Head and Neck Surgery criteria [10]. The diagnostic procedure consisted of routine examinations of the ear, nose, and throat, audiological tests, vestibular tests, laboratory tests, blood pressure measurements, electrocochleography (ECoG), and high-resolution computed tomography (HRCT) of the temporal bones and cerebellopontine angles. Individuals with pathological changes of the external ear, tympanic membrane, or middle ear were excluded from this study.

Fourteen patients with LFHL had acute sensorineural hearing loss >30 dB HL at 250 and 500 hertz (Hz), with an air-conduction hearing threshold ≤25 dB HL at high frequencies (1000, 2000, 4000, and 8000 Hz). All the patients had no history of vertigo attack, tinnitus, or ear fullness. Diagnosis of the LTHL was assessed by the criteria suggested by Jung et al. [11].

Measurements of the Dimensions of the Anatomical Structures

The cochlear aqueduct dimensions were measured on the diseased side of the patients with Meniere's disease. Including 6 bilateral Meniere's disease, the total number of ears measured was 32 in the Meniere's group. In the control group, the dimensions of the 23 normal ears were measured. The dimensions of the 18 ears (from 14 patients) with LFHL were also measured. To measure the cochlear aqueduct dimensions, HRCT of the temporal bone was performed in the axial plane with a 0.6 mm thickness. The scanning parameters were as follows: 200 mA, 120 kV, and a rotation time of 1 sec. Measurements were performed electronically based on 5× enlarged images displayed on a monitor. The image display matrix was 1920 × 1080 with a pixel size of 0.311 mm. If a particular region of the cochlear aqueduct was not visible, it was marked as NV (not visible). All the measurements were made in a blinded fashion whereby the computed tomography (CT) scan reviewer was not aware of the diagnosis.

The cochlear aqueduct was evaluated for six parameters using the method described by Jackler and Hwang [4], with some modifications. These six parameters were as follows (Figure 1):

- Medial opening (MO), the diameter at the point where the cochlear aqueduct opens into the brain;
- Petrous apex (PA), the diameter at the junction between the petrous apex and otic capsule;
- Otic capsule (OC), the diameter at the midpoint of the otic capsule;
- Lateral opening (LO), the diameter at the point where the cochlear aqueduct opens into the scala tympani;
- Distance of the cochlear aqueduct (DC), the distance between the lateral end of the cochlear aqueduct and the cochlear basal turn;

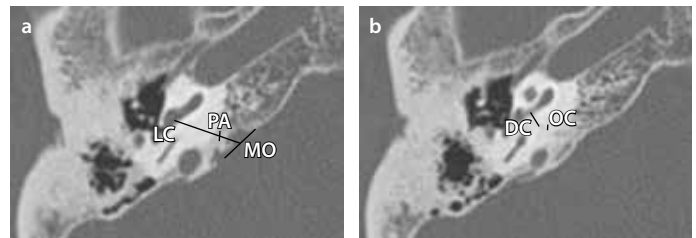


Figure 1. a, b. Axial images of the cochlear aqueduct. The medial opening (MO) was measured in the slice in which the maximal width was observed. The diameter of the petrous apex (PA) was measured at the junction between the petrous apex and otic capsule. The length of the cochlear aqueduct (LC) was measured as the length of its longitudinal axis, from the basal turn of the cochlear to the medial opening (a). The diameter of the otic capsule (OC) was measured at the midpoint of the otic capsule, while the length of the cochlear aqueduct (DC) was measured as the distance between the lateral end of the cochlear aqueduct and the cochlear basal turn (b).

- Length of the cochlear aqueduct (LC), the length of its longitudinal axis, from the basal turn of the cochlea to the medial opening.

Statistical Analyses

Comparisons between two groups (each of three groups) were carried out using the Mann-Whitney test (PASW statistics 18, SPSS Inc.; Chicago, IL, USA). The Mann-Whitney test was also used to detect statistical significances between the lesion and normal sides in unilateral Meniere's disease patients. The Kruskal-Wallis test was used for comparison between the three groups. Data are presented as the mean±standard deviation (SD). P values less than 0.05 were considered as statistically significant. Comparison of the ECoG results of the Meniere's disease and LFHL group were performed using the Mann-Whitney test. Correlation between the ECoG results and the parameters was statistically analyzed with the Spearman correlation coefficient.

Institutional Review Board Approval

This retrospective study was approved by the Institutional Review Board (IRB) of a tertiary medical center for data collection and analysis.

RESULTS

In comparisons with the control group and LFHL group, the lesion side of the Meniere's disease group showed a narrower MO than that of the control group (3.76 ± 0.96 mm vs. 4.56 ± 1.23 mm, $p=0.035$) and that of the LFHL group (5.02 ± 1.20 mm, $p=0.001$). The MO was not significantly different between the control group and the LFHL group ($p=0.207$) (Figure 2). There was no difference in PA, OC, DC, and LC among the three groups (Table 1). LO could not be measured because the LO was not visible for all the cases. When the dimensions were measured in both ears of the same patients with unilateral Meniere's disease ($n=20$), there was no significant difference detected for any of the measurements (MO, PA, OC, DC, or LC) between the lesion and contralateral sides (Table 2).

Electrocochleography was carried out on 24 affected ears of the Meniere's disease patients and on 16 ears of the LFHL patients. Analysis of the ECoG results was performed with the summating potential (SP)/action potential (AP) ratio. The average SP/AP ratios were not different from each other between the Meniere's disease (0.34 ± 0.13) and the LFHL group (0.34 ± 0.12 , $p=0.713$). In addition, the SP/AP ra-

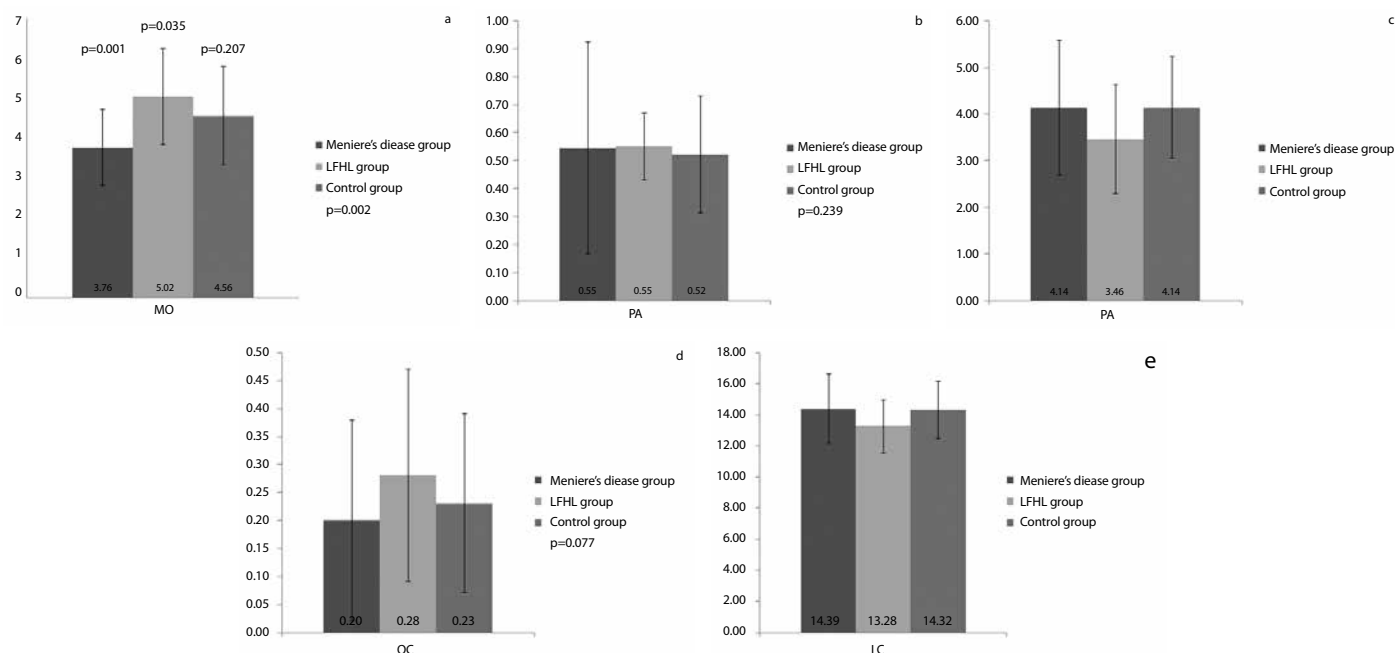


Figure 2. a-e. Comparison of five criteria between the Meniere's disease group, the control group, and the low-frequency hearing loss (LFHL) group. The medial opening (MO) of the lesion side of Meniere's disease patients was significantly narrower than those of the control group ($p=0.035$) and the LFHL group ($p=0.001$). The MO was not significantly different between the control group and the LFHL group ($p=0.207$) (a). The petrous apex (PA, b), otic capsule (OC, c), distance of the cochlear aqueduct (DC, d), and length of the cochlear aqueduct (LC, e) were not significantly different between the three groups.

Table 1. Dimensions of the parameters of the cochlear aqueduct in the three groups

	Meniere's disease group (n=32 ears*, mean±SD)	LFHL group (n=18 ears†, mean±SD)	Control group (n=23 ears, mean±SD)	p
MO	3.76±0.96 mm	5.02±1.20 mm	4.56±1.23 mm	0.002 [‡]
PA	0.55±0.38 mm	0.55±0.12 mm	0.52±0.21 mm	0.239
OC	0.20±0.18 mm	0.28±0.19 mm	0.23±0.16 mm	0.077
DC	4.14±1.45 mm	3.46±1.17 mm	4.14±1.09 mm	0.052
LC	14.39±2.23 mm	13.28±1.71 mm	14.32±1.84 mm	0.103

*Unilateral Meniere's disease, 20 patients; bilateral Meniere's disease, 6 patients.

†Unilateral LFHL, 10 patients; bilateral LFHL, 4 patients.

‡Statistically significant differences.

LFHL: low-frequency hearing loss; SD: standard deviation; MO: medial opening; PA: petrous apex; OC: otic capsule; DC: distance of the cochlear aqueduct; LC: length of the cochlear aqueduct

tios of the Meniere's disease patients and the LFHL patients did not correlate with the five other parameters (MO, PA, OC, DC, and LC) (Figure 3).

DISCUSSION

This study showed that the size of the MO in the Meniere's disease group was significantly smaller than that in the control group and in the LFHL group. Because the patency or diameter of the cochlear aqueduct is related to the pressure regulation of the inner ear^[12], these findings may suggest a mechanism of the pathophysiology of Meniere's disease. In earlier experimental studies that analyzed the relationship between the pressures of the perilymph, CSF, and endolymph, no significant differences in perilymphatic pressure were reported between the Meniere's disease and the normal hearing groups^[12]. By contrast, studies showed that the membranous labyrinth was compliant and that the pressures of the endolymph spaces

Table 2. Comparison between affected and normal ears in the unilateral Meniere's disease patients.

	Affected ear n=20 ears, mean±SD	Normal ear n=20 ears, mean±SD	p
MO	3.73±0.76 mm	4.32±1.17 mm	0.121
PA	0.48±0.12 mm	0.47±0.15 mm	0.620
OC	0.21±0.19 mm	0.17±0.17 mm	0.461
DC	4.08±1.52 mm	3.84±1.19 mm	0.547
LC	14.45±1.91 mm	14.54±2.27 mm	0.968

SD: standard deviation; MO: medial opening; PA: petrous apex; OC: otic capsule; DC: distance of the cochlear aqueduct; LC: length of the cochlear aqueduct

could induce endolymph flow^[13, 14]. Additionally, the cochlear aqueduct was assumed to be the primary outlet for the increased amount of perilymph^[13]. In this scenario, perilymph would be driven through the cochlear aqueduct to establish a pressure balance between the perilymph and CSF in cases of impotent cochlear aqueduct patency. If the patency of the cochlear aqueduct became compromised, the reduction in inflow from the CSF to the perilymph would induce a reduction of the perilymph pressure. The low perilymph pressure makes the endolymph volume expand and could have an effect on endolymphatic hydrops.

Krombach et al.^[15] reported that the mean size of the medial opening was ~3.9 mm and that the mean width at the middle of the canal was ~0.6 mm. In another report, the lateral opening could not be measured in 57.5% (46/80) of the Meniere's disease group cases or in 51.3% (41/80) of the control group cases^[16]. However, in that report the authors did not find a significant difference between the values obtained for patients suffering from Meniere's disease and those obtained for the control group subjects. The mean size of the MO and

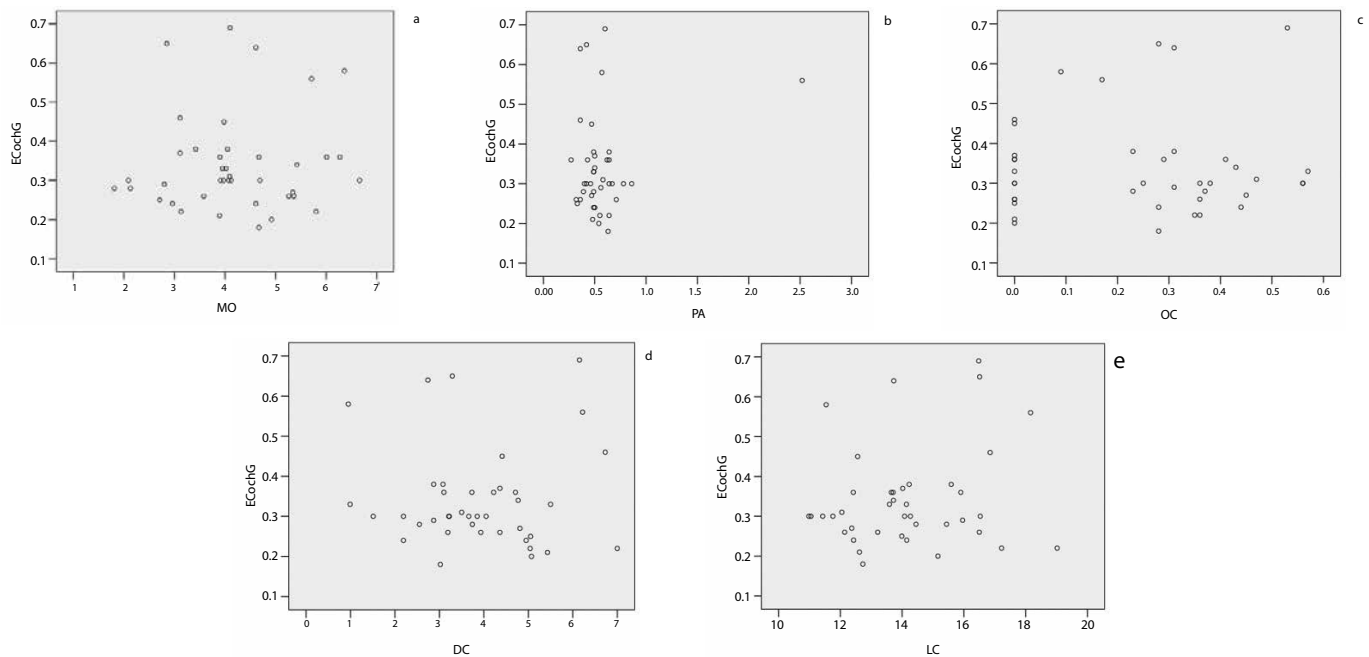


Figure 3. a-e. Scatter plots of the correlation between the summing potential (SP) / action potential (AP) ratio of electrocochleography (ECoG) and the parameters. The SP/AP ratio of ECoG did not have a statistically significant correlation with the medial opening (MO, a), petrous apex (PA, b), otic capsule (OC, c), distance of the cochlear aqueduct (DC, d), or length of the cochlear aqueduct (LC, e) of the Meniere's disease group or the low-frequency hearing loss (LFHL) group.

PA in both the Meniere's disease and control group showed similar statistics with previous studies, while in both groups of the present study, the mean size of the LC was found to be larger. Additionally, in our current patient series, it was not possible to measure the size of the lateral opening for all the cases.

The pathophysiologic mechanism of LTHL was suggested as abrupt cochlear hydrops. Here, as the apex of the cochlea is more sensitive to pressure changes than the basal turn, abrupt cochlear hydrops could be responsible for the isolated acute LTHL, which in turn could produce subsequent hearing loss according to the extension of the hydrops^[17]. Thus the change of pressure seems to be the main mechanism rather than the narrowing of the aqueduct.

To measure the dimensions of the cochlear aqueduct in our study cohort, HRCT of the temporal bone was performed in the axial plane with 0.6 mm collimation and an image display matrix of 1920 × 1080 with a pixel size of 0.311 mm. As the HRCT and image display settings in our study were better than those in earlier studies, we could more accurately measure the size of the cochlear aqueduct and more sensitively detect whether the lateral opening of the cochlear aqueduct was closed or not. We were aware that there could be differences in the anatomy of the cochlear aqueduct that vary according to ethnicity, but, notably in our study, all the subjects were of the same ethnicity, namely far-east Asian Koreans.

Epidemiological studies have shown that some patients with unilateral Meniere's disease progress to bilateral disease several years after the initial disease onset^[18, 19]. Furthermore, some studies have reported histological abnormalities in the contralateral ear in clinically diagnosed unilateral Meniere's disease^[17, 20]. Taken together, the evidence indicates that the contralateral ear of unilateral Meniere's disease cases could potentially be at an increased risk for developing Meniere's dis-

ease. Accordingly, it is notable that the dimensions of the contralateral and symptomatic ears showed no significant differences in patients with unilateral Meniere's disease in our current series.

Conclusion

Compared to the control and LFHL groups, the MO of the cochlear aqueduct was significantly smaller in the Meniere's disease group. These differences may represent predisposing factors for the development of Meniere's disease.

Ethics Committee Approval: Ethics committee approval was received for this study from the ethics committee of Institutional Review Board.

Informed Consent: N/A.

Peer-review: Externally peer-reviewed.

Author Contributions: Concept - J.W.C.; Design - J.W.C.; Supervision - J.W.C.; Resources - J.W.C., J.H.L.; Materials - J.W.C., J.H.L.; Data Collection and/or Processing - C.I.S., W.S.K.; Analysis and/or Interpretation - C.I.S., W.S.K.; Literature Search - C.I.S., W.S.K., J.W.C.; Writing Manuscript - C.I.S., W.S.K., J.W.C.; Critical Review - J.W.C., J.H.L.

Conflict of Interest: No conflict of interest was declared by the authors.

Financial Disclosure: This work was supported by the National Research Foundation of Korea (NRF) grant funded by the Korean government (MEST) (2011-0026811).

REFERENCES

1. Feijen RA, Segenhout JM, Albers FW, Wit HP. Cochlear Aqueduct Flow Resistance Depends on Round Window Membrane Position in Guinea Pigs. *J Assoc Res Otolaryngol* 2004; 5: 404-10. [\[CrossRef\]](#)
2. Hyun SM, Kang WS, Chung JW. A Case of Bilateral Hearing Loss Following External Ventricular Drainage. *Korean J Otorhinolaryngol-Head Neck Surg* 2011; 54: 158-61. [\[CrossRef\]](#)

3. Pogodzinski MS, Shallop JK, Sprung J, Weingarten TN, Wong GY, McDonald TJ. Hearing loss and cerebrospinal fluid pressure: case report and review of the literature. *Ear Nose Throat J* 2008; 87: 144-7.
4. Jackler RK, Hwang PH. Enlargement of the cochlear aqueduct: fact or fiction? *Otolaryngol Head Neck Surg* 1993; 109: 14-25.
5. Lee SH, Park SH, Park J, Hwang SK. Unilateral hearing loss following shunt placement for normal pressure hydrocephalus with a unilateral patent cochlear aqueduct. *Clin Neurol Neurosurg* 2007; 109: 799-802. [\[CrossRef\]](#)
6. Lim HW, Shim BS, Yang CJ, Kim JH, Cho YH, Cho YS, et al. Hearing loss following ventriculoperitoneal shunt in communicating hydrocephalus patients: a pilot study. *Laryngoscope* 2014; 124: 1923-7. [\[CrossRef\]](#)
7. Thalen EO, Wit HP, Segenhout JM, Albers FW. Dynamics of inner ear pressure change caused by intracranial pressure manipulation in the guinea pig. *Acta Otolaryngol* 2001; 121: 470-6. [\[CrossRef\]](#)
8. Laurens-Thalen EO, Wit HP, Segenhout JM, Albers FW. Direct measurement flow resistance of cochlear aqueduct in guinea pigs. *Acta Otolaryngol* 2004; 124: 670-4. [\[CrossRef\]](#)
9. Walsted A. Effects of Cerebrospinal Fluid Loss on Hearing. *Acta Otolaryngol* 2000; 120: 95-8. [\[CrossRef\]](#)
10. Committee on Hearing and Equilibrium guidelines for the diagnosis and evaluation of therapy in Meniere's disease. American Academy of Otolaryngology-Head and Neck Foundation, Inc. *Otolaryngol Head Neck Surg* 1995; 113: 181-5. [\[CrossRef\]](#)
11. Jung AR, Kim MG, Kim SS, Kim SH, Yeo SG. Clinical characteristics and prognosis of low frequency sensorineural hearing loss without vertigo. *Acta Otolaryngol* 2016; 136: 159-63. [\[CrossRef\]](#)
12. Mateijsen DJ, Rosinck HJ, Wit HP, Albers FW. Perilymphatic pressure measurement in patients with Meniere's disease. *Eur Arch Otorhinolaryngol* 2001; 258: 1-4. [\[CrossRef\]](#)
13. Salt AN, DeMott JE. Longitudinal endolymph movements induced by perilymphatic injections. *Hear Res* 1998; 123: 137-47. [\[CrossRef\]](#)
14. Salt AN. The endolymphatic sinus is a possible detector of endolymph volume status. *Hear Res* 2007; 224: 117-8. [\[CrossRef\]](#)
15. Krombach GA, van den Boom M, Di Martino E, Schmitz-Rode T, Westhofen M, Prescher A, et al. Computed tomography of the inner ear: size of anatomical structures in the normal temporal bone and in the temporal bone of patients with Meniere's disease. *Eur Radiol* 2005; 15: 1505-13. [\[CrossRef\]](#)
16. Yilmazer C, Sennaroglu L, Basaran F, Sennaroglu G. Relationship of the cochlear aqueduct and inner ear pressure in Meniere's disease and in a normal population. *Otol Neurotol* 2001; 22: 534-8. [\[CrossRef\]](#)
17. Merchant SN, Adams JC, Nadol JB Jr. Pathophysiology of Meniere's syndrome: are symptoms caused by endolymphatic hydrops? *Otol Neurotol* 2005; 26: 74-81. [\[CrossRef\]](#)
18. da Costa SS, de Sousa LC, Piza MR. Meniere's disease: overview, epidemiology, and natural history. *Otolaryngol Clin North Am* 2002; 35: 455-95. [\[CrossRef\]](#)
19. House JW, Doherty JK, Fisher LM, Derebery MJ, Berliner KI. Meniere's disease: prevalence of contralateral ear involvement. *Otol Neurotol* 2006; 27: 355-61. [\[CrossRef\]](#)
20. Conlon BJ, Gibson WP. Meniere's disease: the incidence of hydrops in the contralateral asymptomatic ear. *Laryngoscope* 1999; 109: 1800-2. [\[CrossRef\]](#)