



## Clinical Report

# Neurofibroma around the Ear Canal: Report of Three Cases

**Bülent Satar, Yusuf Hıdır, Mehmet Burak Aşık, Ümit Aydın, Mustafa Gerek, İbrahim Yavan**

Department of Otolaryngology and Head and Neck Surgery, Gülhane Military Medicine Academy, Ankara, Turkey (BS, ÜA, MG)

Department of Otolaryngology and Head and Neck Surgery, Egepol Hospital, İzmir, Turkey (YH)

Clinic of Otolaryngology, Şırnak Military Hospital, Şırnak, Turkey (BA)

Department of Pathology, Gülhane Military Medical Academy, Ankara, Turkey (İY)

Facial nerve neurofibromas are an uncommon entity, particularly in the intraparotid region. Three cases are presented herein, including the first reported case of both an intratemporal and intraparotid facial nerve malignant neurofibroma. To the best of our knowledge, this is the first medical publication to describe a neurofibroma involving both the intratemporal and intraparotid regions. The aim of this clinical record was to present the surgical experiences in three cases of intratemporal and intraparotid facial neurofibroma. Of the three cases of neurofibroma included in this report, the first case was a 30-year-old male who initially presented with a parotid mass without facial dysfunction. The other two cases were intratemporal neurofibromas, one of which was confirmed as a plexiform neurofibroma by pathology. These tumors often involve two or more segments of the facial nerve. The outcomes of these tumors are closely related to nerve integrity, preoperative facial nerve function level, and the follow-up period. Neurofibromas are most commonly found with neurofibromatosis type 1 and are characterized by incorporation of the nerve fibers within their matrix. Presentation of the intratemporal facial neurofibromas is variable, with facial palsy most common. Furthermore, the incidence of a solitary neurofibroma of the facial nerve originating in the parotid region is extremely low.

**Keywords:** Facial nerve, neurofibroma, parotid tumor

## INTRODUCTION

Neurofibromas are one of the benign nerve sheath tumors. Schwann cells are the main components of the tumor, with axons, fibroblasts, perineurial cells, and some inflammatory cells being the other elements<sup>[1,2]</sup>. Macroscopically, the tumor appears as a solid, tan-gray, glistening mass that is translucent to light<sup>[3]</sup>. Its growth pattern is either a well-bordered intraneural enlargement or infiltration into the surrounding tissue<sup>[4]</sup>. From a clinicopathological perspective, neurofibromas are classified into some subtypes: localized cutaneous form or localized intraneural form, plexiform subtype, and diffuse and massive subtypes<sup>[3]</sup>. Microscopic techniques may show some variances across the subtypes. The main architecture consists of a mucopolysaccharide-rich matrix, where spindle cells with normochromatic nuclei dominate<sup>[3]</sup>. The tumor is stained with the S-100 protein<sup>[5]</sup>.

Neurofibromas rarely involve nerves around the auricle. Furthermore, facial nerve involvement is a rarer condition. If plexiform neuroma is found, it is more interesting that more than one segment of the facial nerve may be affected. Fadda et al.<sup>[6]</sup> reported that there were only 11 cases with intraparotid facial nerve neurofibromas in the English literature. To the best of our knowledge, one of the three cases in our study is the first case report with a neurofibroma of the facial nerve involving both intratemporal and intraparotid segments in the literature. The other two cases had a neurofibroma of the pinna, one of which also involved the temporomandibular joint (TMJ). Written informed consent was obtained from the patients who were included in this clinical case series.

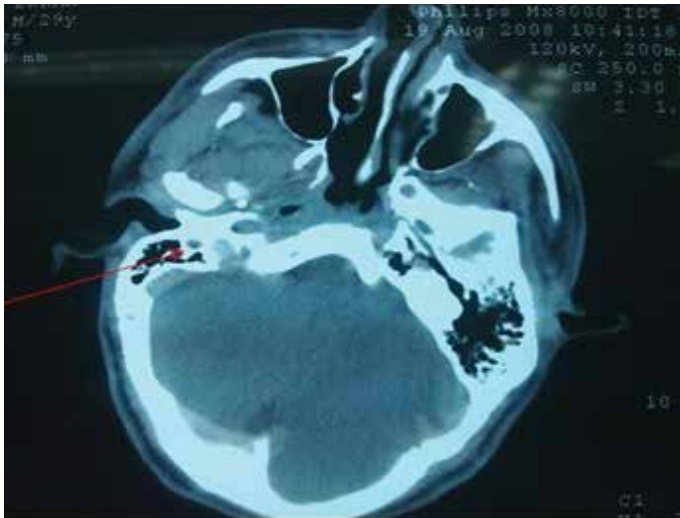
## CASE PRESENTATION

### Case 1

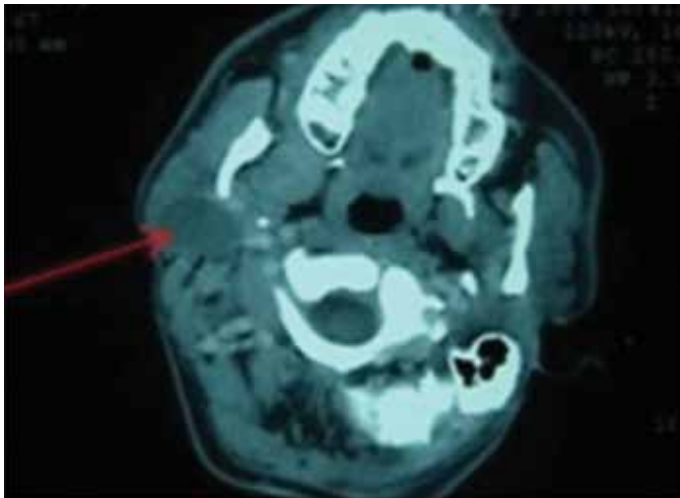
A 30-year-old male presented with a 6-month history of swelling and pain under the right auricle. In the head and neck examination, a fixed and semi-solid mass, approximately 3×3 cm in diameter, was found at the right parotid region under the right auricle. No café-au-lait spots were found in the full body inspection. The facial nerve function was normal. A fine-needle biopsy was reported to be inconclusive for any diagnosis. Parotid ultrasonography showed a solid mass of 26×31×36 mm with smooth contours. Computed tomography (CT) of the neck (without contrast) showed the same mass in the parotid region (Figure 1, 2).

A superficial parotidectomy was planned considering the high possibility of a pleomorphic adenoma. During the dissection, the facial nerve could not be identified. Instead, a solid yellowish bilobed mass was at the site of the nerve (Figure 3). The mass extended towards the stylomastoid foramen. The incision was then extended up to the postauricular region, and an intact canal wall mastoidectomy was performed.

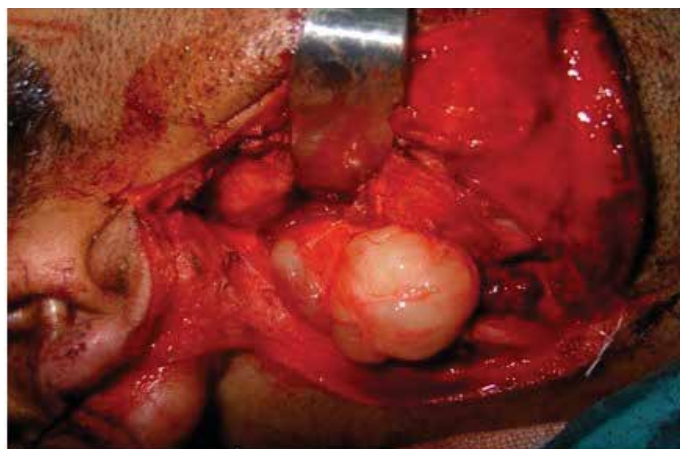
**Corresponding Address:** Mehmet Burak Aşık E-mail: burock312@yahoo.com**Submitted:** 11.11.2015**Revision received:** 22.01.2016**Accepted:** 23.01.2016**Available Online Date:** 03.08.2016©Copyright 2016 by The European Academy of Otolaryngology and Neurotology and The Politzer Society - Available online at [www.advancedotology.org](http://www.advancedotology.org)



**Figure 1.** Axial CT. The arrow shows a slightly mass-enlarged fallopian canal (Case 1)

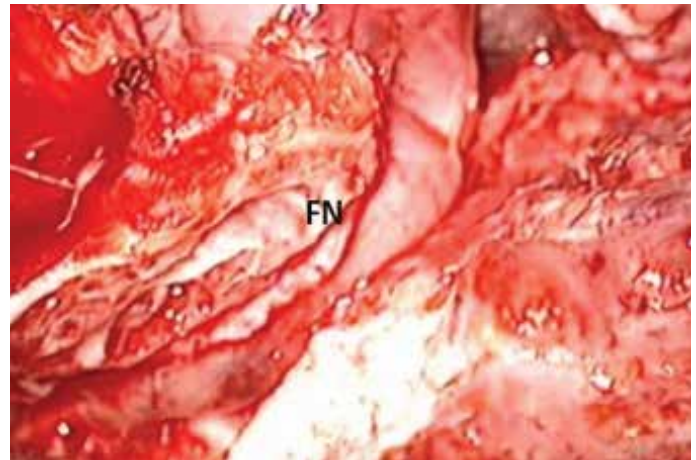


**Figure 2.** Axial CT showing the parotid mass (Case 1)

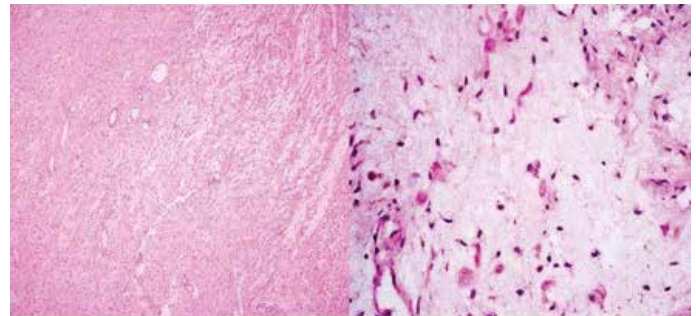


**Figure 3.** Bilobed mass inside the parotid gland (Case 1)

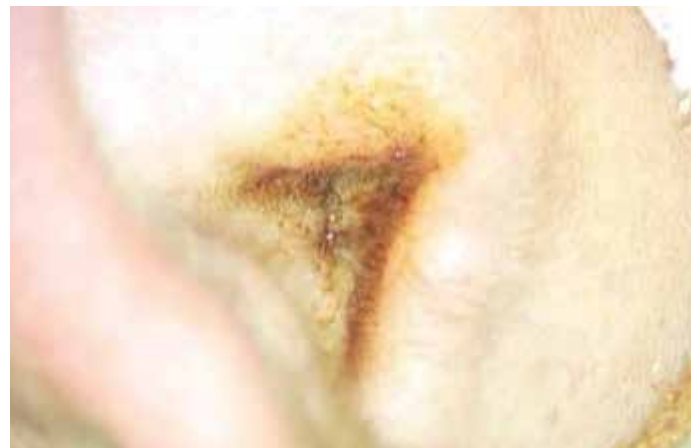tomy was performed. Once the mastoidectomy had been performed, it could be seen that the nerve tumor had enlarged the fallopian canal. The edematous nerve extended up to a few mm away from the second turn of the nerve (Figure 4). Once it was discerned that the tumor originated from the facial nerve, it was decided to wake the patient



**Figure 4.** The tumor involved the nerve in the stylomastoid foramen and second genu (Case 1)



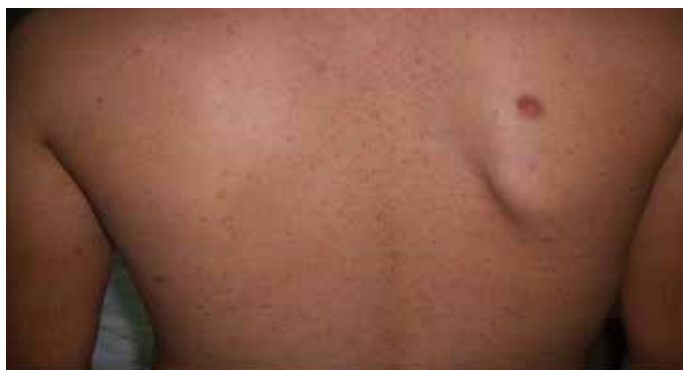**Figure 5.** Neurofibroma with a myxoid matrix containing neoplastic cells and ropey collagen bundles (Case 1)



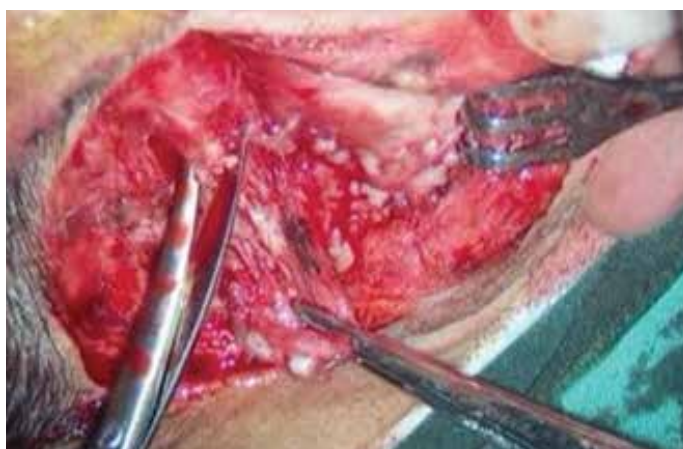
**Figure 6.** The tumor also partly obliterated the ear canal (Case 2) (Continuous line)

to receive an informed consent for further surgery. When the CT was reviewed retrospectively, the enlarged fallopian canal could be noted. Upon receiving the informed consent, the next day, the nerve invaded by the tumor was resected from the parotid bifurcation to the pyramidal segment. A 6-cm nerve graft harvested from the greater auricular nerve was anastomosed to the proximal and distal ends of the nerve. Lateral tarsorrhaphy was also performed, and a specimen was submitted to the pathology clinic for histological examination. Macroscopically, the tumor was a tan-white solid nodule. In the histopathological examination, the tumor contained interlacing bundles of elongated cells with wavy, dark-stained nuclei (Figure 5). The postoperative period was uneventful. At the end of the first year, the patient was able to





**Figure 7.** Numerous café-au-lait spots (Case 2)

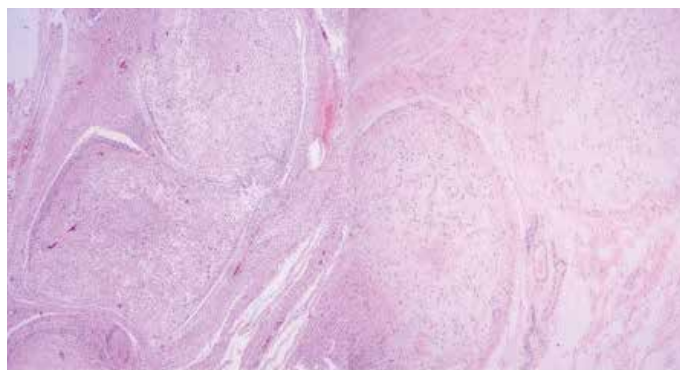


**Figure 8.** Intraoperative view of the tumor in the postauricular region (Case 2)

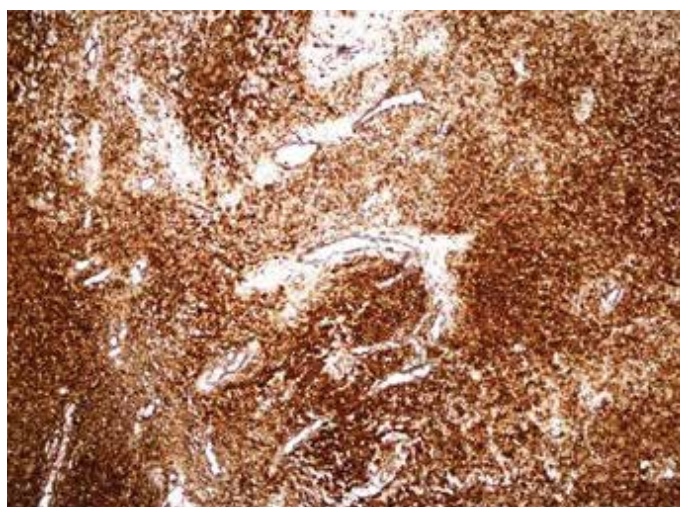
close his eyes without any effort. Interestingly, in the third year, during the winter time, the patient experienced temporary facial dysfunction but recovered after a short course of steroid treatment. The facial nerve examination still shows House–Brackmann Grade 3 facial function.

### Case 2

A 24-year-old male presented with a long history of pain and slight hearing loss in the right ear. In the otoscopic examination, a subcutaneous mass involving the postauricular region and crus helix was found that obliterated the entrance of the right external auditory canal. The facial nerve function was normal, and there was no sensory deficit in the pinna skin. The patient also had lop ears. A pure tone audiogram showed conductive hearing loss of 42 dB HL in the right ear and a normal hearing level in the left ear. Anterior and posterior aspects of the body had various café-au-lait spots (Figure 6). A temporal bone CT showed the soft tissue mass located over the cortical bone of the mastoid region, partially obliterating the external ear canal (Figure 7). It appeared that the mass did not involve the mastoid segment of the facial nerve. Using a postauricular approach, the mass was excised in a piecemeal fashion without violating the skin of the ear canal. The mass was somewhat hemorrhagic and tended to intermingle the postauricular periosteum and the temporal muscle fibers (Figure 8). Upon excision of the mass, patency of the ear canal was obtained. The skin of the ear canal was laid back in its place, and the ear canal was filled with pieces of gel foam. The histopathological examination revealed that the plexiform neurofibroma consisted of a tortuous mass of expanded nerve branches, which are seen as



**Figure 9.** Plexiform neurofibroma with tortuous enlargement of the nerves (Case 2)



**Figure 10.** Neoplastic cells showing S-100 positivity (Case 2)

cuts in various planes of the section. In the immunohistochemical examination, the tumor cells show diffuse S-100 protein positivity (Figure 10). The postoperative period was uneventful. The average air conduction threshold was 10 dB HL postoperatively. There was no recurrence in the fourth year after surgery.

### Case 3

A 44-year-old female presented with a 7-year history of swelling and hearing loss in the left ear. In the otoscopic examination, a solid mass of approximately 2×1 cm was found, obliterating the left external auditory canal and cavum concha (Figure 10 ). The skin over the mass was somewhat bluish. The mass was tender upon palpation. The facial nerve function was normal, and there was no sensory deficit in the pinna skin. The patient had conductive hearing loss of 37 dB HL in the left ear and a normal hearing level in the right ear. The temporal bone CT showed a mass originating from the postauricular region superficial to the cortical bone and extending toward the condyle of the mandible. Magnetic resonance imaging (MRI) of the temporal bone showed a heterogeneous and intensively enhanced mass of 44×15×50 mm that partly obliterated the external ear canal and extended towards the mastoid region posteriorly, the mandibular condyle anteriorly, and the temporal muscle superiorly (Figure 11). The mass was hypointense in T1 MRI scans and hyperintense in T2 MRI scans. The patient had no café-au-lait spots on her body. A biopsy of the mass in the postauricular area was somewhat hemorrhagic and revealed microscopic features of a neurofibroma. The patient denied further surgery. One and half years later, the patient agreed to

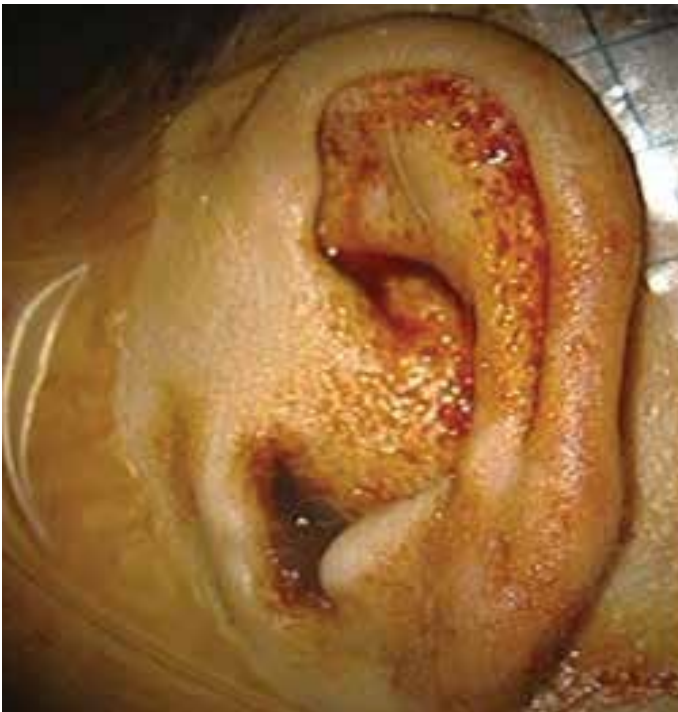

Figure 11. The partially obliterated external auditory canal (Case 3)

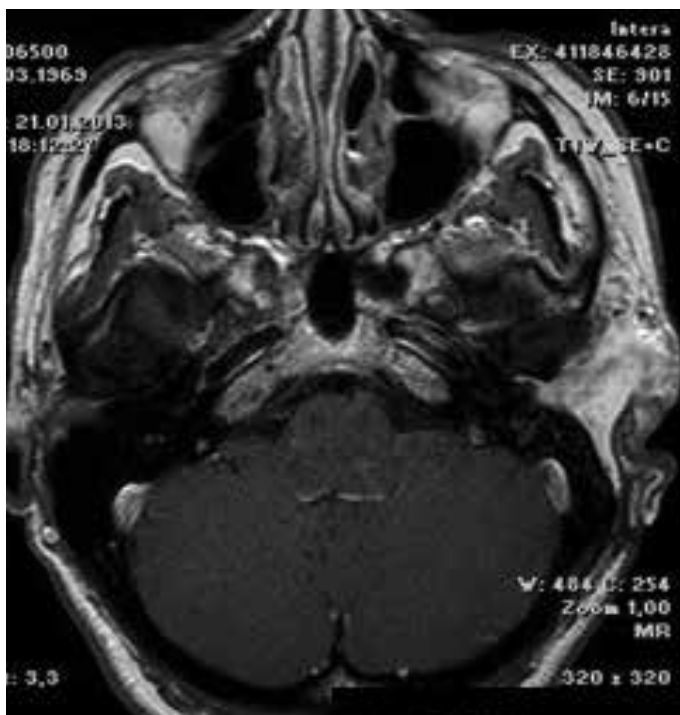

Figure 12. MRI T1 sequence with contrast showing enhancement of the tumor.

undergo the surgical procedure. After counseling the patient, repeated MRI, angiography, and embolization were performed. The MRI showed a slight increase in the dimensions of the tumor (50×32×55 mm). Next, a subtotal excision was planned to improve the conductive hearing loss, leaving the mass around the TMJ. Through the postauricular incision, the outline of the mass was brought into view. The mass was hemorrhagic and tended to intermingle subcutaneous soft tissue planes (Figure 12). During the dissection, the skin of the ear canal had to be violated in a very small area. After piecemeal ex-

cision, the skin was placed back into position, and the ear canal was filled with pieces of gel foam soaked with antibiotic ointment. The histopathological examination revealed characteristic features of a neurofibroma. The postoperative period was uneventful, and there was no recurrence in the external ear in the third year after surgery. There was also no growth of the tumor remnant around the TMJ. The average air conduction threshold was 10 dB HL.

## DISCUSSION

The pinna and external ear canal are innervated by the cranial nerves (CN) V, VII, IX, and X and the cervical nerves in a complex manner. Considerable variations make the innervation more complex. The great auricular nerve originating from the cervical plexus of the nerves (C2–C3) supplies sensory innervation to most of the lateral surface of the pinna, whereas the medial surface is innervated by the lesser occipital nerve of the plexus [7]. The auriculotemporal branch from the CN V crosses the medial and posterior surfaces to the TMJ, crosses the zygomatic arch, and innervates the superior and anterior parts of the pinna and external ear canal walls [7]. The auricular branch from the CN X participates in the innervation of the external ear canal along with branches of CN VII and IX.

Case 1 had facial nerve involvement that was noted during the routine parotidectomy. Based on the location of the neurofibroma in case 2, one might propose that the tumor arose from the pinna branches of the lesser occipital nerve or great auricular nerve. Considering the presence of multiple café-au-lait spots and plexiform neurofibroma in the patient, diagnosis of neurofibromatosis type-I (NF-I) was established. The interesting location of the tumor in case 3 implies that the tumor likely originated from the auriculotemporal nerve. We deliberately left some part of the tumor associated with the mandibular condyle untouched, considering the potential for a bad sequelae of a surgery around the TMJ. Removing the tumor component associated with the external ear canal provided complete relief in conductive hearing loss. Furthermore, the patient is still asymptomatic with the tumor remnant in the TMJ.

The neurofibroma may be sporadic or associated with the NF-I syndrome. It has been stated that those strongly NF-associated subtypes are multiple cutaneous subtype (NF-1 or -2), massive subtype (NF-1), and plexiform subtype (NF-1) [3]. Of those, plexiform neurofibromas tend to form poly-nodular lesions in the shape of skip lesions on the affected nerve. Cases 1 and 3 had localized subtypes of neurofibroma. There were no other stigmata of NF. Case 2 was associated with NF-I, and the neurofibroma was a plexiform variance. It seems that the status of the facial function depends on the involvement of the facial nerve segment with the neurofibroma. Dai et al. [8] reported that hearing loss, pulsatile tinnitus, and facial paralysis are common symptoms in intratemporal neurofibromas. Facial paralysis is generally not observed in an intraparotid neurofibroma, unlike with a facial nerve schwannoma [9]. In contrast, facial dysfunction may be seen in intratemporal facial neurofibromas [10]. Our case (Case 1) with facial nerve neurofibroma did not have these symptoms, with the exception of a palpable mass in the parotid region.

Diagnosis of an intraparotid and intratemporal facial neurofibroma, like other neurogenic tumors, is considerably difficult [9]. Incisional biopsy of the facial neurofibroma will probably fail to prove the correct diagnosis. Evaluating a mass associated with the parotid gland and



facial paralysis requires an MRI <sup>[10]</sup>. However, a diagnostic problem arises when a facial neurofibroma without facial palsy is located in the intraparotid region. These tumors are mostly diagnosed intraoperatively. Ultimately, excisional biopsy is the gold standard for neurofibromas <sup>[9, 10]</sup>. Dai et al. <sup>[8]</sup> reported that for 54% of the patients in their study, more than one segment of the facial nerve was affected. They performed a transmastoid approach in all cases and used sural or auricularis magnus nerve grafts in four of the cases <sup>[8]</sup>.

Recurrence of these tumors is found to be associated with some factors, such as subtotal resection, head, neck, and face locations, and age <sup>[3,9]</sup>. Woods et al. <sup>[10]</sup> proposed multifocality or a multinodular pattern as a factor for recurrence <sup>[4]</sup>. Therefore, the surgeon should ascertain that the nerve ends are tumor-free using an intraoperative frozen section. Neurofibromas are understood to undergo malignant transformation. However, its rate is not the same for all subtypes. Although the rate of malignant transformation for diffuse and massive subtypes is extremely low, it is higher for the localized intraneural subtype, which affects a large nerve, particularly the plexiform subtype in NF-1 patients. The localized cutaneous subtype does not undergo such degeneration <sup>[3]</sup>.

In conclusion, facial nerve neurofibromas are an uncommon entity, particularly in the intraparotid region. Three cases are presented herein, including the first reported case of both an intratemporal and intraparotid facial nerve malignant neurofibrosarcoma. Although facial nerve tumors are rarely seen, we should keep these tumors in mind in cases with a parotid mass. Conservative management, i.e., maintaining the nerve intact with functional activity, is recommended. Close monitoring, particularly in neurofibromas associated with Von Recklinghausen's disease, is mandatory because of the increased risk of sarcomatous transformation. Complete removal of these tumors can be challenging because of local invasion and the resultant recurrence risk. Because axons travel along the neurofibroma, the morbidity associated with resection of important structures, such as the facial nerve, is another complicated aspect of the surgical treatment. However, surgical management remains the mainstay of treatment for these locally invasive tumors.

## Summary

Neurofibromas may be sporadic or associated with the NF-I syndrome. It has been stated that the strongly NF-associated subtypes are the multiple cutaneous subtype (NF-1 or 2), massive subtype (NF-1), and plexiform subtype (NF-1).

Facial function depends on the involvement of the facial nerve segment with the neurofibroma. Facial paralysis is generally not observed in an intraparotid neurofibroma, unlike with a facial nerve schwannoma.

Diagnosis of an intraparotid and intratemporal facial neurofibroma, like other neurogenic tumors, is considerably difficult. These tumors are mostly diagnosed intraoperatively. Ultimately, excisional biopsy is the gold standard for neurofibromas.

Extratemporal involvement of the facial nerve is rarer. An extremely rare condition is both intra- and extratemporal involvement of the nerve by a neurofibroma.

Treatment of the neurofibroma originating from the facial nerve depends on the location of the tumor and the status of facial function. It is better to delay surgery to at least the time of House-Brackmann Grade 3 facial dysfunction.

**Ethics Committee Approval:** N/A.

**Informed Consent:** Written informed consent was obtained from patients who participated in this case series report.

**Peer-review:** Externally peer-reviewed.

**Author Contributions:** Concept - B.S., M.B.A.; Design - B.S., M.B.A.; Supervision - M.G., B.S.; Funding - B.S.; Materials - U.A., Y.H., M.B.A.; Data Collection and/or Processing - M.B.A., U.A., I.Y.; Analysis and/or Interpretation - B.S., M.B.A., I.Y.; Literature Review - B.S., M.B.A., I.Y.; Writer - B.S., M.B.A.; Critical Review - M.G., B.S.; Other - Y.H., M.G., I.Y.

**Acknowledgements:** Authors would like to thank Ömer Günhan for his help to provide pathological images.

**Conflict of Interest:** No conflict of interest was declared by the authors.

**Financial Disclosure:** The authors declared that this study has received no financial support.

## REFERENCES

1. Perry A, Roth KA, Banerjee R, Fuller CE, Gutmann DH. NF1 deletions in S-100 protein-positive and negative cells of sporadic and neurofibromatosis 1 (NF1)-associated plexiform neurofibromas and malignant peripheral nerve sheath tumors. *Am J Pathol* 2001; 159: 57-61. [\[CrossRef\]](#)
2. Carroll SL. Molecular mechanisms promoting the pathogenesis of Schwann cell neoplasms. *Acta Neuropathol* 2012; 123: 321-48. [\[CrossRef\]](#)
3. Woodruff JM. Pathology of tumors of the peripheral nerve sheath in type 1 neurofibromatosis. *Am J Med Genet A* 1999; 89: 23-30. [\[CrossRef\]](#)
4. Rodriguez FJ, Folpe AL, Giannini C, Perry A. Pathology of peripheral nerve sheath tumors: diagnostic overview and update on selected diagnostic problems. *Acta Neuropathol* 2012; 123: 295-319. [\[CrossRef\]](#)
5. McMonagle B, Fagan P. Intratemporal Facial Neurofibroma. *Otol Neurotol* 2002; 27: 1046-7.
6. Fadda MT, Verdino G, Mustazza MC, Bartoli D, Iannetti G. Intra-parotid facial nerve multipl plexiform neurofibroma in patient with NF1. *Int J Pediatr Otorhinolaryngol* 2008; 72: 553-7. [\[CrossRef\]](#)
7. Goycoolea MV, Paparella MM, Nissen RL. Atlas of otologic surgery. Philadelphia: Saunders; 1989. xviii, 369 p.
8. Dai C L, Li J, Guo L, Song Z. Surgical experience of intratemporal facial nerve neurofibromas. *Acta Otolaryngol* 2013; 133: 893-6. [\[CrossRef\]](#)
9. McGuirt WF Sr, Johnson PE, McGuirt WT. Intraparotid Facial Nerve Neurofibromas. *Laryngoscope* 2003; 113: 82-4. [\[CrossRef\]](#)
10. Woods O, Giguère C, Saliba I. Intraparotid Neurofibroma: Review of the Literature. *J Otolaryngol Head Neck Surg* 2011; 40: 104-12.