



## Case Report

# An Unusual Presentation of Gout: Tophi in the Middle Ear

**Ahmet Mutlu, Emine Dündar, Mete İşeri, Cengiz Erçin, Ayşe Cefle**

Department of Otorhinolaryngology, Kocaeli University School of Medicine, Kocaeli, Turkey (AM, MI)

Department of Internal Medicine, Kocaeli University School of Medicine, Kocaeli, Turkey (ED)

Department of Pathology, Kocaeli University School of Medicine, Kocaeli, Turkey (CE)

Department of Internal Medicine and Rheumatology, Kocaeli University School of Medicine, Kocaeli, Turkey (AC)

Gout is a common metabolic disease and is characterized by episodic acute and chronic arthritis caused by the deposition of monosodium urate (MSU) crystals in joints and connective tissues. The most commonly involved joint is the first metatarsophalangeal joint. It may also present with nonspecific complaints caused by gouty tophi in unusual sites of the body such as the spine, bone, and middle ear. Such involvements can be disabling and impair the quality of life. In this report, we describe the case of a patient who had complaints of hearing loss and otorrhea. A 34 year-old male patient presented with complaints of recurrent otorrhea and hearing loss for several months. He had no history of joint pain or constitutional symptoms at the time of admission. An otoscopic examination of the left ear revealed subtotal tympanic membrane perforation, and white middle ear plaques were detected. The patient underwent intact canal mastoidectomy under general anesthesia, and middle ear sclerosis was determined as Wieling Kerr classification type 2. Postoperative histopathologic examination of the specimen revealed amorphous eosinophilic deposits within fibrous stroma and tophi containing negatively birefringent MSU crystals by polarized light. After the histopathologic diagnosis of gout, the patient was assessed for peripheral joint involvement. He had no radiographic abnormalities. The patient was administered a serum urate-lowering therapy, given a low purine diet, and followed with the diagnosis of tophaceous gout. Unusual localizations of gouty tophi have been reported in the literature. Gouty tophi should also be considered in the differential diagnosis of middle ear masses alongside common pathologies.

**KEYWORDS:** Gout, gouty tophus, hearing loss, uric acid, tympanosclerosis

## INTRODUCTION

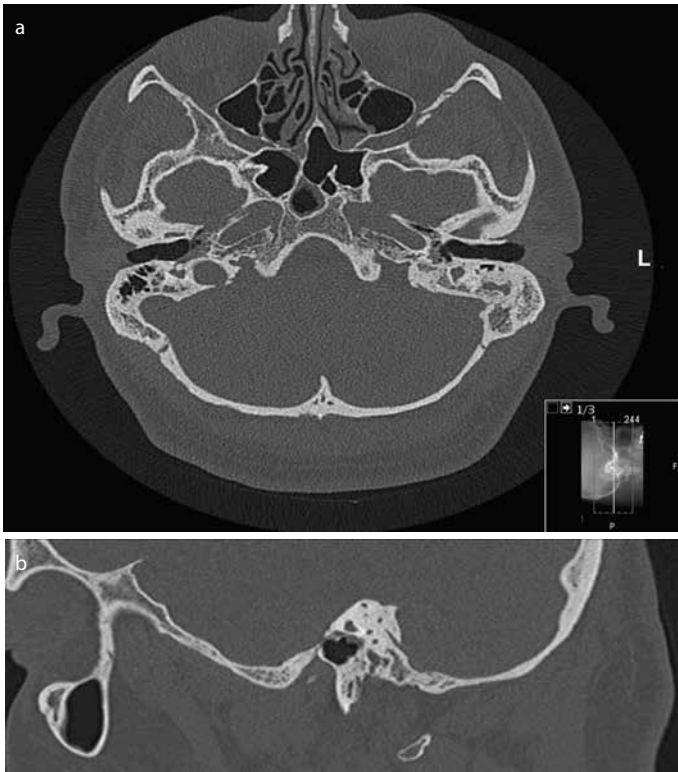Gout is a common metabolic disease. It is characterized by episodic acute and chronic arthritis caused by the deposition of monosodium urate (MSU) crystals in joints and connective tissues. It affects 1–2% of adults in developed countries, generally middle-aged to elderly men and post-menopausal women<sup>[1]</sup>. Its incidence in the general population ranges from 0.06 to 2.68 per 1,000 person-years<sup>[2]</sup>. The most commonly involved joint is the first metatarsophalangeal joint. Other frequently affected joints include the tarsal joints, ankle, knee, wrists, and finger joints<sup>[3]</sup>. The first episode of acute gouty arthritis generally begins with joint pain and swelling. It may also present with nonspecific complaints caused by gouty tophi in unusual sites of the body such as the spine, bone, and middle ear<sup>[4-9]</sup>. Such involvement can be disabling and can impair the quality of life. Only three cases of tophaceous gout of the middle ear have been reported to date<sup>[4-6]</sup>.

In this report, we describe the case of patient who had complaints of hearing loss and otorrhea. The patient underwent intact canal mastoidectomy with ossiculoplasty, and a post-operative histopathological examination demonstrated gouty tophi.

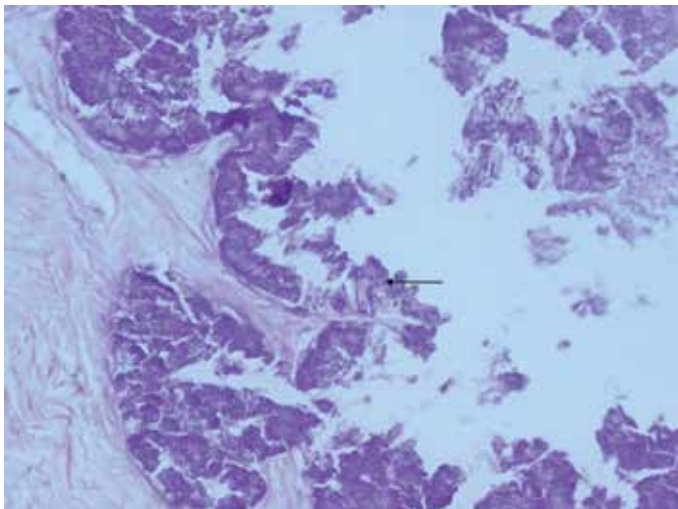
## CASE PRESENTATION

A 34-year-old male patient presented with complaints of recurrent otorrhea and hearing loss for several months. He had no history of joint pain or constitutional symptoms at the time of admission. An otoscopic examination of the left ear revealed subtotal tympanic membrane perforation, and white middle ear plaques were detected. The ear canal was intact, and the pinna was unremarkable. The patient's white blood cell count was 4,790/mm<sup>3</sup>, the erythrocyte sedimentation rate was 2 mm/h, C-reactive protein level was 0.13 mg/dL, and serum glucose level was 89 mg/dL. The serum uric acid level slightly increased and was 8.7 mg/dL (Normal rates: 2.5–7.7 mg/dL). The patient's urinary urate excretion rate was 540 mg/day, and it was within the normal range (N: 250–750 mg/day). The patient did not have joint pain, swelling, or erythema. He also did not have a family history of gouty arthritis. He was assessed as having chronic otitis media with tympanosclerosis according to his otoscopic and audiologic examination results. Mild conductive hearing loss was detected on pure tone audiometry (Left: 49 dB HL, Right: 20 dB HL). Temporal bone computerized tomography findings displayed an increase in soft tissue in the middle ear and non-specific mastoiditis (Figure 1). The patient un-

**Corresponding Address:** Ahmet Mutlu E-mail: ahmutlu1988@gmail.com**Submitted:** 07.07.2015**Revision received:** 28.09.2015**Accepted:** 18.01.2016**Available Online Date:** 03.08.2016

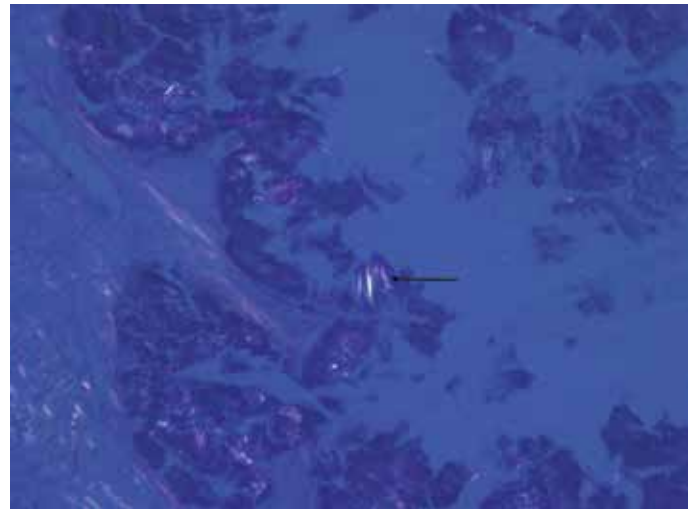

**Figure 1. a, b.** Temporal bone computerized tomography. Soft tissue density of the left middle ear and non-specific mastoiditis. Axial cross-section image (a), sagittal cross-section image (b)



**Figure 2.** Amorphous eosinophilic MSU deposits within fibrinoid stroma. Hematoxylin Eosin staining ×400 (black arrow)

derwent intact canal mastoidectomy under general anesthesia, and middle ear sclerosis was determined as Wieling Kerr classification type 2. White tympanosclerotic plaques were cleared from the incus and stapes, and hearing reconstruction was performed with a titanium partial ossicular reconstruction prosthesis (KURZ®; Dusslingen, Germany). A postoperative histopathologic examination of the specimen (Figure 2, 3) revealed amorphous eosinophilic deposits within the fibrous stroma and tophi containing negatively birefringent MSU crystals by polarized light (Figure 2, 3). After the histopathologic diagnosis of gout, the patient was assessed for peripheral joint involvement. He had no radiographic abnormalities such as erosions, cystic



**Figure 3.** Negatively birefringent MSU crystals by polarized light microscopy. HE staining ×400 (black arrow)

changes, or lytic areas with overhanging edges. As the patient did not have any symptoms, magnetic resonance imaging, which is capable of detecting crystal deposits, was not performed as part of the routine evaluation. The patient was administered a serum urate-lowering therapy, given a low purine diet, and followed with the diagnosis of tophaceous gout. Postoperative 12<sup>th</sup> month pure tone audiometric test levels showed an air–bone gap gain of 26 dB on the left ear with 23 dB HL. This report has been written after obtaining the patient's informed consent.

## DISCUSSION

Gout is a common inflammatory arthritis caused by the deposition of MSU crystals. Its prevalence and incidence has increased in recent decades [3]. This increase can be attributed to aging, hypertension, obesity, metabolic syndrome, alcoholism, increased intake of proteins, and a fructose-enriched diet [10]. Impaired renal function and reduced efficiency of renal urate clearance also contributes to hyperuricemia and gout progression. Gout is a chronic disease and may progress to tophaceous gout without effective treatment. The objective of long-term therapy is to reduce serum uric acid levels and prevent tophi formation, which can be disabling.

Unusual localizations of gout tophi have been reported in the literature. These cases include tophi in the spinal cord causing compressive symptoms [8]. There are only three cases of tophaceous gout in the middle ear in the literature [4, 5]. Reineke et al. [5] presented a case with a middle ear mass diagnosed as a gout tophus. Mass resection was adequate to restore hearing. A definitive diagnosis of unusually located gouty tophi requires a histopathological examination. Gouty tophi are characterized by foreign body granulomas comprising mono- and multinucleated macrophages surrounding the deposits of MSU crystals [7]. The presence of calcium pyrophosphate crystals as a result of pseudogout must be considered, and polarized light microscopy helps differentiate the pathologies. MSU crystals show negative birefringent with yellow color, and calcium pyrophosphate crystals are in blue with a weak positive birefringence.

In the current patient case, we observed erosion of the long process of the incus and impairment of the incudostapedial joint. Tophi were

resected from the middle ear cavity; thus, we preferred a titanium partial ossicular reconstruction prosthesis to fix the ossicular chain. Temporal muscle fascia and conchal cartilage were used to maintain the intact tympanic membrane graft. We were able to obtain a 26 dB air-bone gap gain and partially recover the conductive hearing loss in 6 months. The pathological diagnosis of the lesion needed a multi-systemic investment for gout. Because of the high serum uric acid levels, urate-lowering therapy (allopurinol 300 mg/day oral) was begun to prevent new tophi formation on the middle ear.

Gouty tophi should also be considered in the differential diagnosis of middle ear masses alongside common pathologies.

**Ethics Committee Approval:** N/A.

**Informed Consent:** Written informed consent was obtained from patient who participated in this study.

**Peer-review:** Externally peer-reviewed.

**Author Contributions:** Concept - A.M., E.D.; Design - A.M., E.D.; Supervision - M.I., A.C.; Funding - M.I., A.C.; Materials - C.E., A.M.; Data Collection and/or Processing - A.M., E.D.; Analysis and/or Interpretation - M.I., A.C.; Literature Review - A.M., C.E.; Writer - A.M., E.D.; Critical Review - M.I., C.E.; Other - C.E., A.C.

**Acknowledgements:** Authors would like to thank patient for giving the permission to use the data.

**Conflict of Interest:** No conflict of interest was declared by the authors.

**Financial Disclosure:** The authors declared that this study has received no financial support.

## REFERENCES

1. Richette P, Bardin T. Gout. *Lancet* 2010; 375: 318-28. [\[CrossRef\]](#)
2. Wijnands JM, Viechtbauer W, Thevissen K, Arts IC, Dagnelie PC, Stehouwer CD, et al. Determinants of the prevalence of gout in the general population: a systematic review and meta-regression. *Eur J Epidemiol* 2015; 30: 19-33. [\[CrossRef\]](#)
3. Doherty M. New insights into the epidemiology of gout. *Rheumatology (Oxford)* 2009; 48(Suppl 2): ii2-8. [\[CrossRef\]](#)
4. Tausch-Tremi R, Berghaus A. Gout tophus of the middle ear. *HNO* 1990; 38: 465-7.
5. Reineke U, Ebmeyer J, Schutte F, Upile T, Sudhoff HH. Tophaceous gout of the middle ear. *Otol Neurotol* 2009; 30: 127-8. [\[CrossRef\]](#)
6. Faas I. A gouty tophus in the temporomandibular joint and on the Eustachian tube. *Laryngol Rhinol Otol (Stuttg)* 1983; 62: 574-7. [\[CrossRef\]](#)
7. Nguyen C, Ea HK, Palazzo E, Lioté F. Tophaceous gout: an unusual cause of multiple fractures. *Scand J Rheumatol* 2010; 39: 93-6. [\[CrossRef\]](#)
8. Yoon JW, Park KB, Park H, Kang DH, Lee CH, Hwang SH, et al. Tophaceous gout of the spine causing neural compression. *Korean J Spine* 2013; 10: 185-8. [\[CrossRef\]](#)
9. Barksfield R, Gallagher K, Pasapula C. Silent gout: an unusual presentation in diabetic neuropathy. *Foot (Edinb)* 2012; 22: 264-6. [\[CrossRef\]](#)
10. Roddy E, Zhang W, Doherty M. The changing epidemiology of gout. *Nat Clin Pract Rheumatol* 2007; 3: 443-9. [\[CrossRef\]](#)