

---

ORIGINAL ARTICLE

---

**Simultaneous contralateral vestibular schwannoma and glomus jugulare**

**Kürşat Ceylan, MD., Hatice Emir, MD., İlhan Ünlü, MD., Ünal Bayız, MD.**

---

ENT Department, Ministry of  
Health Ankara Training and  
Research Hospital, Ankara, Turkey

Correspondence

Kursat Ceylan  
4. Sok. 22/27 Sogutozu 06520  
Ankara TURKEY

GSM: +905323354797  
Email: ceylankursat@ttnet.net.tr

*Submitted:* 06 December 2006

*Revised:* 19 February 2007

*Accepted:* 20 February 2007

Mediterr J Otol 2007; 3: 95-98

Copyright 2005 © The Mediterranean  
Society of Otolaryngology and Audiology

Only one case of simultaneous contralateral vestibular schwannoma and glomus jugulare has been reported in the literature. We report on a second case observed in a 63-year-old woman with serviceable hearing only on the same side as the schwannoma. She was treated with radiotherapy after embolization for the glomus jugulare and stereotactic surgery with gamma knife for the schwannoma side. Our case was very challenging as 2 important pathologies existed on either side, both carrying a risk of deafness as a consequence of the disease and/or the possible treatments.

Glomus jugulare tumors are benign neoplasms that arise from the adventitia of the jugular bulb and typically follow the Jacobson and Arnold nerves within the tympanic cleft. Despite their being the most common neoplasms of the middle ear and the second most common tumor involving the temporal bone after vestibular schwannomas, glomus tumors remain a rare clinical entity. They account for 0.03% of all neoplasms and 0.6% of all head and neck tumors. The annual incidence is 1 in 1.3 million. The mean patient age at presentation is 55 years. Traditionally, the management of glomus tumors has involved radiation therapy or resection often preceded by preoperative embolization<sup>[1]</sup>. Vestibular schwannomas arise from Schwann cells on branches of the vestibulocochlear nerve. The annual incidence is 1 per 100,000 population<sup>[2]</sup>. Surgery is the treatment of choice for glomus jugulare tumors, and glomus tumors carry an overall 10% malignancy potential. If surgical intervention is considered too risky, conventional radiotherapy or stereotactic radiosurgery may be considered as alternate treatment options. Larger tumors may need lateral skull base or infratemporal fossa approaches that are associated with significant complications such as cerebrospinal fluid

leak, meningitis, death, stroke, hearing loss, and multiple lower cranial nerve palsies.

To the best of our knowledge, only 4 cases of a simultaneous vestibular schwannoma and a glomus jugulare tumor have been previously reported in the literature. In the first 3 cases, the lesions were located on the same side, but in the fourth they were located contralaterally (Table). In this article, we report a new case of simultaneous contralateral vestibular schwannoma and glomus jugulare tumor.

### CASE REPORT

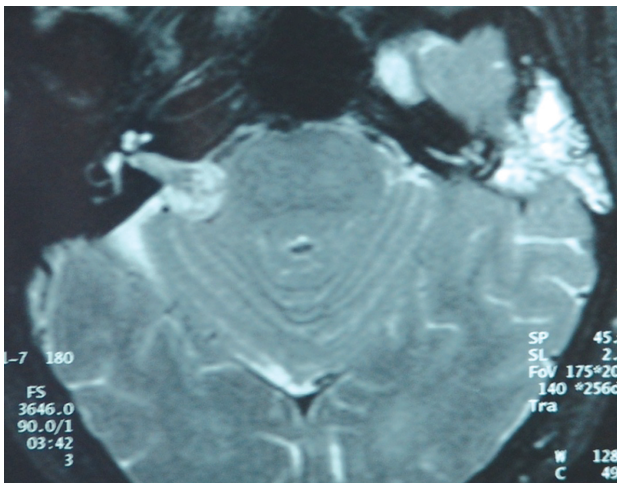
A 63-year-old woman presented with a 4-year history of bilateral hearing loss and a 2-year history of left-sided pulsatile tinnitus. Other symptoms included unsteadiness and left-sided headache. Otoscopy revealed a red pulsatile mass behind the left tympanic membrane. Neurologic examination demonstrated normal cranial nerves and cerebellar function. The results of Romberg's test were negative and the findings on Unterberger's stepping test were normal, but the patient was unsteady on tandem gait with her eyes open.

**Table. Characteristics of the 5 reported cases of simultaneous vestibular schwannoma and glomus tumor**

Author	Age/sex	Schwannoma		Glomus tumor		Management
		Side	Size	Side	Size	
Weber et al [3], 1992	65/F	Left	20 mm	Left	Fisch type A	Surgery
Falcioni et al [4], 1998	72/F	Left	5 mm	Left	Fisch type A	Conservative
Schallawitz et al [5], 2001	79/F	Right	12 mm	Right	Fisch type C	Radiotherapy
Moumoulidis et al [6], 2005	66/F	Right	15 mm	Left	Fisch type D	Schwannoma: observation; glomus tumor: embolization, radiotherapy
Ceylan et al*, 2006	66/F	Right	22 mm	Left	Fisch type D	Schwannoma: gamma knife; glomus tumor: embolization, radiotherapy

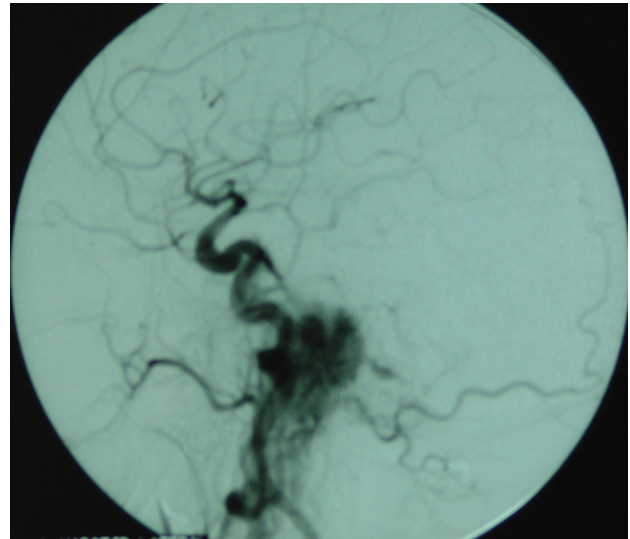
\* Present case

Pure-tone audiometry revealed a sensorineural hearing loss in the right ear and mixed hearing loss in the left ear, with air-conduction thresholds averaging 44 dB on the right and 82 dB on the left. Speech audiometry showed a maximum discrimination score of 50% at 80 dB in the right ear and 0% at 80 dB on the left (representing non-serviceable hearing). Magnetic resonance imaging (MRI) detected a 22-mm (maximum mediolateral diameter) vestibular schwannoma on the right and a Fisch type C2De1 glomus jugulare tumor on the left (Figure 1). Carotid angiography demonstrated the characteristics of a typical large glomus tumor that was supplied primarily by branches of the external carotid artery (Figure 2).



**Figure-1:** Axial MRI shows right-sided vestibular schwannoma and left-sided glomus jugulare tumor.

Surgery was planned after embolization for the glomus tumor side, but the patient and her family changed their minds after the embolization had been done. They preferred a less risky treatment modality. Consequently the glomus tumor was treated with embolization followed by radiotherapy; the schwannoma was treated with gamma knife stereotactic radiosurgery. The patient was assessed annually with neuro-otologic examinations and MRIs. She remained stable and exhibited no evidence of any change in schwannoma size or in hearing thresholds and speech discrimination with her hearing ear as after 3 years of posttreatment follow-up. The patient is still using an air conduction hearing aid.



**Figure-2:** The glomus jugulare tumor is seen on carotid angiography.

## DISCUSSION

In previously reported cases of simultaneous vestibular schwannoma and glomus jugulare tumor, which occurred in women aged 65 to 79 years, the first 3 patients presented with symptoms in 1 ear only<sup>[3-5]</sup>. A vestibular schwannoma was diagnosed incidentally on the radiologic investigation for a glomus jugulare tumor in 2 patients<sup>[4-5]</sup>, and a glomus jugulare tumor was diagnosed incidentally during surgery for a vestibular schwannoma in 1 patient<sup>[3]</sup>. In contrast, the fourth patient<sup>[6]</sup> and ours presented with symptoms in both ears, and vestibular schwannoma and glomus jugulare tumor were diagnosed simultaneously on the radiologic investigation.

Management options for both vestibular schwannomas and glomus jugulare tumors include observation, surgery and radiotherapy.<sup>[7]</sup> The first 3 patients were managed differently: with surgery,<sup>[3]</sup> observation,<sup>[4]</sup> and radiotherapy.<sup>[5]</sup> In each case, management was straightforward because the 2 tumors were ipsilateral.

In the fourth patient, the lesions were contralateral, with a 15-mm vestibular schwannoma in a right ear with no useful hearing and Fisch type D glomus jugulare tumor in a left ear with some hearing. In contrast, our

patient has serviceable hearing on the right side where there was a 22-mm vestibular schwannoma and no useful hearing on the left side with Fisch type D glomus jugulare tumor. The priority in both patients was to manage the disease in both ears while preserving the hearing. In the fourth patient, the glomus jugulare on the left clearly required treatment because of its size, whereas a watch, wait, and rescan plan was adopted for the vestibular schwannoma.

Embolization is generally used as a preoperative intervention to decrease blood loss and to facilitate surgery, although some reports not favoring embolization exist. Radiotherapy alone can be considered for elderly patients, for those who have high surgical risk because of large tumor size, and for those who refuse surgery. Embolization with radiation therapy requires good oxygenation for better results. Embolization decreases tumor oxygenation and therefore, may decrease the efficacy of radiotherapy. Our patient was unique because of applied treatment modalities for both sides. The schwannoma in our patient was relatively large but sited on the only hearing side. The patient and her family refused surgery after embolization had been performed. We decided that embolization followed by radiotherapy for the glomus jugulare and gamma knife therapy for the schwannoma was preferable. This treatment pairing would likely control the disease without major surgery but would not put the available hearing at much risk.

Our patient is currently using an air conductive-type hearing aid. Radiotherapy is not without risk for hearing. Her right-side hearing will deteriorate over time with or without radiotherapy and she will eventually be deaf in both ears. We are considering a brainstem implant when the patient loses her serviceable hearing.

---

## REFERENCES

---

1. Moffat DA, Hardy DG. Surgical management of large glomus jugulare tumours: infra- and trans-temporal approach. *J Laryngol Otol* 1989;103:1167-1180.
2. Tos M, Thomsen J. Epidemiology of acoustic neuromas. *J Laryngol Otol* 1984;98:685-692.
3. Weber R, Draf W, Bachor E. Simultaneous occurrence of an acoustic neurinoma and a glomus tympanicum tumor in a patient: an unusual constellation an problematic surgical task [German]. *HNO* 1992;40:410-413.
4. Falcioni M, Caruso A, Sanna M. Coexistence of vestibular schwannoma and glomus tympanicum tumor [Italian]. *Acta Otorhinolaryngol Ital* 1998;18:398-401.
5. Schallawitz T, Strauss G, Bootz F. Pulsating space-occupying lesion of the right tympanum after radical operation: glomus jugulare tumor and acoustic neuroma right [Italian]. *HNO* 2001;49:226-227.
6. Moumoulidis I, Brevis C, Moffat DA. Simultaneous contralateral vestibular schwannoma and glomus jugulare tumor: a case report. *Ear Nose Throat J* 2005;84(5) 290-293.
7. Sheehan J, Kondziolka D, Flickinger J, Lunsford LD. Gamma knife surgery for glomus jugulare tumors: an intermediate report on the efficacy and safety. *J Neurosurg* 2005;102:241-246.