



Original Article

# An Implantable Hearing System As Rehabilitation for Hearing Loss Due to Bilateral Aural Atresia: Surgical Technique and Audiological Results

Rubens de Brito, Luzia Maria Pozzobom Ventura, José Carlos Jorge, Eduardo Boaventura Oliveira, Luiz Fernando Manzoni Lourencone

Department of Otolaryngology, Hospital De Reabilitacao De Anomalias Craniofaciais (HRAC), Universidade De Sao Paulo, Bauru, Brazil

**OBJECTIVE:** To demonstrate the surgical technique and audiological results of a middle ear implant for restoring hearing in patients with bilateral aural atresia and microtia with conductive or mixed hearing loss.

**MATERIALS and METHODS:** In this prospective study, 12 subjects aged 12 years and older presenting with hearing loss and bilateral congenital aural atresia underwent surgical insertion of a middle ear implant. The patients underwent tympanomastoidectomy with a wide opening of the attic and preservation of the roof of the atresic tympanic bone to expose the middle ear and position the floating mass transducer of the implant.

**RESULTS:** There were no intraoperative or postoperative complications. The hearing threshold averages in a free field were 53.5 dB preoperatively and 25.6 dB postoperatively. Monosyllabic word recognition averaged 61% preoperatively and 91.3% postoperatively. The average speech perception in quiet conditions during the hearing in noise test improved from 67.11 dB to 45.99 dB, and the signal-to-noise ratio improved from 5.64 to 1.31.

**CONCLUSION:** The tested system is an excellent option for auditory rehabilitation of conductive hearing loss due to bilateral ear atresia. The surgery is well structured and safe and provides several alternatives to the surgeon, which is valuable in difficult cases.

**KEYWORDS:** Vibrant soundbridge, conductive hearing loss, aural atresia, active middle ear implant

## INTRODUCTION

Bilateral aural atresia with microtia is a condition that leads to severe conductive hearing loss. Rehabilitation is usually performed with a bone-anchored hearing aid. However, there are skin complications related to percutaneous devices, and some patients who cannot or do not want to use percutaneous devices for dermatologic or esthetic reasons may have the option of an active middle ear prosthesis<sup>[1]</sup>. Bone conduction implant surgery can also result in complications related to osteointegration, and rarely, major complications are associated with drilling a small hole toward the dura<sup>[2]</sup>.

A middle ear implant (MEI) is indicated and approved for individuals presenting with sensorineural, conductive, or mixed hearing loss who are not sufficiently benefitted from conventional acoustic hearing aids or cannot wear them for any reason<sup>[3,4]</sup>. The internal unit of the MEI is surgically implanted and comprises an implanted device (receiver and magnet), a conductor link, and a floating mass transducer (FMT). The versatility of the FMT allows it to be fixed in different places in the middle ear, such as the long process of the incus, stapes, and round window<sup>[5-7]</sup>.

The use of an active middle ear implant is an option for hearing restoration in aural atresia with microtia; however, there are few descriptions of successful procedures in the literature<sup>[8-11]</sup>. In addition, the surgical technique has not been standardized regarding not only the positioning of the active part in the middle ear but also the mastoid or middle-ear approach for any of the available implantable devices. In this study, we aimed to demonstrate the MEI as a viable option for patients suffering from bilateral aural atresia and microtia with conductive or mixed hearing loss. A standardized surgical approach for these cases is also described in detail.

## MATERIALS and METHODS

### Subject Selection Criteria

Patients (adults and children older than 12 years) with bilateral aural atresia presenting with conductive or mixed hearing loss and meeting the inclusion criteria were selected. Informed consent was obtained for all patients. The study was approved by the ethics committee of our institution and conducted in accordance with the ethical principles stated in the Declaration of Helsinki. Written

informed consent was obtained from patients or patients' parents who participated in this study. The Ethics Committee approved the study, which was conducted in accordance with the Helsinki Declaration.

All patients underwent hearing evaluation and a computed tomography study of the temporal bones 1 month before surgery.

The inclusion and exclusion criteria were as follows:

#### Inclusion Criteria

- Bilateral ear atresia or microtia with a Jahrsdoerfer score greater than 5 [12].
- Bilateral stable conductive or mixed hearing loss without bone conduction fluctuation over 15 dB HL in either direction during the past 2 years.
- Experience with conventional bone conduction hearing aids and inability to wear them or no benefit from wearing them for at least 3 months.

#### Exclusion Criteria

- Patients with retrocochlear or central auditory disorders.
- Presence of chronic otitis media.

#### Audiological Testing

The audiological tests listed below were performed in the pre- and postoperative periods to compare the results with and without the speech processor and to evaluate whether use of the MEI improved speech performance. The paired *t* tests were conducted using R 2.12.2 (2011) software, (R Foundation for Statistical Computing, Vienna, Austria). The data were described as mean  $\pm$  standard deviation. *P* values less than 0.05 were considered to be statistically significant.

#### Functional Gain

Aided and unaided free-field warble tone audiometry was performed in a soundproofed booth with a loudspeaker positioned at 0° azimuth and at a distance of 1 m from the subject to obtain the mean thresholds for frequencies of 0.5, 1, 2, and 3 kHz, according to the guidelines of the Committee on Hearing and Equilibrium [13].

#### Speech Testing

Speech recognition scores were measured as percent correct recognition of monosyllables in consonant-vowel-consonant form, presented at 65 dB of sound pressure level (SPL) from a loudspeaker positioned at 0° azimuth and at a distance of 1 m from the subject in a soundproofed booth.

The speech reception threshold was measured by application of the hearing in noise test (HINT) [14] in a sound-treated room. In quiet conditions, a signal with an initial intensity of 65 dB SPL was presented at 0° azimuth to the subject. The threshold at which the subject understood 50% of the presented speech was recorded. In noise conditions, the noise was presented at 90° azimuth ipsilateral to the ear selected for implantation in the preoperative period or to the aided ear in the postoperative period. The noise level was fixed at 65 dB SPL, and the signal presentation level was adapted until the patient understood 50% of the speech. The result was expressed as the signal-to-noise ratio (SNR) threshold in dB.

#### Surgical Procedure

A retroauricular incision was made 6 cm from the temporomandibular joint to allow future aesthetic procedures. A wide mastoidectomy was performed, preserving the cortical of the atresic tympanic bone as a shell to cover and protect the middle-ear space and the FMT of the Vibrant Soundbridge system (VSB), (Med-El, Innsbruck, Austria). The atresic tympanic bone was drilled until the stapes, incus-stapes joint, and oval window were totally exposed. The malleus-incus block was removed only if it was fixed or had malformed anatomy that could impede clipping of the FMT on the incus. When the malleus and incus were removed, the FMT was positioned on the stapes using a titanium coupler. If the stapes was overly malformed or was absent, the FMT was placed over the round or oval window. The FMT could also be positioned on the incus if it was not fixed or malformed. The long process of the incus is the classic location to clip the FMT and is normally used. Patients returned for activation six weeks after surgery.

#### RESULTS

Twelve patients underwent surgery for VSB implantation, and all the patients used the device daily 6 months after activation. Their ages ranged from 14 to 26 years, with a mean of 20 years at the time of surgery. The patient data, operated sides, Jahrsdoerfer scores, and FMT positions are described in Table 1.

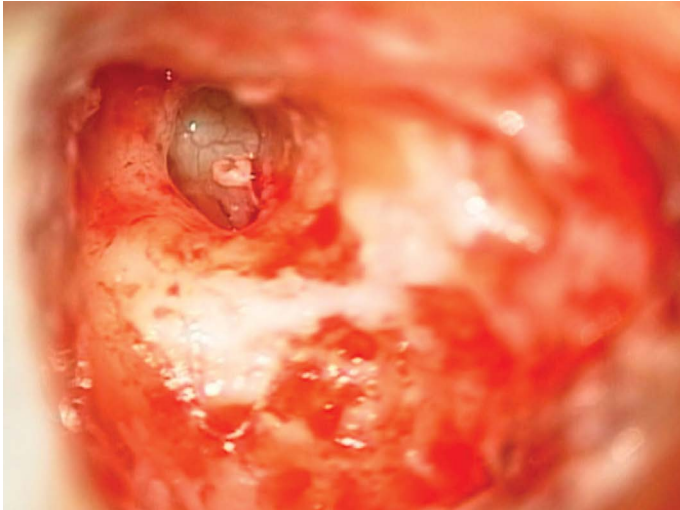
There were no intraoperative or postoperative complications. The modified mastoidectomy was adequate for exposing the middle ear and fixing the FMT in all cases (Figure 1). Figure 2 shows the FMT positions chosen during surgery. The FMT was fixed on the stapes and attached to titanium couplers in eight cases. The long process of the incus was used in two cases and the short process was used in one case. Also, in only one case, we placed the FMT in the oval window.

Free-field hearing thresholds for each patient are given in Figure 3 for frequencies of 0.5, 1, 2, and 3 kHz, with a preoperative average of 53.5 dB (standard deviation [SD]: 7.4) and a postoperative average of 25.6 dB (SD, 7). The average monosyllabic word recognitions were 61% (SD, 36.8) before surgery and 91.3% (SD, 91.3) postoperatively. The

Table 1. Patient data

Patient	Age	Sex	Hearing loss	Implanted ear	Jahrsdoerfer score	Floating mass transducer position
1	22	M	Conductive	Left	9	Stapes
2	16	F	Conductive	Right	7	Incus, short process
3	19	M	Conductive	Left	9	Stapes
4	25	M	Conductive	Right	8	Stapes
5	17	F	Conductive	Left	8	Stapes
6	22	F	Conductive	Left	8	Stapes
7	20	F	Conductive	Right	9	Incus, long process
8	24	M	Mixed	Left	6	Oval window
9	26	M	Conductive	Left	8	Stapes
10	20	M	Conductive	Right	9	Incus, long process
11	16	M	Conductive	Right	8	Stapes
12	15	M	Conductive	Right	8	Stapes

M: male; F: female



**Figure 1.** Example of middle ear exposure with space enabling floating mass transducer placement.

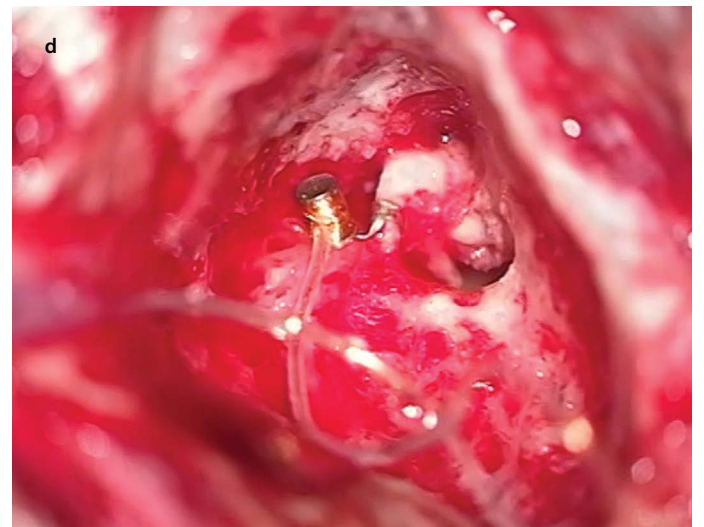
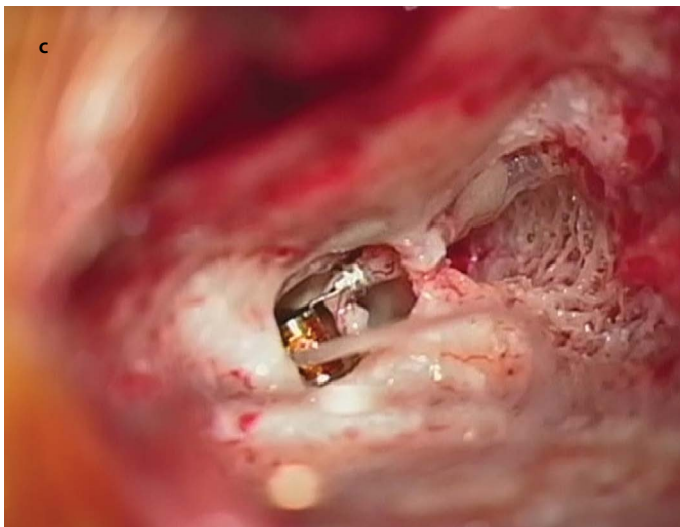
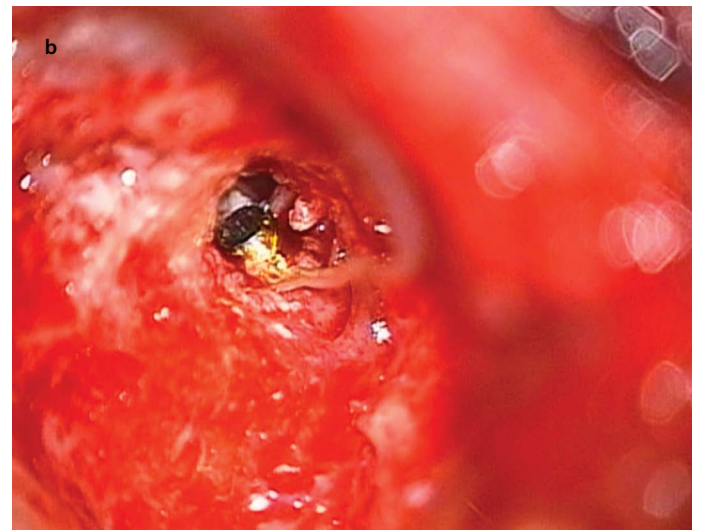
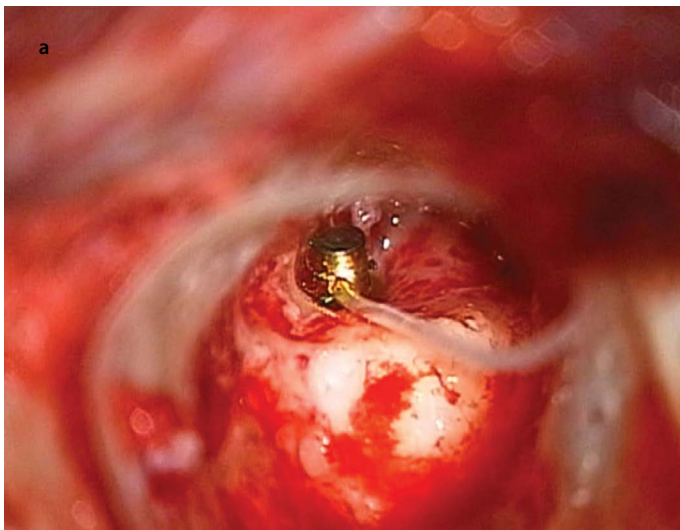
average speech perception in quiet conditions in the HINT improved from 67.11 dB (SD, 8.56) to 45.99 dB (SD, 7.76) after surgery, and SNR improved from 5.64 (SD, 4.33) to 1.31 (SD, 3.89); the details of these results are presented in Figures 4, 5.

## DISCUSSION

Bilateral congenital atresia of the external auditory canal is challenging for auditory rehabilitation because hearing aids cannot be appropriately adapted; also, continuous pressure from the use of bone conduction hearing aids is associated with chronic headaches, skin problems, and sinking of the mastoid bone in the pressed region. This causes patients to abandon use of the device at adolescence [15, 16].

Reconstruction (canaloplasty) of external ear atresia was formerly the standard surgery for aural atresia; however, the surgery is difficult and often offers poor audiological results. Although it remains an option in specific cases when the anatomy is favorable, we believe that this surgery should be avoided [17, 18].

Bone conduction implants have been the standard option for unilateral or bilateral congenital atresia for many years. The surgery is easily



**Figure 2 a-d.** Floating mass transducer placement. (a) Stapes; (b) oval window; (c) incus, long process; (d) incus, short process.



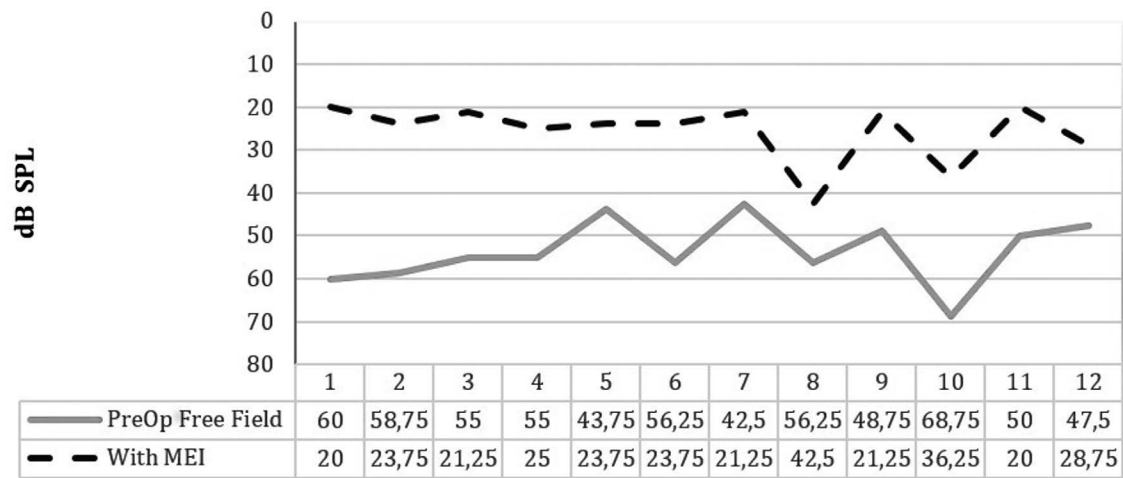


Figure 3. Comparison of preoperative and postoperative free-field hearing thresholds ( $p<0.001$ ). MEI, middle ear implant.

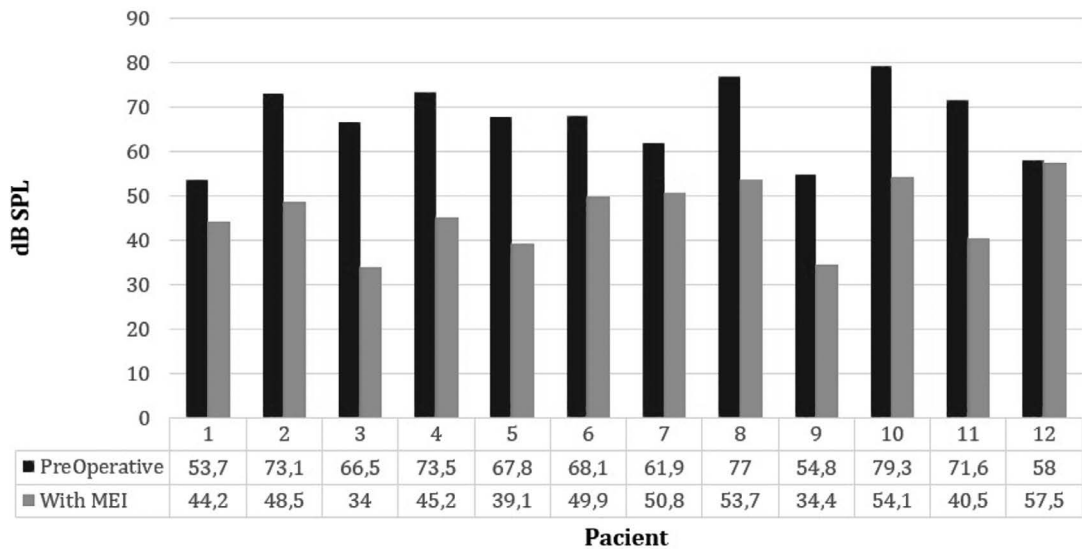


Figure 4. Comparison between preoperative and postoperative speech perception in quiet conditions in the hearing in noise test ( $p<0.001$ ). MEI, middle ear implant.

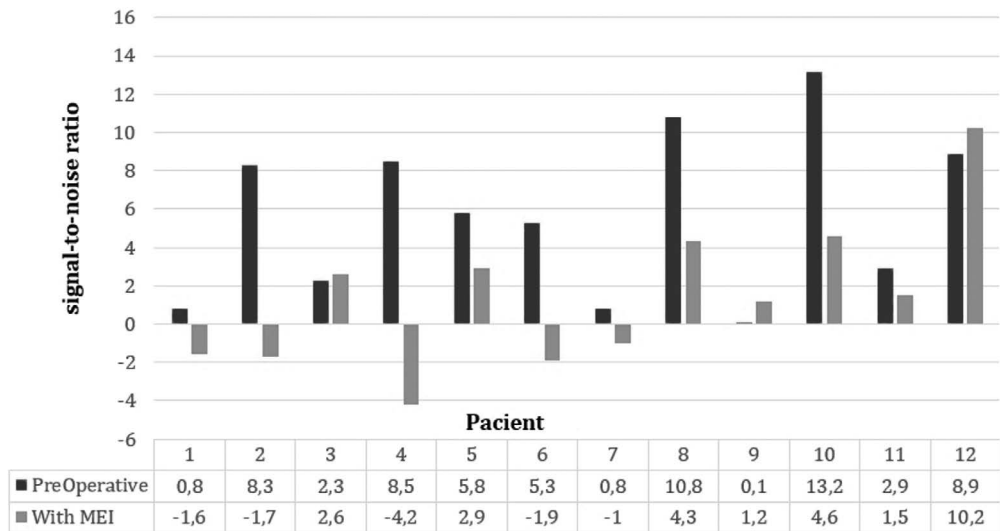


Figure 5. Comparison of preoperative and postoperative signal-to-noise ratios in the hearing in noise test ( $p=0.009$ ).

performed and provides good audiological results with low rates of major complications. However, there are still some skin problems related with percutaneous devices, mainly in tropical countries where the weather is warm and humid. Also, many patients do not wish to use percutaneous devices for aesthetic reasons<sup>[19-21]</sup>. Recently, transcutaneous passive devices are being more frequently prescribed; it has been reported that they cause slight pressure irritation of the skin between the implants and the external base plate<sup>[22]</sup>. Transcutaneous active devices can be challenging, especially in patients who have smaller temporal bones<sup>[23]</sup>. We chose to study the specified MEI as an option to treat conductive or mix hearing loss due to aural atresia in patients with good middle ear anatomy (Jahrsdoerfer score greater than 5) as an option for patients who do not want conventional bone conduction hearing aids.

The versatility of the FMT allows the surgeon to use any vibrating structure of the middle ear as a clip point.

The surgical challenge was to reach the middle ear safely and protect the FMT from soft tissue after the mastoidectomy. We performed a modified mastoidectomy. The atresic bone was drilled; however, we left the malformed external cortical bone intact and allowed it to cover the middle ear like a shell. This technique proved to be safe; also, it allowed comfortable attic exposure, while the remaining tympanic bone was sufficient to prevent contact of the FMT with any with soft tissue. The incision was made 6 cm from the atresic canal to preserve the integrity of tissue vascularization and to allow future aesthetic reconstruction.

After reaching the antrum and attic and exposing the malformed and fixed incus and malleus, two options were available. The malleus-incus block was removed only if it was fixed or had malformed anatomy that could impede clipping of the FMT on the incus. When the malleus and incus were removed, the FMT was positioned on the stapes using a titanium coupler. If the stapes was overly malformed or absent, the FMT was placed over the round or oval window. We chose the oval window in one case and the long or short process of the malformed incus in three cases. FMT stability was maintained in every position.

Another interesting point is that it is possible to stabilize the FMT using a small piece of cartilage or muscle if the surgeon deems it necessary, because the FMT is able to move freely, as it was placed on the oval window in patient 8. We did not observe any complications or situations in which we were not able to implant the FMT. As the middle ear is smaller in these cases, it may be necessary to drill the tympanic bone anteriorly at the level of the tympanic annulus as far as the temporal mandibular joint capsule to the enlarge middle ear space. This is a simple procedure and allows the FMT to be placed free of contact with any bone wall.

The audiological results were better when the FMT was clipped to the stapes or the incus (long or short process) than the results in our only oval-window case. However, this case involved very severe malformation, and the oval window was smaller than usual; therefore, we cannot describe this as a typical outcome<sup>[24, 25]</sup>.

The patients have been followed for the last two years, and they have reported no complications related to the surgery or their hearing stability.

**Ethics Committee Approval:** Ethics committee approval was received for this study from the ethics committee of University of Sao Paulo, Sao Paulo, Brazil.

**Informed Consent:** Written informed consent was obtained from from patients or patients' parents who participated in this study.

**Peer-review:** Externally peer-reviewed.

**Author Contributions:** Concept - R.B., L.F.M.L.; Design - R.B., L.F.M.L., L.M.P.V.; Supervision - R.B., L.F.M.L.; Resources - R.B., L.F.M.L., L.M.P.V.; Materials - R.B., L.F.M.L., L.M.P.V.; Data Collection and/or Processing - R.B., L.F.M.L., L.M.P.V., J.C.J., E.B.O.; Analysis and/or Interpretation - R.B., L.F.M.L., L.M.P.V.; Literature Search - R.B., L.F.M.L., L.M.P.V., J.C.J., E.B.O.; Writing Manuscript - R.B., L.F.M.L., J.C.J., E.B.O.; Critical Review - R.B., L.F.M.L.

**Acknowledgements:** We thank the entire team of professionals at the Hospital for Rehabilitation of Craniofacial Anomalies who collaborated to carry out this study.

**Conflict of Interest:** No conflict of interest was declared by the authors.

**Financial Disclosure:** The authors declared that this study has received no financial support.

## REFERENCES

1. Zawawi F, Kabbach G, Lallemand M, Daniel SJ. Bone-anchored hearing aid: Why do some patients refuse it? *Int J Pediatr Otorhinolaryngol* 2014; 78: 232-4. [\[CrossRef\]](#)
2. Tzortzis S, Tzifa K, Tikka T, Worrollo S, Williams J, Reid AP, et al. A ten-year review of soft tissue reactions around percutaneous titanium implants for auricular prosthesis. *Laryngoscope* 2015; 125: 1934-9. [\[CrossRef\]](#)
3. Lenarz T, Weber BP, Mack KF, Battmer RD, Gnadeberg D. The Vibrant Soundbridge System: a new kind of hearing aid for sensorineural hearing loss. 1: Function and initial clinical experiences. *Laryngorhinootologie* 1998; 77: 247-55. [\[CrossRef\]](#)
4. Luetje CM, Brackman D, Balkany TJ, Maw J, Baker RS, Kelsall D, et al. Phase III clinical trial results with the Vibrant Soundbridge implantable middle ear hearing device: a prospective controlled multicenter study. *Otolaryngol Head Neck Surg* 2002; 126: 97-107. [\[CrossRef\]](#)
5. Colletti V, Soli SD, Carner M, Colletti L. Treatment of mixed hearing losses via implantation of a vibratory transducer on the round window. *Int J Audiol* 2006; 45: 600-8. [\[CrossRef\]](#)
6. Bittencourt AG, Burke PR, Jardim IS, Brito R, Tsuji RK, Fonseca ACO, et al. Implantable and Semi-Implantable Hearing Aids: A Review of History, Indications, and Surgery. *Int Arch Otorhinolaryngol* 2014; 18: 303-10. [\[CrossRef\]](#)
7. Lee JM, Jung J, Moon IS, Kim SH, Choi JY. Benefits of active middle ear implants in mixed hearing loss: Stapes versus round window. *Laryngoscope* 2016 Aug 25. doi: 10.1002/lary.26244 [Epub ahead of print] [\[CrossRef\]](#)
8. Colletti L, Carner M, Mandalà M, Veronese S, Colletti V. The floating mass transducer for external auditory canal and middle ear malformations. *Otol Neurotol* 2011; 32: 108-15. [\[CrossRef\]](#)
9. Frenzel H, Sprinzl G, Streitberger C, Stark T, Wollenberg B, Wolf-Magele A, et al. The Vibrant Soundbridge in children and adolescents: Preliminary European multicentre results. *Otol Neurotol* 2015; 36: 1216-22. [\[CrossRef\]](#)
10. Leinung M, Zaretsky E, Lange BP, Hoffmann V, Stover T, Hey C. Vibrant Soundbridge in preschool children with unilateral aural atresia: acceptance and benefit. *Eur Arch Otorhinolaryngol* 2016 aug 25. doi:10.1007/s00405-016-4265-1 [Epub Ahead of Print] [\[CrossRef\]](#)
11. Jovankovicová A, Staník R, Kunzo S, Majáková L, Profant M. Surgery or implantable hearing devices in children with congenital aural atresia: 25 years of our experience. *Int J Pediatr Otorhinolaryngol* 2015; 79: 975-9. [\[CrossRef\]](#)

12. Jahrsdoerfer RA, Yeakley JW, Aguilar EA, Cole RR, Gray LC. Grading system for the selection of patients with congenital aural atresia. *Am J Otol* 1992; 13: 6-12. [\[CrossRef\]](#)
13. American Academy of Otolaryngology–Head and Neck Surgery Foundation. Committee on Hearing and Equilibrium guidelines for the evaluation of results of treatment of conductive hearing loss. *Otolaryngol Head Neck Surg* 1995; 113: 186-7. [\[CrossRef\]](#)
14. Bevilacqua MC, Banhara MC, Costa EA, Vignoly AB, Alvarenga KF. The Brazilian Portuguese Hearing in Noise Test. *Int J Audiol* 2008; 47: 364-5. [\[CrossRef\]](#)
15. Schuknecht HF. Congenital aural atresia. *Laryngoscope* 1989; 99: 908-17.
16. Snik AF, Mylanus EA, Cremers CW. The bone-anchored hearing aid: a solution for previously unresolved otologic problems. *Otolaryngol Clin North Am* 2001; 34: 365-72. [\[CrossRef\]](#)
17. Hobson JC, Roper AJ, Andrew R, Rothera MP, Hill P, Green KM. Complications of bone-anchored hearing aid implantation. *J Laryngol Otol* 2010; 124: 132-6. [\[CrossRef\]](#)
18. Badran K, Arya AK, Bunstone D, Mackinnon N. Long-term complications of bone-anchored hearing aids: a 14-year experience. *J Laryngol Otol* 2009; 123: 170-6. [\[CrossRef\]](#)
19. Nadaraja GS, Gurgel RK, Kim J, Chang KW. Hearing outcomes of atresia surgery versus osseointegrated bone conduction device in patients with congenital aural atresia: a systematic review. *Otol Neurotol* 2013; 34: 1394-9. [\[CrossRef\]](#)
20. Holgers KM, Tjellstrom A, Bjursten LM, Erlandsson BE. Soft tissue reactions around percutaneous implants: a clinical study of soft tissue conditions around skin-penetrating titanium implants for bone-anchored hearing aids. *Am J Otol* 1988; 9: 56-9.
21. Hobson JC, Roper AJ, Andrew R, Rothera MP, Hill P, Green KM. Complications of bone-anchored hearing aid implantation. *J Laryngol Otol* 2010; 124: 132-6. [\[CrossRef\]](#)
22. Siegert R, Kanderske J. A new semi-implantable transcutaneous bone conduction device: clinical, surgical and audiological outcomes in patients with congenital ear canal atresia. *Otol Neurotol* 2013; 34: 927-34. [\[CrossRef\]](#)
23. O'niel MB, Runge CL, Friedland DR, Kerschner JE. Patient Outcomes in Magnet-Based Implantable Auditory Assist Devices. *JAMA Otolaryngol Head Neck Surg* 2014; 140: 513-20. [\[CrossRef\]](#)
24. Lustig LR, Arts HA, Brackmann DE, Francis HF, Molony T, Megerian CA, et al. Hearing rehabilitation using the BAHA bone-anchored hearing aid: results in 40 patients. *Otol Neurotol* 2001; 22: 328-34. [\[CrossRef\]](#)
25. McKinnon BJ, Dumon T, Hagen R, Lesinskas E, Mlynski R, Profant M, et al. Vibrant soundbridge in aural atresia: does severity matter? *Eur Arch Otorhinolaryngol* 2014; 271: 1917-2.