



Original Article

# Potential Curative Role of Hypericum Perforatum in an Experimental Rat Model of Tympanic Membrane Perforation

Mehmet Yaşar, Altan Kaya, Hatice Karaman, Mustafa Kavugudurmaz, Halil Polat, Mustafa Sağıt, İbrahim Özcan

Department of Otolaryngology, Kayseri Training and Research Hospital, Kayseri, Turkey (MY, AK, HK, HP, MS, İÖ)  
Department of Otolaryngology, Kırşehir Kaman State Hospital, Kırşehir, Turkey (MK)

**OBJECTIVE:** Our aim was to investigate the curative role of topical *Hypericum perforatum* (HP) in a rat model of tympanic membrane perforation in a histopathological manner.

**MATERIALS AND METHODS:** This study was conducted on 30 female Sprague–Dawley rats. An HP extract was prepared as a suspension in pure olive oil. In all rats, the right and left tympanic membranes were perforated by a fine puncture under a microscope. Rats were randomly assigned to three groups. The HP extract was given as drops on a daily basis in Group 1, while olive oil alone was given on a daily basis in Group 2. In Group 3, the rats were allowed spontaneous recovery without any intervention. Three rats from each group were sacrificed on days 7, 14, and 21. Temporal bullae were removed for histopathological examination to evaluate fibroblast proliferation, leukocyte infiltration, neovascularization, and subepithelial thickness and to compare these among the groups.

**RESULTS:** In histopathological examination of the rats from each group on days 7, 14, and 21, there were significant differences in leukocyte infiltration, fibroblast proliferation, and subepithelial thickness. No significant difference was observed in neovascularization among the groups.

**CONCLUSION:** Compared with the spontaneous recovery group, HP was found to be more effective in a wound-healing model of the tympanic membrane. HP may be applied in clinical practice if it is shown to be safe with regard to ototoxicity.

**KEYWORDS:** *Hypericum perforatum*, tympanic membrane perforation, wound healing

## INTRODUCTION

*Hypericum perforatum* (HP) is a herb famous for its yellow flowers and its benefits in various medical conditions. It can be found in a wide area, including Europe, western Asia, northern Africa, and the United States <sup>[1]</sup>. *Hypericum* species are also widely distributed in Turkey. It is known that there are 81 species, but only HP is reported to be effective in wound healing <sup>[2]</sup>. Maisenbacher and Kovar analyzed HP and identified the substances hyperforin and hypericin in its composition. The authors also showed in bioassays that hypericin is the substance that is effective in wound healing <sup>[3]</sup>. In Turkish folk medicine, it has been known for ages as a remedy used for different types of wounds, and its healing potential has been practiced against urogenital inflammation, diabetes mellitus, neuralgia, heart disease, and even hemorrhoids. In recent years, a large number of studies have been conducted on HP, addressing its effects on gastric ulcers, intestinal disease, burns, and skin wounds <sup>[4-6]</sup>. Other paper indicate its antioxidant and free radical scavenger activity due to its rich content of flavonoids <sup>[5]</sup>. The literature suggests that its contents can have antidepressant, antimicrobial, and antiviral activities <sup>[6,7]</sup>.

The wound-healing activity of HP has been studied in different types of experimental wound models. In a recent study by Süntar et al. <sup>[8]</sup>, HP olive oil extract and ethanol extract and subfractions showed significant healing activity in incisional and excisional wound models, and these results were later confirmed in a subsequent publication <sup>[9]</sup>.

Chronic tympanic membrane perforations are common disorders of the ear, and a remarkable number of patients suffering from such situations visit otolaryngologists every day. Some perforations are suitable for outpatient repair procedures, while others require a tympanoplasty for management. The risk, morbidity, and cost of an ear operation are understandable concerns, and most patients postpone or even refuse treatment because of such consequences. It is likely these patients could be helped more efficiently with an inexpensive, simple, and outpatient method of treatment. With this point of view, many researchers have been trying to find a more

**Presented in:** This study was presented 36<sup>th</sup> Turkish National Congress of Otorhinolaryngology Diseases and Head and Neck Surgery, 5-9 November 2014, Antalya, Turkey.

**Corresponding Address:** Mehmet Yaşar E-mail: drmyasar@hotmail.com

**Submitted:** 21.09.2015

**Revision received:** 6.12.2015

**Accepted:** 21.03.2016

©Copyright 2016 by The European Academy of Otolaryngology and Neurotology and The Politzer Society - Available online at [www.advancedotology.org](http://www.advancedotology.org)

comfortable and practical treatment protocol. In attempts to find a way for a better solution of this problem, experimental wound models on the tympanic membrane of rats have been applied and the results published. Previous studies have revealed the positive and negative effects of various agents on the healing of tympanic membranes, including hyaluronic acid, epidermal growth factor, transforming growth factor, platelet-derived growth factor, and platelet-rich plasma [10-13]. To the best of our knowledge, there are no data showing that HP has been used for healing tympanic membranes.

Therefore, we aimed to assess the effect of HP olive oil extract on the wound-healing process in experimentally perforated tympanic membranes of rats.

## MATERIALS AND METHODS

### Animals

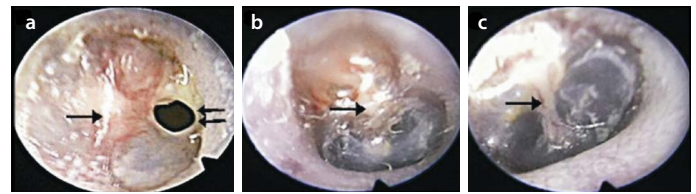
This study was conducted on 30 female Sprague–Dawley rats aged  $\geq 6$  weeks, weighing 200–300 g. The rats were fed with standard rat pellet and tap water ad libitum. Rats were housed in separate cages (five rats per cage) under standard conditions at a temperature of 21°C and maintaining a 12-hour dark–light cycle. This study was approved by the Ethics Committee on Animal Experiment and Research (2013-13/ 112).

### Experimental Procedure

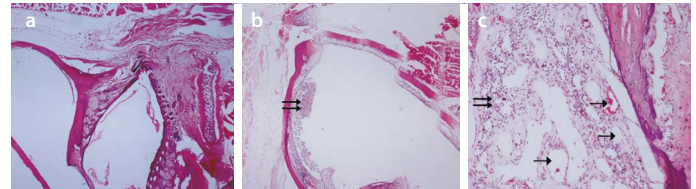
*Hypericum perforatum* was harvested from rural areas of Adana Province in July and then dried. In the laboratory, 50 g of dry HP was weighed. The weighed HP was immersed in 500 cc of olive oil in glass jars and left in the sunshine over 4 weeks until the occurrence of a red coloration. There is also a traditional recipe for this: “the content of the jar should be exposed to the heat of the sun and the breeze of the night” [8]. The rats were randomly assigned to three groups as follows: Group 1 (n=10) received HP, Group 2 (n=10) received 10% olive oil, and Group 3 (n=10) received no therapy. By oto-microscopic evaluation, rats without inflammation, trauma, or disease in both ears were included in the study. None of the rats were excluded for these reasons. Both ears of the rats were included in the same study group.

### Study Design

Rats were anesthetized using a ketamine hydrochloride (Ketalar, Eczacıbaşı; İstanbul, Turkey) dose of 100 mg/kg and a xylazine (Rompun, Bayer; Leverkusen, Germany) dose of 7.5 mg/kg via an intraperitoneal route. After being secured on a board, the rats were examined through a speculum inserted into the external auditory canal (EAC) under a surgical microscope. Tympanic membranes were visualized by removing debris and cerumen. After inspection of the EAC and tympanic membranes, a 3 mm perforation was made in the inferior lower quadrant using a 0.4 mm incisive puncture. Videos of tympanic membranes were recorded after perforation on the 7<sup>th</sup>, 14<sup>th</sup>, and 21<sup>st</sup> days by using an oto-endoscope (Wolf; Tuttlingen, Germany) (Figure 1a-c). A drop of relevant test substance was put into both EACs on alternate days. To assess early and late wound healing, three rats from each group were sacrificed on days 7 and 14; four rats from each group were sacrificed on the 21<sup>st</sup> day by administration of a high-dose anesthetic combination via an intracardiac route. The temporal bullae were then removed by wide resection in order to spare the tympanic membrane and surrounding tissues.



**Figure 1.** a-c. Video-endoscopic view showing tympanic membrane perforation on the 7<sup>th</sup> day (a), 14<sup>th</sup> day (b), and 21<sup>st</sup> day (c) for *Hypericum perforatum* groups. →: Malleus; ⇨: Tympanic membrane perforation



**Figure 2.** a-c. Spontaneous healing group (a). Histologic examination of hematoxylin and eosin-stained rat tympanic membrane sections of a group of rats treated with hypericum. Day 21, showing increased leukocyte cells, fibroblast cells, and exudation (b). Histologic examination of hematoxylin and eosin-stained rat tympanic membrane sections of a group of rats treated with olive oil. Day 7, showing neovascularization and prominent fibroblast cells (H&E;  $\times 20$ ) (c), →: Neovascularization; ⇨: Exudation

### Histomorphological Evaluation

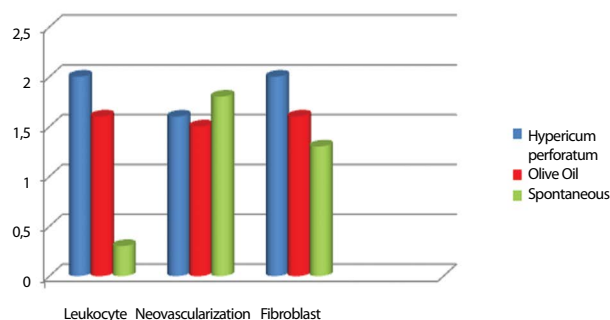
The tissues were fixed in 10% formalin and embedded in paraffin. To enable histopathological examination, the specimens were decalcified in a solution of formic acid and sodium citrate and the tympanic bullae were bisected, creating a transverse section of the tympanic membrane bisecting through the short process of the malleus. One paraffin-embedded tissue block was selected from each case and cut into 5  $\mu$ m sections, stained with hematoxylin and eosin and examined under light microscopy. Tissue sections were deparaffinized with xylene and washed with ethanol. The pathologist was blinded to the histological sections of the groups. Histologically, the perforated tympanic membranes were evaluated with respect to infiltration of leukocytes, neovascularization, fibroblast proliferation and thickness of the subepithelial connective tissue. Histopathologically, the presence of lamina propria edema, neovascularization, and fibroblast proliferation was scored subjectively as -, + (weak), ++ (moderate), or +++ (remarkable). The tympanic membrane thickness was quantitatively measured in micrometers.

### Statistical Analyses

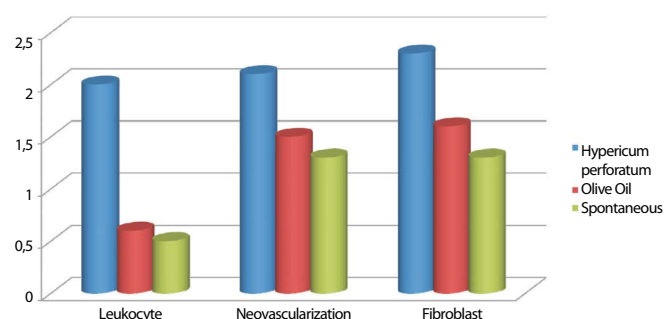
Data were analyzed using the SPSS (Statistical Package for the Social Sciences, version 21.0, IBM Corp.; New York, USA) for Windows. A p value  $< 0.05$  was considered as statistically significant. The Kruskal–Wallis test was used to compare groups. The non-parametric multiple comparison test was used to identify factors causing a difference.

## RESULTS

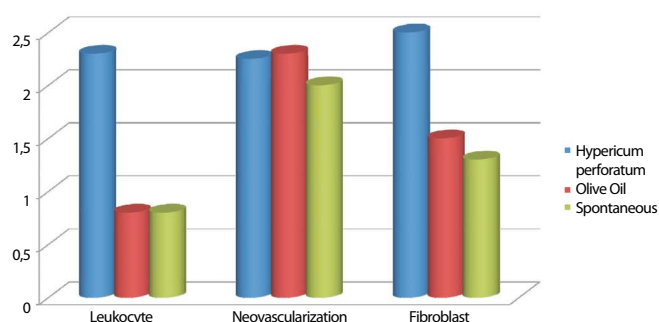
Healing results were compared among the rats sacrificed on days 7, 14, and 21 (Figure 2). On day 7, there were significant differences in the leukocyte count, fibroblast count and subepithelial thickness ( $p < 0.001$ ,  $p = 0.004$ , and  $p = 0.02$ , respectively). Multiple comparison tests revealed that the difference resulted from Group 1. There was no significant difference in neovascularization among the groups ( $p = 0.254$ ) (Figure 3). On day 14, there were significant differences in the leukocyte count, fibroblast count, and subepithelial thickness ( $p = 0.003$ ,  $p = 0.03$ , and  $p = 0.09$ , respectively). Multiple comparison



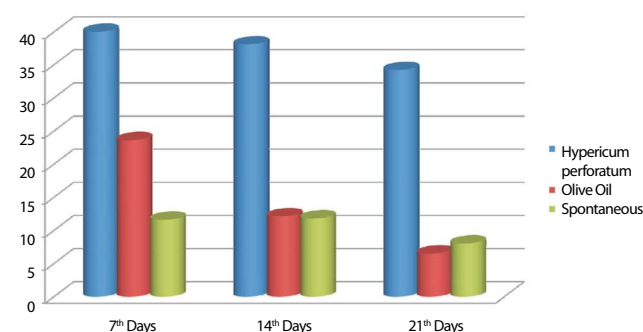
**Figure 3.** On day 7, compared with the other groups, significant increases were detected in the leukocyte and fibroblast counts in the HP group.



**Figure 4.** On day 14, compared with the other groups, significant increases were detected in the leukocyte and fibroblast counts in the HP group.



**Figure 5.** On day 21, compared with the other groups, significant increases were detected in the leukocyte and fibroblast counts in the HP group.



**Figure 6.** On days 7, 14, and 21, significant increase was detected in the subepithelial thickness in the HP group when compared to other groups.

tests revealed that the difference resulted from Group 1. There was no significant difference in neovascularization among the groups ( $p=0.08$ ) (Figure 4). On day 21, there were significant differences in the leukocyte count, fibroblast count, and subepithelial thickness ( $p=0.003$ ,  $p=0.006$ , and  $p=0.01$ , respectively). Multiple comparison tests revealed that the difference resulted from Group 1. There was no significant difference in neovascularization among the groups ( $p=0.592$ ) (Figure 5). Subepithelial thickness was to be found higher in Group 1 than in the other groups (Figure 6).

## DISCUSSION

Many studies of experimental excisional and incisional animal models of wound healing have found that *Hypericum* species are effective in wound healing [8, 14, 15]. In an in vitro study on chicken embryonal fibroblasts by Öztürk et al. [16], it was shown that an ethanolic extract of HP (50%) had positive effects on wound healing. In a study on rats by Zdunic et al. [17], it was shown that HP had an anti-inflammatory activity equivalent to indomethacin, in addition to gastroprotective activity. The authors concluded that the gastroprotective activity was similar to that of quercetin and 12, II18-biagen. It is known that anti-inflammatory activity results from the pseudohypericin and hyperforin components of HP [18]. On the other hand, it is known that *Hypericum* species have antibacterial and antiviral activities [19]. Ultimately, lack of infection at the wound site is an important factor in wound healing.

Many studies have been performed suggesting that HP is effective in wound healing. In a study by Süntar et al. [8], it was found that active HP extracts enhanced re-epithelization, neovascularization and the proliferation capacity of fibroblasts. In a study using a wound-healing model, Castro et al. [20] found that cell migration was increased around the wound site on days 6 and 10. The authors also found that tissue reorganization and collagen fibril maturation were increased prominently on day 6. In addition, the authors reported that blood flow was enhanced by increasing the calibration of vessels in tissues undergoing repair processes and demonstrated that this was associated with neovascularization. Öztürk et al. [16] suggested that the effects of HP on wound healing occur through the stimulation of fibroblast migration and collagen synthesis, but are not associated with mitotic activity. In addition to animal models, Samadi et al. [21] showed in a clinical study that HP is effective with cesarean wounds.

Tympanic membrane perforation is an undesirable condition that causes conductive hearing loss and exposes important structures of the inner ear to outer media. Treatment is surgical closure of the perforation under appropriate conditions in TM perforation. The treatment involves an invasive procedure requiring specialized equipment, resources and experience [12]. Thus, simple, non-invasive therapeutic modalities are needed that are less complicated. Several agents, including hyaluronan, heparin, epidermal growth factor, platelet-derived growth factor, transforming growth factor, and platelet-rich plasma have been used in the repair of tympanic membrane perforations [10, 13, 22-24]. Erkilet et al. [13] created a rat model of tympanic membrane perforation and administered platelet-rich plasma in this model. Although the authors failed to demonstrate a significant improvement histologically, they reported a significant decrease in recovery time ( $10.2 \pm 2.1$  days) when compared to a control group. In a guinea pig model, Dere et al. [25] investigated wound

healing in tympanic membrane perforation using fibroblast growth factor and found that the tympanic membrane was thickened with epithelial hyperplasia. Mondain et al. <sup>[26]</sup> reported that the recovery time was shorter with fibroblast growth factor and that the fibrous layer of the tympanic membrane was covered with polymorphonucleocytes following keratin on day 3. In another study, keratinocyte GF, FGF 2 and FGF 10 were used in a rat model of tympanic membrane perforation. The authors found that KGF1 and FGF 2 played a primary role in keratinocyte migration and proliferation in the histomorphological evaluation on days 7 and 14. The authors also reported that keratinocytes diffused into connective tissue in wound healing with FGF10 <sup>[27]</sup>. Differently, wound healing on day 21 was also assessed in order to see the effect of treatment on the late phase of wound healing and HP was found to be effective in our study. In our study, we saw that the tympanic membrane was covered with a thick fibrous tissue on gross examination in all rats from all groups on day 14. Our study revealed that fibroblast proliferation was increased at the early and late phases in the group that had received HP. This result was in line with effects reported in the literature for different substances used to improve wound healing. In our study, HP improved fibroblast proliferation in the middle layers in the pars tensa of the tympanic membrane and contributed to wound healing. HP was found to be more effective than the olive oil used as the solvent. No evaluation regarding the antibacterial effect of HP was performed in the present study, but a lack of otitis development despite topical use via a perforated membrane and being housed in a cage together is supportive of antibacterial activity, as suggested in the literature. This implies that HP may make secondary contributions to wound healing by preventing wound site infection.

Tympanic membrane perforation is repaired in a manner similar to three phases observed in classical wound healing, which are known as the inflammatory, proliferative and remodeling phases. Tympanic membrane wound healing is a complex process involving epithelial migration, increased fibroblastic reaction, vascular proliferation, and tissue remodeling. Following perforation, leukocytes, fibroblasts, and other cellular elements are initially recruited to the wound site and the margins of perforation are thickened through mitotic activity. There is a thickening in the tympanic membrane, including in non-perforated areas, due to proliferation of the subepithelial layer <sup>[28]</sup>. Vascular proliferation begins when the proliferation phase starts and there is also squamous epithelium migration in this phase. As such, perforation is closed by approximation of the epithelial cells and keratin layer <sup>[29]</sup>. After closure of the tympanic membrane perforation, the remodeling phase begins and wound healing is completed. The increased number of leukocytes at the wound site leads to an increase in matrix metalloproteinases being released from the leukocytes. These enzymes contribute to re-epithelization and remodeling in the wound-healing process <sup>[30]</sup>. Fibroblasts recruited to the TM perforation site are major cells of connective tissue. An increase in fibroblasts leads to closure of the perforation by accelerating epithelization through bridges resulting from the increased collagen synthesis <sup>[28]</sup>. In the *Hypericum* group, increased leukocyte and fibroblasts can contribute to an acceleration of wound healing through the above-mentioned pathways.

In a review on models of chronic tympanic membrane perforation, Wang et al. <sup>[31]</sup> emphasized that these models are more appropriate

than models of acute tympanic membrane models in the assessment of novel treatment modalities and their effectiveness but that these methods should be standardized. In our study, our primary goal was to reveal whether HP is as effective in other wound models, although the model used in our study was a model of acute tympanic membrane perforation. In this study, it was shown that HP was effective in wound healing for acute tympanic membrane perforation. Given the antibacterial, anti-inflammatory and positive effect of wound healing, further studies on the feasibility of HP in chronic perforation models are needed. In clinical practice, antibiotics and steroids are recommended in the postoperative period for otological surgery. HP could make positive contributions to treatment in the postoperative period, if it could be established that HP is not ototoxic by further studies.

As a matter of fact, there are some limitations of our study that we have to mention. The most important criterion of success is recovery time in the model of tympanic membrane perforation. One of the major limitations of the present study is the failure to determine the time to recovery due to the lack of daily oto-endoscopic recordings resulting from technical issues. Another limitation of this study is the lack of investigating the effectiveness of the drug in perforations with different sizes and different localizations on TM. This is needed to clarify the effectiveness of drug on perforation models that include perforations with various sizes and localizations.

This is the first study investigating the potential curative role of HP in an experimental rat model of tympanic membrane perforation. In light of these findings, we conclude that HP may be effective in wound healing in tympanic membrane perforation. Thus, it may be practical and effective in conditions normally requiring experience and equipment, such as tympanic membrane perforation. It could be introduced into clinical use in otology after further studies are conducted on ototoxicity. HP can be an alternative therapeutic modality since it seems to be cost-effective and minimally invasive in wound models of TM in general.

**Ethics Committee Approval:** Ethics committee approval was received for this study from the ethics committee of Erciyes University (No: 2013-13/112).

**Informed Consent:** N/A.

**Peer-review:** Externally peer-reviewed.

**Author Contributions:** Concept - M.Y., M.S.; Design - M.Y., M.K.; Supervision - I.O., M.S.; Funding - I.O., M.Y.; Materials - H.P., A.K.; Data Collection and/or Processing - H.K., M.K.; Analysis and/or Interpretation - M.Y., H.K.; Literature Review - H.P., A.K.; Writer - M.Y., M.S.; Critical Review - I.O., M.S.; Other - M.K., H.P.

**Acknowledgements:** Authors would like to thank Celil Ünver for his contribution to their study.

**Conflict of Interest:** No conflict of interest was declared by the authors.

**Financial Disclosure:** The authors declared that this study has received no financial support.

## REFERENCES

1. Greeson JM, Sanford B, Monti DA. St. John's wort (*Hypericum perforatum*): A review of the current pharmacological, toxicological, and clinical literature. *J Psychopharmacol* 2001; 153: 402-14. [\[CrossRef\]](#)



2. Süntar I, Küpeli Akkol E, Keleş H, Oktem A, Baser KHC, Yeşilada E. A novel wound healing ointment: a formulation of Hypericum perforatum oil and sage and oregano essential oils based on traditional Turkish knowledge. *J Ethnopharmacol* 2011; 134: 89-96. [\[CrossRef\]](#)
3. Maisenbacher P, Kovar KA. Analysis and stability of Hyperici oleum. *Planta Medica* 1992; 58: 351-4. [\[CrossRef\]](#)
4. Yeşilada E, Honda G, Sezik E, Tabata M, Goto K, Ikeshiro Y. Traditional medicine in Turkey IV. Folk medicine in the Mediterranean subdivision. *J Ethnopharmacol* 1993; 39: 31-8. [\[CrossRef\]](#)
5. Silva BA, Ferreres F, Malva JO. Phytochemical and antioxidant characterization of Hypericum perforatum alcoholic extracts. *Food Chem* 2005; 90: 157-67. [\[CrossRef\]](#)
6. Barnes J, Anderson LA, Phillipson JD. St John's wort (Hypericum perforatum L.): a review of its chemistry, pharmacology and clinical properties. *J Pharmacy Pharmacol* 2001; 53: 583-600. [\[CrossRef\]](#)
7. Andersen DO, Weber ND, Wood SG, Hughes BG, Murray BK, North JA. In vitro virucidal activity of selected anthraquinones and anthraquinone derivatives. *Antiviral Research* 1991; 16: 185-96. [\[CrossRef\]](#)
8. Süntar IP, Küpeli Akkol E, Yilmazer D, Baykal T, Kirmizibekmez H, Alper M, et al. Investigations on the in vivo wound healing potential of Hypericum perforatum L. *J Ethnopharmacol* 2010; 127: 468-77. [\[CrossRef\]](#)
9. Lavagna SM, Secci D, Chimenti P, Bonsignore L, Ottaviani A, Bizzarri B. Efficacy of Hypericum and Calendula oils in the epithelial reconstruction of surgical wounds in childbirth with caesarean section. *Farmaco*. 2001; 56: 451-3. [\[CrossRef\]](#)
10. Güneri EA, Tekin S, Yilmaz O, Ozkara E, Erdağ TK, İkiz AO, et al. The effects of hyaluronic acid, epidermal growth factor and mitomycin in an experimental model of acute traumatic tympanic membrane perforation. *Otol Neurotol* 2003; 24: 371-6. [\[CrossRef\]](#)
11. Kaftan H, Herzog M, Mieke B, Hosemann W. Topical application of transforming growth factor-β1 in acute traumatic tympanic membrane perforations: An experimental study in rats. *Wound Repair Regen* 2006; 14: 453-66. [\[CrossRef\]](#)
12. Yeo SW, Kim SW, Suh BD, Cho SH. Effects of platelet-derived growth factor-AA on the healing process of tympanic membrane perforation. *Am J Otolaryngol* 2000; 21: 153-60. [\[CrossRef\]](#)
13. Erkillet E, Koyuncu M, Atmaca S, Yarim M. Platelet-rich plasma improves healing of tympanic membrane perforations: experimental study. *J Laryngol Otol* 2009; 123: 482-7. [\[CrossRef\]](#)
14. Rao SG, Udupa SL, Rao PGM, Rao G, Kulkarni DR. Calendula and Hypericum: two homeopathic drugs promoting wound healing in rats. *Fitoterapia* 1991; 6: 508-10.
15. Mukherjee PK, Verpoorte R, Suresh B. Evaluation of in vivo wound healing activity of Hypericum patulum (Family: Hypericaceae) leaf extract on different wound model in rats. *J Ethnopharmacol* 2000; 70: 315-21. [\[CrossRef\]](#)
16. Öztürk N, Korkmaz S, Öztürk Y. Wound - healing activity of St. John's Wort (Hypericum perforatum L.) on chicken embryonic fibroblasts. *J Ethnopharmacol* 2007; 111: 33-9. [\[CrossRef\]](#)
17. Zdunic G, Godevac D, Milenkovic M, Vucicevic D, Savikin K, Menkovic N, et al. Evaluation of Hypericum perforatum Oil Extracts for an Antiinflammatory and Gastroprotective Activity in Rats. *Phytotherapy Research* 2009; 23: 1559-64. [\[CrossRef\]](#)
18. Albert D, Zündorf I, Dingermaier T, Müller WE, Steinhilber D, Werz O. Hyperforin is a dual inhibitor of cyclooxygenase-1 and 5-lipoxygenase. *Biochem Pharmacol* 2002; 64: 1767-75. [\[CrossRef\]](#)
19. Cecchini C, Cresci A, Coman MM, Ricciutelli M, Sagratini G, Vittori S, et al. Antimicrobial activity of seven hypericum entities from central Italy. *Planta Med* 2007; 73: 564-66. [\[CrossRef\]](#)
20. Castro FC, Magre A, Cherpinski R, Zelante PM, Neves LM, Esquisatto MA, et al. Effects of microcurrent application alone or in combination with topical Hypericum perforatum L. and Arnica montana L. on surgically induced wound healing in Wistar rats. *Homeopathy* 2012; 101: 147-53. [\[CrossRef\]](#)
21. Samadi S, Khadivzadeh T, Emami A, Moosavi NS, Tafaghodi M, Behnam HR. The effect of Hypericum perforatum on the wound healing and scar of cesarean. *J Altern Complement Med* 2010; 16: 113-7. [\[CrossRef\]](#)
22. Ozturk K, Yaman H, Cihat Avunduk M, Arbag H, Keles B, Uyar Y. Effectiveness of MeroGel hyaluronic acid on tympanic membrane perforations. *Acta Otolaryngol* 2006; 126: 1158-63. [\[CrossRef\]](#)
23. Ramalho JR, Bento RF. Healing of subacute tympanic membrane perforations in chinchillas treated with epidermal growth factor and pentoxifylline. *Otol Neurotol* 2006; 27: 720-7. [\[CrossRef\]](#)
24. Somers T, Goovaerts G, Schelfhout L, Peeters S, Govaerts PJ, Offeciers E. Growth factors in tympanic membrane perforations. *Am J Otol* 1998; 19: 428-34.
25. Dere H, Unal A, Ozcan I, Yardimci S, Ergul G, Titiz A, et al. Histological evaluation of basic fibroblast growth factor effect on the healing of traumatic tympanic membrane perforation (in Turkish). *Türk Otolarengoloji Arsivi* 1997; 35: 33-7.
26. Mondain M, Saffiedine S, Uziel A. Fibroblast growth factor improves the healing of experimental tympanic membrane perforations. *Acta Otolaryngol* 1991; 111: 337-41. [\[CrossRef\]](#)
27. Santa Maria PL, Redmond SL, Atlas MD, Ghassemifar R. Keratinocyte growth factor 1, fibroblast growth factor 2 and 10 in the healing tympanic membrane following perforation in rats. *J Mol Histol* 2011; 42: 47-58. [\[CrossRef\]](#)
28. Mondain M, Ryan A. Histological study of the healing of traumatic tympanic membrane perforation after basic fibroblast growth factor application. *Laryngoscope* 1993; 103: 312-8. [\[CrossRef\]](#)
29. Somers T, Houben V, Goovaerts G, Govaerts PJ, Offeciers FE. Histology of the perforated tympanic membrane and its muco-epithelial junction. *Clin Otolaryngol* 1997; 22: 162-6. [\[CrossRef\]](#)
30. Rennekampff HO, Hansbrough JF, Kiessig V, Doré C, Sticherling M, Schröder JM. Bioactive interleukin-8 is expressed in wounds and enhances wound healing. *J Surg Res* 2000; 93: 41-54. [\[CrossRef\]](#)
31. Wang AY, Shen Y, Wang JT, Friedland PL, Atlas MD, Dilley RJ. Animal models of chronic tympanic membrane perforation: A 'time-out' to review evidence and standardize design. *Int J Pediatr Otorhinolaryngol* 2014; 78: 2048-55. [\[CrossRef\]](#)