



Original Article

Endolymphatic Duct Blockage for Refractory Ménière's Disease: Assessment of Endolymphatic Sac Biopsy on Short-Term Surgical Outcomes

Marc-Henri Asmar, Issam Saliba

Division of Otolaryngology-Head & Neck Surgery, University of Montreal Hospital Centre (CHUM), Montreal, QC, Canada (MHA, IS)
University of Montreal Hospital Centre Research Centre (CRCHUM), Montreal, QC, Canada (IS)

OBJECTIVE: Endolymphatic sac decompression (ESD) for the treatment of Ménière's disease (MD) has had limited success and variable results in the literature. We have devised a novel technique that involves blocking the endolymphatic duct with surgical clips. In a separate effort to study the endolymphatic sac (ELS), we have sectioned the lateral part of the main body of the ELS as biopsies from a subset of patients. We aimed to evaluate the effect of the lateral part sectioning of the ELS on short-term surgical outcomes.

MATERIALS and METHODS: This was a single-physician, retrospective study in a tertiary medical center. MD patients underwent endolymphatic duct blockage (EDB) surgery with or without ELS biopsy. The assessed surgical outcomes were the occurrence of benign paroxysmal positional vertigo (BPPV), intraoperative CSF leaks, aural fullness, tinnitus, vertigo spells, and pure tone audiometry. Data were collected at the following visits: preoperatively 1st week, 1st month, and 6th months.

RESULTS: A total of 63 patients were included. The outcomes of the biopsy group (EDB+B) (n=27) were compared to those of the EDB group (n=36) at each visit. There was no significant difference in the occurrence of postoperative BPPV, CSF leaks, aural fullness, tinnitus, or vertigo spells. The SDS, the PTA, and bone conduction were not significantly different at any visit, and PTA variations were similar in both groups.

CONCLUSION: Our results suggest that aggressive decompression of the ELS by sectioning the sac does not benefit patients in the early postoperative period. The short-term success of EDB surgery is attributable to the effective obstruction of the endolymphatic duct regardless of pressure in the ELS.

KEYWORDS: Meniere's disease, Endolymphatic duct, Endolymphatic sac, decompression, CSF leak, endolymphatic shunt

INTRODUCTION

Ménière's Disease (MD) is an idiopathic cochleovestibular disease characterized by episodic vertigo spells associated with fluctuating hearing loss, aural fullness, and tinnitus. Many experts agree that endolymphatic hydrops explains the underlying pathology, but there is lack of satisfactory evidence for this hypothesis. A recent study documented a decreased perilymph-to-endolymph ratio following endolymphatic sac decompression (ESD) surgery on MRI with gadolinium injected in the Eustachian tubes^[1], which supports the hydrops theory. Other authors have found no relationship between the resolution of hydrops and relief from vertigo symptoms^[2].

Treatment for MD includes an initial trial of medical therapy and lifestyle changes (avoiding caffeine, alcohol, theine, and salt) that achieve adequate disease control in roughly two-thirds of patients^[3]. Medical therapy may include diuretics, vasodilators, and symptomatic treatment for nausea and vomiting. MD is considered as intractable or refractory if there is a failure of medical therapy, for which more aggressive treatment options have been considered. Intratympanic gentamicin injections for instance, one of the less invasive options, provide moderate vertigo control but no hearing improvement^[4]. ESD surgery is a popular choice for invasive therapeutic interventions among neuro-otologists, but it remains an individual centered decision as evidence backing it in the literature is inconclusive: a 2013 Cochrane systematic review found only two randomized controlled trials on a total of 59 patients that did not show significant changes in vertigo or auditory outcomes^[5]. Several variations of ESD surgery have been attempted over the past few decades, including sac shunting, sac drainage, sac decompression, or even sigmoid sinus decompression^[6]. A famous study conducted by Thomsen et al.^[7,8] in 1981 and concluded in 1986 compared sac shunting to a placebo procedure (mastoidectomy) and found no benefit of the endolymphatic sac (ELS) shunting procedure; their analysis was later criticized by Welling and Nagaraja^[9]. Sac shunting was found to be effective in this instance, but data remains variable and controversial in several studies^[10]. A meta-analysis in 2014 by Sood et al.^[11] found that sac decompression and sac shunting both achieve approximately 75% vertigo control with hearing preservation in favor of decompression. Over the past few years, we have established a novel surgical

technique, the endolymphatic duct blockage (EDB) surgery, for the treatment of intractable MD and have performed it at our institution on refractory cases with considerable success^[12]. In a separate basic research effort to study the diseased ELS histopathology, we have taken biopsies from the ELS during surgery. This would be similar in effect to short-term sac shunting with the main difference being the blockage of the endolymphatic duct before the excision of the lateral part of the ELS body, thus preventing endolymphatic flow from the sac. The aim of this study was to evaluate the impact of ELS biopsies on surgical outcomes in the short-term postoperative period (6 months).

MATERIALS and METHODS

Study Design and Patient Population

This retrospective, single-physician, single-center comparative study was conducted in 2015 at our tertiary care center. The patient pool from which we selected our participants comprised MD patients refractory to medical therapy who underwent EDB surgery since November 2010 at our institution. Electronic medical charts were reviewed for all MD patients, and all operated patients were considered. In a separate basic research effort to study the ELS histopathology, our team performed ELS biopsies on numerous operated patients. Sac biopsy is not part of the standard treatment, and these patients were offered the option to participate in the research on the day of their surgery. Documented ELS biopsies in the operative report and a follow-up of at least 6 months were the only inclusion criteria used to identify our EDB+B group. Inclusion criteria for the EDB group were EDB surgery for the treatment of refractory MD with no documented intraoperative ELS biopsy and a minimum follow-up of 6 months. Exclusion criteria for both groups were (1) a surgical history of previous interventions for MD such as ESD surgery or semi-circular canal obliteration, (2) incomplete clinical follow-up during the first 6 months postoperatively, (3) repeated EDB surgery in the first 6 months to revise the surgical clip position, and (4) bilateral MD. Patients who satisfied both inclusion and exclusion criteria were randomly selected from the EDB without biopsy pool and were included (EDB group). Electronic medical charts were reviewed for data related to surgical outcomes: pure tone averages (PTAs) for air conduction, bone conduction thresholds (BCTs), speech discrimination scores, vertigo episodes, aural fullness, tinnitus, intraoperative CSF leaks, and postoperative BPPV.

Montreal University Hospital Center (CHUM) institutional ethics board approved the study, and we met the standards of this ethics committee. Written informed consent was obtained from patients who participated in this study. Patient names and chart numbers were not collected during chart review, and case numbers were assigned for anonymity.

Patients and Outcome Measures

Sixty-three patients met our criteria and were included. Twenty-seven patients were assigned to the EDB+B group, and 36 were assigned to the EDB without biopsy group. Age and sex were not significantly different between the groups (Table 1). All patients had unilateral MD and had undergone EDB surgery. Data were collected from electronic medical charts based on consultations in the ENT clinic of our institution by the investigator. The treating surgeon (primary investiga-

Table 1. Demographic parameters

	EDB+B	EDB	p
N	27	36	
Male	7 (26%)	14 (39%)	0.28
Female	20 (74%)	22 (61%)	
Mean Age (years)	54.2±10.72	49.78±12.35	0.14

AC: air-conduction threshold; BC: bone-conduction threshold; Gap: air-bone difference; dB nHL: decibel hearing level; PTA: pure tone average (mean of pure tone hearing thresholds at 0.5, 1, 2, and 4 kHz) EDB: endolymphatic duct blockage surgery; EDB+B: endolymphatic duct blockage surgery with endolymphatic sac biopsy

tor) was not responsible for collecting or analyzing data. Data from preoperative visits and follow-ups at 1 week, 1 month, and 6 months postoperatively were collected from standardized clinic notes that include the following parameters: time elapsed since surgery, postoperative complications and adverse events, full neurotologic examination, the number of vertigo spells since the last visit and associated symptoms, the presence of tinnitus and aural fullness, and test results for pure tone audiometry. Our follow-up duration was limited to 6 months because the objective was to determine the effect of sectioning the lateral part of the ELS on short-term surgical outcomes.

Vertigo was reported as the cumulative number of episodes since the last visit. Preoperative vertigo was defined as the cumulative number of vertigo spells in the last 6 months before the day of surgery.

Aural fullness and tinnitus were reported as absent or present at each postoperative visit.

Hearing was evaluated by pure tone audiometry testing, which was performed at our institution for all patients at every control visit and on the day before surgery. Speech discrimination scores (SDSs) were recorded and the PTA was calculated from thresholds at 0.25, 0.5, 1, 2, and 4 kHz frequencies of the affected ear. The mean BCTs were calculated from thresholds at 0.5, 1, 2, and 4 kHz. A variation of at least 10 dB on the PTA and 15% on the SDS were considered clinically significant.

Surgical Protocol of EDB^[12]

The first step of our procedure was canal wall-up mastoidectomy to identify the tegmen mastoideum, the sigmoid sinus, and the sinodural angle and to thin the posterior bony ear canal wall. The posterior semi-circular canal and posterior fossa dura matter were then identified. The Donaldson line was estimated using the prominence of the horizontal semi-circular canal to approximate the position of the ELS. Thinning of the bone over the dura and sac was then performed using diamond burrs. At this point of the procedure, the sac was completely skeletonized and decompressed. The infralabyrinthine dura was then exposed with care not to incise the sac or dissect it off the posterior fossa dura: this exposes the main body of the ELS. For the ELS biopsy, the entire lateral portion of the sac was dissected with care to not damage the surrounding dura matter, and the biopsy was sectioned from the main body of the ELS. The bone of the vestibular aqueduct operculum and the posterior fossa dura from the retrolabyrinthine bone medial to the sac were then dissected, aiming to expose the endolymphatic duct's superior and inferior borders and its origin from the main body of the sac. The space around the exposed duct was then used to position the instrument to clip the duct. Care must be taken to avoid

damaging the thin dura as intraoperative CSF leaks were likely to occur at this point of the procedure. The final step was to occlude the duct with two small titanium clips using a ligating clip applier similar to the one utilized for vascular surgery.

Intraoperative CSF Leak Management ^[12]

We previously reported in our pilot study that 14% of our operated patients had a minor CSF leak during EDB surgery because of accidentally damaging the very thin dura matter from the petrous bone around the endolymphatic duct ^[4]. CSF leaks were managed by patching the dura matter tear with a temporalis fascia graft, covered by BioGlue (albumin/glutaraldehyde sealant). No postoperative restriction was asked for the patient^[12].

Statistical Analysis

Statistical analysis was performed using Statistical Package for the Social Sciences (SPSS version 24) (IBM, Chicago, IL, USA). Student t-tests and Chi-square tests were used to compare outcomes between the two groups. Paired Student t-tests and McNemar's test were used to conduct intragroup analyses. Non-normally distributed data were analyzed using the Mann-Whitney or Wilcoxon signed-rank non-parametric tests for independent and paired samples, respectively. $p < 0.05$ was considered to be statistically significant.

RESULTS

The patients were anonymously assigned to either the EDB+B group or EDB group. Twenty-seven patients underwent EDB with biopsy and 36 patients underwent EDB. Patient demographic parameters are shown in Table 1; the patients in the groups were homogenous in age and gender ($p = 0.144$ and $p = 0.28$, respectively). We reported outcomes by symptom categories.

Vertigo control

The mean \pm SD cumulative number of vertigo spells in the 6 preoperative months was 12.61 ± 15.13 ($n = 27$) in the EDB+B group and 7.78 ± 6.95 ($n = 36$) in the EDB group, with no statistically significant difference ($p = 0.16$). The mean \pm SD number of vertigo spells since the previous visit to the clinic for the EDB + B group was 0.04 ± 0.2 at 1 week, 0.19 ± 0.69 at 1 month, and 0.46 ± 1.28 at 6 months postoperatively. Similarly, the number of vertigo spells in the EDB group was 0.03 ± 0.17 at 1 week, 0.11 ± 0.53 at 1 month, and 0.09 ± 0.38 at 6 months postoperatively. No statistically significant difference was noted for any follow-up visit with $p = 0.82$, $p = 0.62$, and $p = 0.18$ at 1 week, 1 month, and 6 months postoperatively, respectively. These results are shown in Figure 1. However, both groups showed significant improvement in vertigo control at 6 months postoperatively when compared to cumulative vertigo spells in the last 6 months before surgery ($p < 0.001$).

Aural Fullness

All patients suffered from aural fullness at the time of surgery, and symptoms persisted at 1 week postoperatively for virtually all patients in both groups: 100% for the EDB group and 92.6% for EDB+B group ($p = 0.42$). However, at the 1- and 6-month follow-up visits, the prevalence of aural fullness declined slightly in both groups, with no significant difference noted. At 1 month postoperatively, 83.3% of the EDB group patients complained of persistent aural fullness compared to the 81.5% of the EDB+B patients ($p = 1$). At 6 months post-

operatively, 75% of the EDB group patients reported persistent aural fullness compared to the 74.1% of the EDB+B group patients ($p = 1$). Results are shown in Figure 2. In both groups, the decline in the prevalence of aural fullness at 6 months postoperatively compared with that preoperatively was statistically significant ($p = 0.016$).

Tinnitus

All patients suffered from tinnitus at the time of surgery. There was no significant difference between the groups at any of the control visits. At 1 week postoperatively, 97.2% of the EDB group patients and 92.6% of the EDB+B groups patients reported tinnitus ($p = 1$). At 1 month postoperatively, tinnitus persisted in 92% of the EDB groups patients and in 89% of the EDB+B groups patients ($p = 1$). At 6 months postoperatively, 83% of the EDB group patients and 81.5% of the EDB+B group patients complained of tinnitus ($p = 1$). Results are shown in Figure 3. Within the groups and compared to that before surgery, tinnitus prevalence at 6 months postoperatively was significantly lower in the EDB group ($p = 0.03$) and not in the EDB+B group ($p = 0.065$). Although still prevalent, tinnitus was subjectively reported as less severe at 6 months postoperatively; scores were not assigned for severity in our follow-up notes and were therefore not reported here.

PTA (air conduction thresholds)

Before surgery, the mean PTA was 47.5 dB and 49.6 dB for the EDB and EDB+B groups, respectively ($p = 0.93$). At 1 week postoperatively, patients in both groups experienced a transient decline in auditory

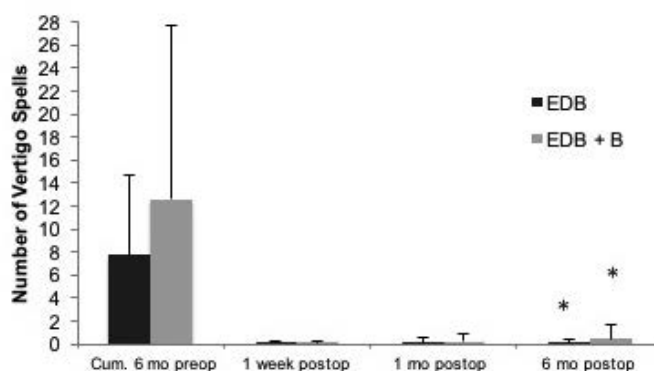


Figure 1. Vertigo control.

EDB: endolymphatic duct blockage surgery; EDB+B: endolymphatic duct blockage surgery with endolymphatic sac biopsy; cum.: cumulative; mo: months, preop: preoperative; postop: postoperative.

*Cumulative number of vertigo episodes compared that preoperatively: $p < 0.001$.

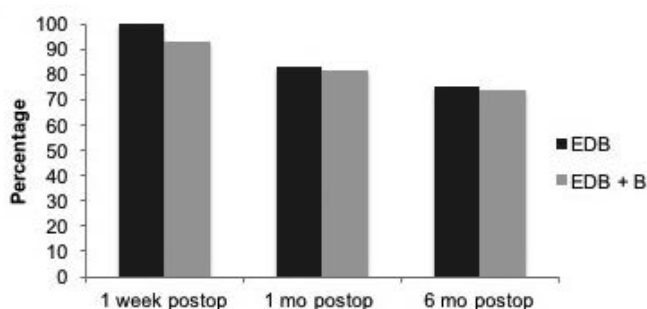


Figure 2. Aural fullness persistence.

EDB: endolymphatic duct blockage surgery; EDB+B: endolymphatic duct blockage surgery with endolymphatic sac biopsy; mo: months; postop: postoperative. Statistical significance was not reached between the groups.

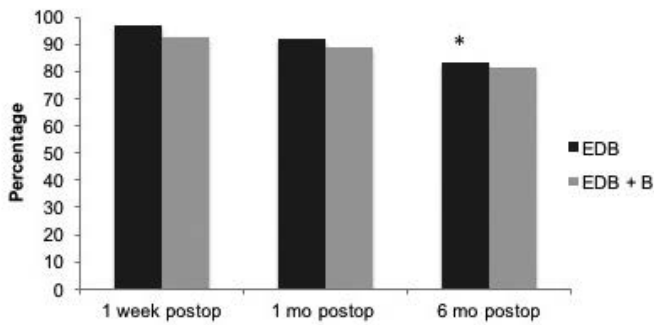


Figure 3. Tinnitus persistence.

EDB: endolymphatic duct blockage surgery; EDB+B: endolymphatic duct blockage surgery with endolymphatic sac biopsy; mo: months; postop: postoperative.

*In the EDB group only, the drop at 6 months postoperatively was significant ($p=0.016$).

function with a mean PTA of 67.41 dB in the EDB group and 73.2 dB in the EDB+B group, with no significant differences noted between them ($p=0.23$). The PTA improved slightly at 1 month post EDB in both groups: 63.7 dB for EDB versus 66.7 dB for EDB+B; no significant difference between the groups could be detected ($p=0.26$). By 6 months postoperatively, both groups had a mean PTA close to their preoperative levels: 51.64 dB and 57 dB in the EDB and EDB+B groups, respectively ($p=0.39$). PTAs for each follow-up visit are shown in Figure 4.

Although no statistically significant difference could be observed between our groups' mean PTAs at each visit, the initial drop in auditory function from preoperative levels followed by gradual recovery was significant for the individual groups at 6 months postoperatively: an increase of 4.12 dB in the EDB group ($p=0.037$) and an increase of 7.37 dB in the EDB+B group ($p=0.035$). These variations were not clinically significant (less than 10 dB).

BCTs

Before surgery, the mean BCT was 41.11 dB in the EDB group and 42.3 dB in the EDB+B group. In the EDB group, the mean BCT increased to 45.9 dB at 1 week, decreased to 42.5 dB at 1 month, and again decreased to 41 dB at 6 months postoperatively. In the EDB+B group, the mean BCT increased to 47.37 dB at 1 week and 48.1 dB at 1 month and then decreased to 42.13 dB at 6 months postoperatively. There was no significant difference between the groups at any visit, with p values of 0.77, 0.75, 0.29, and 0.66 for the preoperative visit and 1-week, 1-month, and 6-month postoperative follow-ups, respectively. There was also no significant difference within groups at 6 months postoperatively when compared to the preoperative levels (EDB: $p=0.54$; EDB+B: $p=0.81$). No sensorineural hearing loss was observed in our groups as shown in Figure 4.

SDSs

Before surgery, the mean SDSs were 64.6 % and 69.12 % for the EDB and EDB+B groups, respectively ($p=0.83$). In the EDB group, the mean SDS dropped to 53.13% at 1 week, increased to 65.13% at 1 month, and remained stable at 65.5% at 6 months postoperatively. In a similar fashion, the mean SDS for the EDB+B group patients dropped to 50.54 % at 1 week, increased to 50.79 % at 1 month, and increased again to 71.45 % at 6 months postoperatively. Figure 5 shows SDSs for both groups. p values were 0.49, 0.62, 0.21, and 0.44 for the preoperative visit and 1-week, 1-month, and 6-month postoperative follow-ups, respective-

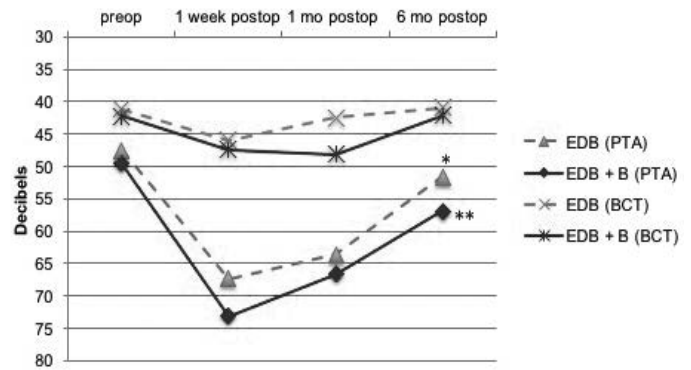


Figure 4. Pure tone average (air conduction) and bone conduction thresholds. EDB: endolymphatic duct blockage surgery; EDB+B: endolymphatic duct blockage surgery with endolymphatic sac biopsy; mo: months; preop: preoperative; postop: postoperative; PTA: pure tone average; BCT: bone conduction thresholds.

*The PTA in the EDB group 6 months postoperatively compared to that preoperatively ($p=0.037$).

**The PTA in the EDB+B group 6 months postoperatively compared to that preoperatively ($p=0.035$).

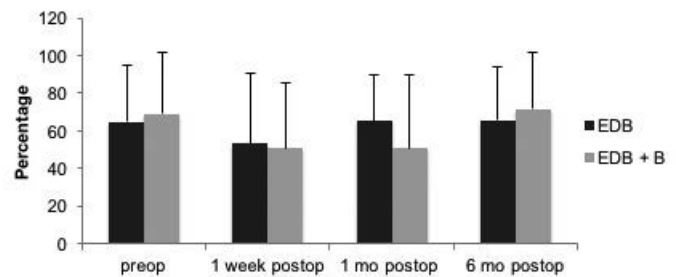


Figure 5. Speech discrimination scores (%).

EDB: endolymphatic duct blockage surgery; EDB+B: endolymphatic duct blockage surgery with endolymphatic sac biopsy; mo: months; preop: preoperative; postop: postoperative. Statistical significance was not reached between the groups.

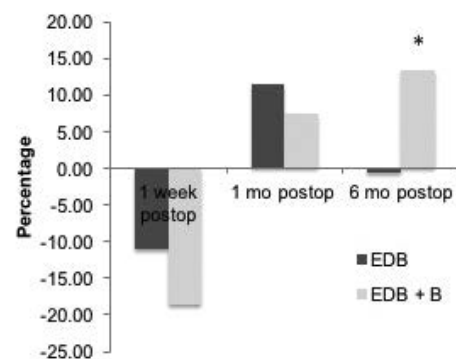


Figure 6. Speech discrimination scores (%) baseline variations from each visit. Levels were computed against the previous visit at each instance.

EDB: endolymphatic duct blockage surgery; EDB+B: endolymphatic duct blockage surgery with endolymphatic sac biopsy; mo: months; preop: preoperative; postop: postoperative. * $p=0.056$

ly. When compared within the groups, SDSs did not vary significantly from preoperative levels to 6 month postoperative levels: $p=0.28$ in the EDB group and $p=0.43$ in the EDB+B group. The above-described pattern with PTA characterized by early worsening and steady slow recovery was also noted with SDSs. Baselines variations from each visit are shown in Figure 6. We computed any differences in SDSs observed since the previous visit for each group separately and at each visit. We

then compared the mean variations between the groups. In the EDB group, the mean SDS dropped 11.1% at 1 week, recovered 11.5 % at 1 month, and remained stable with -0.5% at 6 months postoperatively. Likewise, in the EDB+B group, the mean SDS dropped 18.6% at 1 week and recovered 7.5 % at 1 month followed by a further 13.5% increase at 6 months postoperatively. *p* values for the comparison of variations were 0.62, 0.77, and 0.056 for 1-week, 1-month, and 6-month postoperative follow-ups, respectively. At 6 months postoperatively, the EDB+B group patients had a more pronounced improvement than the EDB group patients, making up for an apparent lag in recovery observed at earlier visits. Statistical significance was not reached.

BPPV and Intraoperative CSF Leaks

There was no significant difference in both postoperative BPPV and intraoperative CSF leaks between the groups. In total, 47.2% of the EDB group patients and 38.9% of the EDB+B group patients developed postoperative BPPV at the level of the posterior semicircular canal of the operated ear (*p*=0.42). Moreover, 39% of the EDB group patients and 40.7% of the EDB+B group patients developed intraoperative CSF leaks (*p*=0.88), which were managed as per the procedure described earlier.

DISCUSSION

Treatment for MD unresponsive to medical therapy remains a controversial subject among ENT surgeons. Studies in the literature report varying rates of vertigo control with different surgical techniques (Liu, 86%^[1]; Thomsen, 53%^[8]; Welling, 67%^[9]; Telischi, 81%^[13]; Brinson, 67%^[14]; Fukushima, 78%^[15]; Kitahara, 90%^[16]; and Durland, 37%^[17]). The success of surgical interventions may be time sensitive, particularly in the early phases of the disease, and may prove more useful in the fluctuating hearing phase than later in the natural course of MD^[18]. A safe and effective intervention that offers intractable MD patients a chance to control their life-altering symptoms while preserving hearing is a prospect that has escaped ENT surgeons since the first report on ESD surgery. Unfortunately, an objective comparison of all surgical techniques in ESD is unavailable in the literature. EDB surgery is a novel technique that we devised for treating intractable MD, with a considerable rate of success, particularly for vertigo control in the first 24 postoperative months^[12]. Aural fullness and tinnitus have been shown to be less prevalent after 24 months, along with preserved hearing, than classic decompression. Class A vertigo control is a feature of postoperative evolution following EDB and is the most desirable outcome for patients. In a previous study, there was significant improvement in the quality of life of patients after EDB surgery^[19]. One method that interested surgeons was endolymphatic mastoid shunting because of the theoretical benefit of evacuating the excess fluid out of the ELS. No study was able to prove that this method was superior to ESD; in fact, Brinson et al.^[14] found that both mastoid shunt and classic decompression were equally effective. The meta-analysis by Sood et al. also revealed that while shunting and decompression have a reported 75% long-term vertigo control, classic decompression was superior for hearing preservation^[11].

In the present study, we investigated the added effect of a more aggressive EDB surgery by the resection of the lateral part of the ELS after blocking the endolymphatic duct, which was required for a separate research effort to study the ELS histopathology. Our results showed that vertigo control is the same, irrespective of whether the patient was bi-

opsied. Patients who underwent biopsy had a similar rate of vertigo episodes preoperatively (*p*=0.16) and at 6 months postoperatively (*p*=0.18) than those who underwent EDB without biopsy, which suggests similar disease severity and favorable response to surgery. Because no significant difference could be detected, no added benefit could be attributed to opening the ELS during surgery for vertigo control and should not be avoided for this purpose. The prevalence of aural fullness in the early postoperative phase also remained unchanged between the groups. Tinnitus, however, only improved in the EDB group at 6 months postoperatively (*p*=0.03). This can be explained by postoperative blood and serum accumulation in the middle ear as well as intraoperative lavage fluid. These are resorbed later in the postoperative period. These findings mirror previously described data^[12] and can be expected to improve further over 24 months. The absence of significant differences in aural fullness suggests no benefits to a more aggressive approach to EDB with regards to the symptom. On the other hand, tinnitus was only significantly improved at 6 months in the EDB group, and this suggests that opening the ELS causes an increased incidence of the symptom or a delay in its resolution. Although not threatening to the patient's overall condition, opening the ELS constitutes an additional harm and should not be recommended. We can reasonably explain these findings: an incision into the ELS would cause more inflammation to heal the injury, resulting in prolonged effusions; this phenomenon is absent in a conventional EDB.

In our final assessment of surgical outcomes in the early postoperative period, our results describe a pattern of audiometry changes similar to previously reported fluctuations of PTAs and SDSs in our groups^[12]. No statistical difference was observed at any of the control visits, and this confirms that opening the sac neither benefits nor harms audition in any clinically significant way. Both groups exhibited a significant increase in PTAs at 6 months postoperatively (4.12 dB in the EDB group and 7.37 dB in the EDB+B group), but both were below 10 dB and were not clinical significant. Bone conduction was not affected in either group at any visit; no sensorineural hearing loss was observed as a result of EDB surgery with or without biopsy. We noticed a trend for a slower recovery of the initial worsening of SDSs in the biopsy group during the first month post EDB, followed by an accelerated recovery over the next few months to reach the same plateau of the preoperative auditory function levels similar to the EDB group. This may be explained by additional early-phase inflammatory changes around the labyrinth that resolve with natural healing. Our results also confirm that the success of symptom control should be attributed to the effective obstruction of the endolymphatic duct during EDB irrespective of the integrity of the main body of the ELS. Blocking the endolymphatic duct with two surgical clips separates the labyrinth from the ELS and effectively isolates cochlear endolymphatic circulation from the ELS fluid. It has been proposed in a pilot study that the ELS is the source of the pathology in MD, although its histopathology remains poorly understood^[12]. Cutting off the ELS from the rest of the cochlea has proven to be effective for symptom relief and protective for auditory function. The diseased sac cannot effectively transmit the increased flow pressure into the cochlea, thus improving symptoms associated with MD. This result was supported by Gibson who reported that ELS removal appeared to provide better relief from vertigo than a simple drainage procedure with less tendency for recurrence several months or years after the initial surgery^[20].

In our experience, other encountered complications were postoperative BPPV due to the close proximity to semi-circular canals during

surgery, which may result in accidental otolith displacement and intraoperative CSF leaks by damaging the thin petrous dura. The occurrence of these adverse events was not altered in our groups, and no other event specific to the ELS biopsy group was reported. We could not identify any added benefits to ELS opening during surgery; however, we identified a potential harm: an increased prevalence of tinnitus at 6 months postoperatively. We suggest that ELS sectioning for more aggressive decompression should not be recommended; EDB surgery is sufficient for symptom control. In other words, after blocking the endolymphatic duct with clips, there is no difference in vertigo outcome irrespective of whether the lateral wall of the ELS is taken out.

None of the patients in our study suffered from any severe adverse events such as meningitis, nerve injury, or recurrence of a CSF leak after intraoperative treatment. The present study confirmed that EDB surgery for the treatment of refractory MD is a safe and effective procedure that results in excellent vertigo control, stable tinnitus, and aural fullness, while maintaining stable auditory function with no significant increase in conductive hearing loss in the early 6-month postoperative period. Our pilot study on a randomized cohort has shown that symptoms improve further on long-term follow-up^[12]. EDB carries a higher risk (40%) of intraoperative CSF leaks than regular ESD surgery, but it can be effectively treated in the operating room during EDB surgery with no long-term sequelae and no increased risk of more severe complications.

Limitations of the Study

Our findings did not predict the long-term effects of intraoperative ELS sectioning on symptoms and hearing preservation. An additional limitation was found in data collection due to the retrospective design: aural fullness and tinnitus were only reported as absent or present. A more detailed description of these symptoms, including severity with a standardized symptom scoring system, would make for an interesting observation. However, it would however be unethical to make more patients undergo an extra procedure that appears to have no additional benefits to their disease management.

CONCLUSION

Endolymphatic duct blockage surgery has proven to be a safe and effective disease-modifying intervention for the treatment of refractory MD. The success of the surgery can be attributed to blocking the distal endolymphatic flow in the ELS at the level of the endolymphatic duct, rather than altering the fluid pressure in the main body of the ELS. Aggressive decompression measures such as sectioning the lateral part of the ELS body do not carry added benefits for short-term disease control while increasing the incidence of tinnitus and should not be recommended.

Ethics Committee Approval: Ethics committee approval was received for this study from the ethics committee of Montreal University Hospital Center (CHUM).

Informed Consent: Written informed consent was obtained from patients who participated in this study.

Peer-review: Externally peer-reviewed.

Author Contributions: Concept - I.S., M.H.A.; Design - I.S., M.H.A.; Supervision - I.S.; Resources - I.S., M.H.A.; Materials - I.S., M.H.A.; Data Collection and/or Processing - M.H.A.; Analysis and/or Interpretation - I.S., M.H.A.; Literature Search - I.S., M.H.A.; Writing Manuscript - M.H.A.; Critical Review - I.S.

Conflict of Interest: No conflict of interest was declared by the authors.

Financial Disclosure: The authors declared that this study has received no financial support.

REFERENCES

1. Liu F, Huang W, Chen Q, Meng X, Wang Z, He Y. Noninvasive evaluation of the effect of endolymphatic sac decompression in Ménière's disease using magnetic resonance imaging. *Acta Otolaryngol* 2014; 134: 666-71. [\[CrossRef\]](#)
2. Chung JW, Fayad J, Linthicum F, Ishiyama A, Merchant SN. Histopathology after endolymphatic sac surgery for Ménière's syndrome. *Otol Neurotol* 2011; 32: 660-4. [\[CrossRef\]](#)
3. Rauch SD. Clinical hints and precipitating factors in patients suffering from Ménière's disease. *Otolaryngol Clin North Am* 2010; 43: 1011-7. [\[CrossRef\]](#)
4. Ren H, Yin T, Lu Y, Kong W, Ren J. Intratympanic dexamethasone injections for refractory Meniere's disease. *Int J Clin Exp Med* 2015; 8: 6016-23.
5. Pullens B, Verschuur HP, Van benthem PP. Surgery for Ménière's disease. *Cochrane Database Syst Rev* 2013; 2: CD005395.
6. Ostrowski VB, Kartush JM. Endolymphatic sac-vein decompression for intractable Meniere's disease: long term treatment results. *Otolaryngol Head Neck Surg* 2003; 128: 550-9. [\[CrossRef\]](#)
7. Thomsen J, Bretlau P, Tos M, Johnsen NJ. Ménière's disease: endolymphatic sac decompression compared with sham (placebo) decompression. *Ann NY Acad Sci* 1981; 374: 820-30. [\[CrossRef\]](#)
8. Thomsen J, Bretlau P, Tos M, Johnsen NJ. Endolymphatic sac-mastoid shunt surgery. A nonspecific treatment modality?. *Ann Otol Rhinol Laryngol* 1986; 95: 32-5. [\[CrossRef\]](#)
9. Welling DB, Nagaraja HN. Endolymphatic mastoid shunt: a reevaluation of efficacy. *Otolaryngol Head Neck Surg* 2000; 122: 340-5. [\[CrossRef\]](#)
10. Lim MY, Zhang M, Yuen HW, Leong JL. Current evidence for endolymphatic sac surgery in the treatment of Meniere's disease: a systematic review. *Singapore Med J* 2015; 56: 593-8. [\[CrossRef\]](#)
11. Sood AJ, Lambert PR, Nguyen SA, Meyer TA. Endolymphatic sac surgery for Ménière's disease: a systematic review and meta-analysis. *Otol Neurotol* 2014; 35: 1033-45. [\[CrossRef\]](#)
12. Saliba I, Gabra N, Alzahrani M, Berbiche D. Endolymphatic duct blockage: a randomized controlled trial of a novel surgical technique for Ménière's disease treatment. *Otolaryngol Head Neck Surg* 2015; 152: 122-9. [\[CrossRef\]](#)
13. Telischi FF, Luxford WM. Long-term efficacy of endolymphatic sac surgery for vertigo in Meniere's disease. *Otolaryngol Head Neck Surg* 1993; 109: 83-7.
14. Brinson GM, Chen DA, Arriaga MA. Endolymphatic mastoid shunt versus endolymphatic sac decompression for Ménière's disease. *Otolaryngol Head Neck Surg* 2007; 136: 415-21. [\[CrossRef\]](#)
15. Fukushima M, Kitahara T, Horii A, Inohara H. Effects of endolymphatic sac decompression surgery on endolymphatic hydrops. *Acta Otolaryngol* 2013; 133: 1292-6. [\[CrossRef\]](#)
16. Kitahara T, Horii A, Imai T, Ohta Y, Morihana T, Inohara H, et al. Effects of endolymphatic sac decompression surgery on vertigo and hearing in patients with bilateral Ménière's disease. *Otol Neurotol* 2014; 35: 1852-7. [\[CrossRef\]](#)
17. Durland WF, Pyle GM, Connor NP. Endolymphatic sac decompression as a treatment for Meniere's disease. *Laryngoscope* 2005; 115: 1454-7. [\[CrossRef\]](#)
18. Brown JS. A ten-year statistical follow-up of 245 consecutive cases of endolymphatic shunt and decompression with 328 consecutive cases of labyrinthectomy. *Laryngoscope* 1983; 93: 1419-24.
19. Gabra N, Asmar MH, Berbiche D, Saliba I. Endolymphatic duct blockage: quality of life assessment of a novel surgical technique for Ménière disease. *Eur Arch Otorhinolaryngol* 2016; 273: 2965-73. [\[CrossRef\]](#)
20. Gibson WP. The effect of surgical removal of the extraosseous portion of the endolymphatic sac in patients suffering from Meniere's disease. *J Laryngol Otol* 1996; 110: 1008-11. [\[CrossRef\]](#)