



Original Article

Surgical Treatment of External Auditory Canal Cholesteatoma – Ten Years of Clinical Experience

Kuen-Yao Ho, Tzu-Yen Huang, Shih-Meng Tsai, Hsun-Mo Wang, Chen-Yu Chien, Ning Chia Chang

Department of Otolaryngology, Kaohsiung Medical University Hospital, Taiwan (KYH, TYH)

Department of Otolaryngology, Faculty of Medicine, College of Medicine, Kaohsiung Medical University, Taiwan (KYH, CYC, NCC)

Department of Public Health, Faculty of Medicine, College of Medicine, Kaohsiung Medical University, Taiwan (SMT)

Department of Otolaryngology, Kaohsiung Municipal Ta-Tung Hospital, Taiwan (HMW)

Department of Otolaryngology, Kaohsiung Municipal Hsiao-Kang Hospital, Taiwan (CYC)

Department of Prevention, Kaohsiung Municipal Hsiao-Kang Hospital, Taiwan (NCC)

OBJECTIVE: To describe the clinical manifestations of external auditory canal (EAC) cholesteatoma and evaluate the surgical outcomes of reconstruction using an inferior pedicled soft-tissue periosteum flap.

MATERIALS and METHODS: A total of 28 patients were enrolled in this retrospective study conducted at Kaohsiung Medical University Hospital in Taiwan between January 2004 and December 2013. EAC cholesteatoma was classified according to the disease extent. The surgery was performed to reconstruct a smooth contour of EAC.

RESULTS: The average age of the 28 patients (9 males and 19 females; 30 surgical ears) was 53.7 years. The most common clinical manifestations were unilateral otalgia (63.3%) and otorrhea (46.7%), and the most frequent locations of EAC cholesteatoma with bony invasion were the posterior–inferior (40%), inferior (30%), posterior (20%), and posterior–inferior–anterior (10%) aspects. Based on Naim's staging systems of EAC cholesteatoma, 26 ears (86.7%) were classified as stage III and 4 ears (13.3%) as stage IV. All patients received surgical management via a postauricular approach, and the average length of postoperative follow-up was 61.5 months (range 8–131 months). One patient had recurrence after surgery for 1 year 3 months.

CONCLUSION: Bony canaloplasty and obliteration with an inferior pedicled soft-tissue periosteum flap is a reliable procedure for EAC cholesteatoma.

KEYWORDS: External auditory canal, cholesteatoma, surgery

INTRODUCTION

External auditory canal (EAC) cholesteatoma is a lesion lined with stratified squamous epithelium containing proliferative keratin with bony erosion. It is an uncommon benign disease with an unclear etiology and pathogenesis. Some authors have reported that EAC cholesteatoma is a result of trauma to EAC, chronic inflammation, ear canal stenosis, or that it arises spontaneously^[1, 2]. Symptoms of EAC cholesteatoma are indolent and nonspecific. Patients with EAC cholesteatoma commonly complain of unilateral otorrhea and otalgia; however, unilateral hearing impairment has rarely been reported^[3, 4].

The locally invasive expansion of EAC cholesteatoma can cause the destruction of the adjacent structures, and if the mastoid cavity is invaded, facial nerve paralysis and labyrinthine fistula can occur^[3, 5, 6]. Destruction through the anterior wall of EAC can affect the temporal–mandibular joint^[1], and advanced invasion of the skull base can induce meningitis or an intracranial abscess^[7]. The mechanism of bony destruction in cholesteatoma remains unclear; however, most hypotheses of bony destruction or resorption in cholesteatoma involve pressure necrosis, osteolysis, and/or contact between the inflammatory granulation tissue and bone, which then causes enzymatic bony destruction^[8, 9]. The aim of this study was to describe the clinical manifestations of EAC cholesteatoma and to present our experience of surgical management in such patients.

MATERIALS and METHODS

A total of 28 patients (30 surgical ears) were enrolled from January 2004 to December 2013. All patients underwent a detailed medical examination, medical history review, and a battery of tests including pure tone audiometry and high-resolution computed tomography (CT) of the temporal bone. This study was approved by the institutional review board.

Staging of EAC Cholesteatoma

The severity and staging of EAC cholesteatoma was based on the criteria proposed by Naim et al. [1] in 2005 and was based on the clinical presentation and level of destruction of the temporal bone (Table 1). Invasion was limited to the epithelium of EAC at an early stage. However, destruction of the bony ear canal or adjacent structures was at a late stage.

Operative Procedures for EAC Cholesteatoma

Every patient underwent eradication surgery with external auditory canaloplasty under general anesthesia. Surgery was performed based on the staging of EAC cholesteatoma and was first assessed using high-resolution temporal bone CT (Figure 1). The procedures were performed in a number of steps. First, 2% lidocaine with 1:100000 epinephrine was injected over the postauricular area, and after a few minutes, a postauricular incision was made. Subcutaneous and areolar tissues were then carefully dissected to identify the temporalis muscle fascia, after which a piece of temporalis fascia was harvested and compressed for reconstruction. The posterior flap was raised and Henle’s spine identified and then a horizontal incision was made to approach the external canal. Subsequently, the extensive area of EAC cholesteatoma was identified and eradication was performed. To preserve a normal ear canal contour, irregular margins of the bony wall were smoothly drilled out (Figure 2). The inferior pedicled soft-tissue periosteal flap was harvested for the reconstruction of the external auditory contour, and canaloplasty was performed with the obliterating flap in the cholesteatoma cavity. During the canaloplasty, the temporalis fascia was placed under the skin of EAC and the inferior pedicled soft-tissue periosteal flap was placed under the fascia to fill the residual cavity after drilling the bone erosion to create a smooth ear canal contour (Figure 3). The final step of bony reconstruction was to set the inferior pedicled soft-tissue periosteal flap, temporalis fascia, and the full-thickness skin graft layer by layer.

Statistical analyses were conducted using Excel 2013 (Microsoft Corp., Redmond, WA, USA).

RESULTS

This was a retrospective study, and all patients received eradication of a cholesteatoma sac and reconstructive canaloplasty. Of the 28 patients (30 surgical ears), 9 (9 ears) were males and 19 (21 ears) were females, with mean ages of 53.7 (range 18–74) and 53.7 (range 22–83) years, respectively. There were 11 right and 19 left ears, and two of the females had previously undergone bilateral ear surgery. The most common clinical manifestations were unilateral otalgia (19 ears, 63.3%) and otorrhea (14 ears, 46.7%), followed by ear fullness (10 ears, 33.3%), tinnitus (5 ears, 16.7%), and hearing loss (4 ears, 13.3%). Four of the surgical ears (13.3%) were asymptomatic and incidentally discovered during otoscopy. The most frequent locations of EAC cholesteatoma with bony invasion were the posterior–inferior (12 ears, 40%), inferior (9 ears, 30%), posterior (6 ears, 20%), and posterior–inferior–anterior (3 ears, 10%) aspects. EAC cholesteatoma was staged using the classification as proposed by Naim et al. [1]; 26 ears (86.7%) were stage III and 4 ears (13.3%) were stage IV (Table 2). All patients received surgical management via a postauricular inlet, and the average length of postoperative follow-up was 61.5 months (range 8–131 months). One ear suffered from recurrence after surgery for 1 year 3 months. Pre and postoperative pure tone audiome-

try were performed in selected cases; there was no specific threshold change noted in these patients.

Case Presentation

A 40-year-old female suffered from right-sided otalgia and otorrhea for 6 months. Medical management at a local clinic with topical and systemic antibiotics combined with regular local treatment was successful. However, she was referred to our hospital for a further opinion, and otoscopy revealed erosions in the posterior and inferior aspects of EAC that contained bony debris and sequestra. A CT scan confirmed a soft-tissue mass with bony destruction in the inferior portion of EAC (Figure 4a). She underwent surgery to remove the EAC cholesteatoma and canaloplasty through the postauricular approach. The shape of the EAC wall was found to have healed well after 6 months of follow-up (Figure 4b).

DISCUSSION

Cholesteatoma is commonly found in the middle ear and mastoid cavity, with a reported annual incidence rate of 9.2 cases per 100000 individuals [10]. However, EAC cholesteatoma is rare, with a reported incidence rate of approximately 1.2–3.7 per 1000 otological patients [6, 11]. The annual incidence of EAC cholesteatoma has been reported to be approximately 0.15 cases per 100000 persons [10].

The etiology and pathogenesis of EAC cholesteatoma are unclear. In general, the narrowing or occlusion of EAC is believed to be responsible. Holt [2] proposed multiple etiologies, such as previous ear surgery/trauma, congenital ear canal stenosis/obstruction, or spontaneous formation. The formation of EAC cholesteatoma is consid-

Table 1. External auditory canal cholesteatoma: The classification was proposed by Naim et al. [1]

Stage I	Hyperplasia and hyperemia of the auditory meatal epithelium
Stage II	No destruction of the bony canal. Accumulation of keratin debris
	a. Intact epithelial surface
	b. Excavation of the defective epithelium with apparent bony canal
Stage III	Destruction of the bony canal with sequestered bone
Stage IV	Destruction of the adjacent anatomical structures
	Subclass M: Mastoid
	Subclass S Skull base with sigmoid sinus
	Subclass J: Temporal–mandibular joint
	Subclass F: Facial nerve

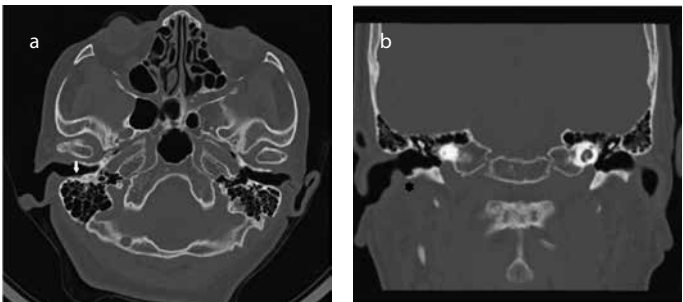


Figure 1. a, b. A 68-year-old female. High-resolution computed tomography revealed soft-tissue density material (a, arrow) with bony destruction (b,*) in the external auditory canal.

Table 2. Summary of reported cases with external auditory canal cholesteatoma

Case	Age (years)	Sex	Side	Location	Otalgia	Otorrhea	Hearing loss	Tinnitus	Ear fullness	Anatomical invasion	Naim's stage
1	25	M	R	Post	+	+	–	–	+	Mastoid	IV
2	35	F	L	Post & Inf	–	+	–	–	–	Excavation	III
3	60	M	R	Post	–	+	+	+	+	Mastoid	IV
4	53	M	L	Post & Inf & Ant	+	+	–	–	+	Excavation	III
5	67	M	L	Post & Inf & Ant	–	+	–	+	+	EAC erosion	III
6	75	F	L	Inf	+	–	–	–	–	Excavation	III
7	62	M	R	Post	+	+	–	–	–	Mastoid	IV
8	59	M	L	Post	–	–	–	–	+	EAC erosion	III
9	69	F	L	Inf	+	+	–	–	–	EAC erosion	III
10	81	F	L	Post & Inf	–	+	–	+	+	EAC erosion	III
11	22	F	L	Post & Inf	–	+	+	+	+	Mastoid	IV
12	40	F	R	Post & Inf	+	+	–	–	–	EAC erosion	III
13	37	F	L	Post & Inf	+	+	–	+	+	EAC erosion	III
14	78	F	L	Inf	+	–	–	–	–	EAC erosion	III
15	18	M	R	Inf	–	+	–	–	–	EAC erosion	III
16	31	F	L	Post & Inf	+	–	–	–	–	EAC erosion	III
17	74	M	R	Inf	+	–	–	–	–	EAC erosion	III
18	38	F	BR	Post & Inf	–	–	–	–	–	EAC erosion	III
			BL	Post & Inf	–	–	–	–	–	EAC erosion	III
19	49	F	L	Post & Inf & Ant	+	–	–	–	–	EAC erosion	III
20	79	F	L	Post & Inf	+	–	–	–	–	EAC erosion	III
21	79	F	L	Post	+	–	+	–	+	EAC erosion	III
22	33	F	L	Post & Inf	+	+	–	–	–	EAC erosion	III
23	65	M	R	Inf	+	–	–	–	+	EAC erosion	III
24	20	F	L	Inf	+	+	–	–	–	EAC erosion	III
25	83	F	L	Post & Inf	+	–	–	–	–	EAC erosion	III
26	30	F	R	Post & Inf	–	–	–	–	–	EAC erosion	III
27	67	F	BL	Post	–	–	–	–	–	EAC erosion	III
			BR	Inf	+	–	+	–	–	EAC erosion	III
28	75	F	R	Inf	+	–	–	–	–	EAC erosion	III

EAC: external auditory canal; M: male; F: female; R: right; L: left; B: bilateral; Post: posterior; Inf: inferior; Ant: anterior

ered to be via “keratinization in situ,” which is a reduction in migratory capacity of epithelium [1, 3, 6, 12]. Same as the vascular distribution, the direction of epithelial migration is outward from the manubrium of malleus to annulus [1]. Makino and Amatsu [12] reported that the migratory rate of the epithelium was the highest over the inferior wall and described the poor blood supply as hypoxia. Most cases of EAC cholesteatoma occur in the inferior wall, as seen in our series (24/30 ears, 80%).

Other medical problems affecting blood circulation can also cause EAC cholesteatoma, such as diabetes mellitus, heavy smoking, and repeated microtrauma [4, 13]. Some authors have also proposed that syphilis, scarlet fever, and rheumatoid arthritis can also cause EAC cholesteatoma [1]. More female patients had EAC cholesteatoma in

our study (19/28), which is in agreement with other studies [1, 14]. However, these studies have only included a small number of cases of EAC cholesteatoma, and future studies should include more cases with a long follow-up period.

The manifestations of EAC cholesteatoma include accumulation of keratin debris and bony destruction as inflammation progresses. The most common symptoms are unilateral otalgia and hearing loss, followed by otorrhea and tinnitus [15]. However, one metaanalysis of EAC cholesteatoma reported that unilateral otorrhea with otalgia was the most common symptom, followed by hearing impairment [4]. In our study, the most common manifestations were unilateral otalgia (19 ears, 63.3%) and otorrhea (14 ears, 46.7%), with relatively fewer patients complaining of ear fullness (10 ears, 33.3%), tinnitus (5 ears,

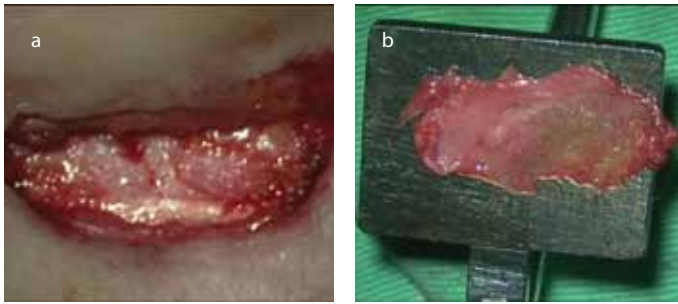


Figure 2. a, b. The cholesteatoma sac with bony erosion in the right ear canal was identified and elevated to allow for careful excision (a, arrow). A smooth contour of the external auditory canal was created by drilling bony irregularities and ridges (b, *).

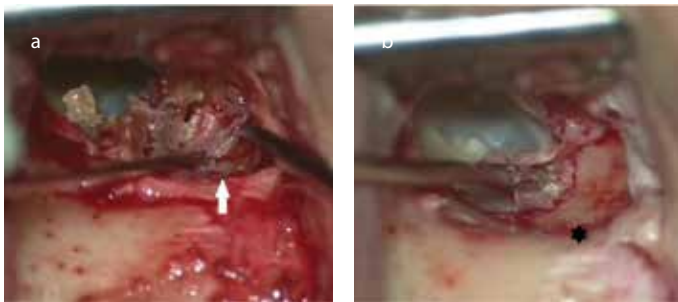


Figure 3. a, b. An inferior pedicled soft-tissue periosteal flap was harvested (a, arrow). Canaloplasty was performed using the obliterating flap in the cholesteatoma cavity (b, *: temporalis fascia).

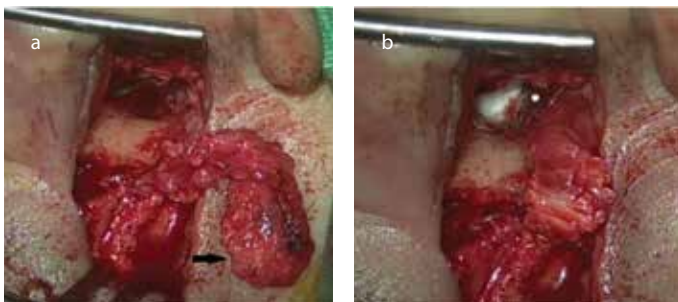


Figure 4. a, b. Coronal computed tomography confirmed the soft-tissue mass with bony destruction in the inferior portion of the external auditory canal (a, *). The shape of the canal wall healed well after surgery with canaloplasty after 6 months of follow-up (b).

16.7%), and hearing loss (4 ears, 13.3%). Four ears (13.3%) were asymptomatic and incidentally discovered during otoscopic examinations.

External auditory canal cholesteatoma can be limited to the epithelium without bony invasion, in which case keratin debris and epithelial hyperplasia are found during otoscopy. However, the bony destruction of EAC and involvement of adjacent structures can occur in advanced diseases. If EAC cholesteatoma invades the mastoid cavity, it may damage the fallopian canal, semicircular canals, and sigmoid sinus [3, 5, 6]. The temporal-mandibular joint would then be affected through the anterior aspect of EAC [6, 15, 16]. In addition, rare cases of skull base invasion have been reported in advanced diseases [7].

Clinical examinations alone are not sufficient to accurately detect the spread of EAC cholesteatoma to the mastoid cavity and adjacent

structures. Currently, high-resolution CT of the temporal bones is the gold standard to assess lesions and make decisions for the treatment of EAC cholesteatoma [3, 17]. In temporal bone CT, EAC cholesteatoma is shown as a soft-tissue tumor within the auditory canal, bony invasion, or destructions of the middle ear and adjacent structures [5, 18]. All our cases received high-resolution CT of the temporal bone to detect lesions and guide management.

Temporal bone CT also plays an important role in the diagnosis and extension of EAC cholesteatoma. However, soft-tissue abnormalities in EAC can include atresia, edema, hemorrhage, keratosis obturans, cholesteatoma, adenoma, ceruminoma, fibroma, mixed tumors, as well as squamous cell, basal cell, and adenocystic carcinoma [18]. Naim et al. [11] recommended performing routine histological investigations of operative specimens to rule out malignancy in EAC cholesteatoma. They reported two patients with EAC tumors, who had persistent otorrhea and similar clinical presentations to EAC cholesteatoma. In these cases, squamous cell carcinoma was diagnosed with histological analysis [11]. In our study, each surgical specimen was pathological-examined and then diagnosed with EAC cholesteatoma.

External auditory canal cholesteatoma was staged using the classification as proposed by Naim et al., [11] which is based on pathological, clinical, and radiological evidence (Table 1). In the earlier stages (stages I and II), there is no destruction of the bony canal, whereas bony destruction of EAC and involvement of adjacent structures are seen in advanced stages (stages III and IV). In our study, all surgical cases were at advanced stages [26 ears (86.7%) stage III, 4 ears (13.3%) stage IV].

With regards to the management of EAC cholesteatoma, the main goal is the same as that for middle ear cholesteatoma. It is very important to eradicate the cholesteatoma and preserve normal structures as far as possible to restore epithelial migration in EAC. In earlier stages, EAC cholesteatoma without bony destruction should be conservatively treated. The first choice of therapy is to remove keratin debris and locally apply gauze with salicylate and cortisone ointment [1, 11]. If these procedures are not sufficient to control the clinical symptoms, or the patients have the advanced stage with the destruction of the bony canal or adjacent anatomical structures, surgery should be considered. The goal of surgery is to excise defective areas with a clear margin of epithelium and carefully remove eroded skin and destroyed bone. The irregular bony surface should then be saucerized using a diamond burr to achieve a smooth contour. Some studies have proposed surgical techniques to fill the bony defects, such as a soft-tissue flap, ear conchal cartilage, and temporalis [11, 19, 20].

In large defects of EAC and mastoid cavity, Tos [21] recommended obliteration with an inferior-based subcutis muscle periosteum flap, harvested along the posterior edge of the auricular incision. Some authors have suggested using bone with perichondrium for reconstruction [22]. Anthony and Anthony [11] reported the use of two surgical techniques to manage EAC cholesteatoma. First, careful removal of the EAC cholesteatoma with one to two margins of normal epithelium was performed, followed by smoothing and saucerizing the bony contour. Second, set harvested normal skin over the exposed bony defect, and then fill EAC with Gelform®.

Based on the satisfactory removal of the EAC cholesteatoma and reconstruction of defects, we modified the procedures suggested by Anthony in our patients. After eradicating the EAC cholesteatoma, the irregular bony wall was drilled out using a diamond burr, and canaloplasty with an inferior pedicled soft-tissue periosteal flap was performed to obliterate the EAC defect. Finally, EAC reconstruction was completed with the inferior pedicled soft-tissue periosteal flap, temporalis fascia, the full-thickness skin graft, and then packing with Gelform® layer by layer.

In conclusion, EAC cholesteatoma is an uncommon benign disease with multiple etiologies and pathogeneses. The clinical manifestations are not usually obvious, and most patients suffer from advanced disease requiring further consultation. Such patients require surgical managements. In our clinical experience of treating patients with EAC cholesteatoma, canaloplasty and obliteration with an inferior pedicled soft-tissue periosteum flap was a reliable procedure.

Ethics Committee Approval: Ethics committee approval was received for this study from the ethics committee of KMHIRB-E(II)-20160161.

Informed Consent: Written informed consent was obtained from patients who participated in this study.

Peer-review: Externally peer-reviewed.

Author Contributions: Concept - K.Y.H.; Design - K.Y.H.; Supervision - S.M.T.; Materials - C.Y.C., N.C.C.; Data Collection and/or Processing - T.Y.H.; Analysis and/or Interpretation - H.M.W.; Literature Search - H.M.W.; Writing Manuscript - K.Y.H.

Acknowledgements: The authors thank the help from the colleagues of Department of Otolaryngology, Kaohsiung Medical University Hospital.

Conflict of Interest: No conflict of interest was declared by the authors.

Financial Disclosure: The authors declared that this study has received no financial support.

REFERENCES

- Naim R, Linthicum F Jr, Shen T, Bran G, Hormann K. Classification of the external auditory canal cholesteatoma. *Laryngoscope* 2005; 115: 455-60. [\[CrossRef\]](#)
- Holt JJ. Ear canal cholesteatoma. *Laryngoscope* 1992; 102: 608-13. [\[CrossRef\]](#)
- Sayles M, Kamel HA, Fahmy FF. Operative management of external auditory canal cholesteatoma: case series and literature review. *J Laryngol Otol* 2013; 127: 859-66. [\[CrossRef\]](#)
- Dubach P, Mantokoudis G, Caversaccio M. Ear canal cholesteatoma: meta-analysis of clinical characteristics with update on classification, staging and treatment. *Curr Opin Otolaryngol Head Neck Surg* 2010; 18: 369-76. [\[CrossRef\]](#)
- Heilbrun ME, Salzman KL, Glastonbury CM, Harnsberger HR, Kennedy RJ, Shelton C. External auditory canal cholesteatoma: clinical and imaging spectrum. *AJNR Am J Neuroradiol* 2003; 24: 751-6.
- Owen HH, Rosborg J, Gaihede M. Cholesteatoma of the external ear canal: etiological factors, symptoms and clinical findings in a series of 48 cases. *BMC Ear Nose Throat Disord* 2006; 6: 16. [\[CrossRef\]](#)
- Martin DW, Selesnick SH, Parisier SC. External auditory canal cholesteatoma with erosion into the mastoid. *Otolaryngol Head Neck Surg* 1999; 121: 298-300. [\[CrossRef\]](#)
- Selesnick SH, Lynn-Macrae AG. The incidence of facial nerve dehiscence at surgery for cholesteatoma. *Otol Neurotol* 2001; 22: 129-32. [\[CrossRef\]](#)
- Uno Y, Saito R. Bone resorption in human cholesteatoma: morphological study with scanning electron microscopy. *Ann Otol Rhinol Laryngol* 1995; 104: 463-8. [\[CrossRef\]](#)
- Kemppainen HO, Puhakka HJ, Laippala PJ, Sipila MM, Manninen MP, Karma PH. Epidemiology and aetiology of middle ear cholesteatoma. *Acta Otolaryngol* 1999; 119: 568-72. [\[CrossRef\]](#)
- Anthony PF, Anthony WP. Surgical treatment of external auditory canal cholesteatoma. *Laryngoscope* 1982; 92: 70-75. [\[CrossRef\]](#)
- Makino K, Amatsu M. Epithelial migration on the tympanic membrane and external canal. *Arch Otorhinolaryngol* 1986; 243: 39-42. [\[CrossRef\]](#)
- Dubach P, Hausler R. External auditory canal cholesteatoma: reassessment of and amendments to its categorization, pathogenesis, and treatment in 34 patients. *Otol Neurotol* 2008; 29: 941-8. [\[CrossRef\]](#)
- Okuda T, Nagai N, Nakanishi H, Matsuda K, Tono T. Tentative plan for classification of progression degree of external auditory canal cholesteatoma: EACC based on clinical evidence. *Otol Jpn* 2014; 21: 175-80.
- Darr EA, Linstrom CJ. Conservative management of advanced external auditory canal cholesteatoma. *Otolaryngol Head Neck Surg* 2010; 142: 278-80. [\[CrossRef\]](#)
- Garin P, Degols JC, Delos M. External auditory canal cholesteatoma. *Arch Otolaryngol Head Neck Surg* 1997; 123: 62-5. [\[CrossRef\]](#)
- Shin SH, Shim JH, Lee HK. Classification of external auditory canal cholesteatoma by computed tomography. *Clin Exp Otorhinolaryngol* 2010; 3: 24-6. [\[CrossRef\]](#)
- Chakeres DW, Kapila A, LaMasters D. Soft-tissue abnormalities of the external auditory canal: subject review of CT findings. *Radiology* 1985; 156: 105-9. [\[CrossRef\]](#)
- Piepergerdes MC, Kramer BM, Behnke EE. Keratosis obturans and external auditory canal cholesteatoma. *Laryngoscope* 1980; 90: 383-91. [\[CrossRef\]](#)
- Bhide AR, Kale RV, Tepan MG, Pandit MS, Raleraskar AR. An extensive cholesteatoma of the external ear. Case report. *J Laryngol Otol* 1973; 87: 705-8. [\[CrossRef\]](#)
- Tos M. *Manual of Middle Ear Surgery*, 1st ed. New York: Georg Thieme Verlag, 1997.
- Naiberg J, Berger G, Hawke M. The pathologic features of keratosis obturans and cholesteatoma of the external auditory canal. *Arch Otolaryngol* 1984; 110: 690-3. [\[CrossRef\]](#)