



Case Report

Surgical Treatment for Epstein–Barr Virus Otomastoiditis Complicated by Facial Nerve Paralysis: A Case Report of Two Young Brothers and Review of Literature

Evelien van Eeten, Hubert Faber, Dirk Kunst

Department of Otolaryngology, Radboud University Medical Center, Nijmegen, Netherlands

We report the case of two young brothers with Epstein–Barr virus (EBV) otomastoiditis complicated by a facial nerve paralysis. The boys, aged 7 months (patient A) and 2 years and 8 months (patient B), were diagnosed with a facial nerve paralysis House–Brackmann (HB) grade IV (A) and V (B). After unsuccessful pharmacological treatment, patient A underwent mastoidectomy and atticotomy and patient B underwent a transmastoidal surgical decompression of the facial nerve. They recovered to HB grades I and II facial nerve palsy (FNP), respectively. Although rare and relatively unknown, EBV should be considered in the differential diagnosis of children with FNP of unknown cause. Surgical intervention may be a viable therapy with good recovery.

KEYWORDS: Facial paralysis, otitis media, Epstein–Barr virus infections, surgical decompression

INTRODUCTION

The cause of acquired facial nerve palsy (FNP) in the pediatric population can be classified as infectious, traumatic, malignancy associated, hypertension associated, and idiopathic (Bell's palsy) (Table 1). Toddlers and preteenagers may be at higher risk for FNP because of infectious and traumatic causes^[1].

The main pathogens causing FNP in children are *Borrelia burgdorferi* (50%), idiopathic or Bell's palsy (26%), otitis media (OM) (12%), varicella-zoster virus (6%), Herpes simplex virus (4%), and coxsackie (2%)^[2]. A thorough research of the literature showed that although rare, Epstein–Barr virus (EBV) can also be linked to FNP^[3, 4]. Here we present the case of two brothers with an EBV-derived unilateral FNP.

CASE PRESENTATION

A 7-month-old boy (patient A) without previous otologic history was referred to our Ear Nose Throat tertiary referral center for the evaluation of a left-sided unilateral FNP that developed after 2 days of fever. A ventilation tube (VT) was placed in the referring hospital 2 days earlier because of signs of OM with effusion. On examination in our hospital 4 days after onset, House–Brackmann (HB)^[5] score grade IV (Table 2), hepatosplenomegaly, and bilateral enlarged cervical glands were observed. Otoscopy showed VT with clear otorrhea, without clinical signs of mastoiditis. A polymerase chain reaction (PCR) on EBV was conducted and confirmed an acute EBV infection.

Contrast-enhanced computed tomographic (cCT) scan (Aquilion ONE VISION Edition; Toshiba Medical Systems, Otawara, Japan) demonstrated opacification of the mastoid and middle ear as seen in otomastoiditis. Contrast-enhanced magnetic resonance imaging (cMRI) scan (Siemens Avanto 1.5T, Erlangen, Germany) demonstrated otitis media and mastoiditis, particularly around the apex pars petrosae, with signs of abscess formation. From the day of onset, the patient was pharmacologically treated for 2 days with azithromycin (Zithromax by Pfizer BV, New York City, United States of America), followed by 2 days of ceftriaxone and simultaneously for 7 days with eardrops consisting hydrocortisone, colistin, and bacitracin (Bacicoline-B by Daleco Pharma BV, Enspijk, The Netherlands).

Based on the diagnosis of EBV-induced mastoiditis complicated by FNP that did not improve with antibiotic treatment, mastoidectomy and atticotomy were performed 6 days after onset of FNP. Granulation tissue from the mastoid was positive for EBV.

Corresponding Address: Hubert Faber E-mail: FaberH@zgv.nl

Submitted: 26.06.2016

Revision received: 11.11.2016

Accepted: 08.02.2017

©Copyright 2017 by The European Academy of Otolology and Neurotology and The Politzer Society - Available online at www.advancedotology.org

Table 1. Causes of facial nerve palsy in children ^[1,3]

Genetic	Fascioscapulohumeral dystrophy
	Myotonic dystrophy
	Myasthenic syndromes
Congenital	Arnold Chiari syndrome
	Cardiofacial syndrome
	Facial nerve malformations
Trauma	Birth trauma
	Temporal bone fracture
	Increased intracranial pressure
	Iatrogenic trauma
Infectious	Lyme disease
	Herpes simplex virus
	Varicella virus
	Otitis media and mastoiditis
	Tuberculosis
	Parotitis
	Mycoplasma pneumoniae infection
	Guillain-Barré syndrome
	Epstein-Barr infection
	Ramsay Hunt syndrome
	Miller Fisher syndrome
	Vasculitis
	Sarcoidosis
Neoplasms	Brain stem glioma
	Parotid tumor
	Leukemia
Metabolic	Diabetes mellitus
	Hyperparathyroidism
	Hypothyroidism
Other	Hypertension-associated hemophilia
Idiopathic	Bell's palsy

After the surgical treatment, patient A clinically recovered to a HB II, with minimal asymmetry and eye closure after 1 month, and HB I 6 months later.

Two months later, his brother (patient B), aged 2 years and 8 months, showed a left-sided unilateral FNP grade V HB. FNP was preceded by 2 days of otalgia and fever. A secondary referral center placed a VT that showed thickened mucosa without signs of acute OM. He only had a medical history of adenotonsillectomy because of obstructive sleep apnea syndrome.

Polymerase chain reaction on EBV that was conducted considering the disease course of his brother indicated an acute EBV infection. cCT showed otomastoiditis, with complete opacification of the mastoid and middle ear. cMRI showed slight coloration of the geniculate ganglion on the tympanal and mastoidal part of the facial nerve (Figure 1). Otoacoustic emission test reported bilateral normal inducible emissions. Two EMGs 14 and 37 days after onset found a severe neuropathy with a non-inducible musculus orbicularis oculi and musculus nasalis. Over 90% difference in compound

Table 2. The House-Brackmann Facial Nerve Grading Scale ^[5]

Grade	Description	Characteristics
I	Normal	Normal facial function in all areas
II	Slight	Appearance: Slight weakness noticeable on close inspection; may have very slight synkinesis
		At rest: Normal symmetry and tone
		Forehead motion: Moderate-to-good function
		Eyelid closure: Complete with minimal effort
III	Moderate	Mouth motion: Slight asymmetry
		Appearance: Obvious but not disfiguring weakness between the two sides; noticeable but not severe synkinesis, contracture, and/or hemifacial spasm
		At rest: Normal symmetry and tone
		Forehead motion: Slight-to-moderate movement
IV	Moderate-severe dysfunction	Eyelid closure: Complete with effort
		Mouth motion: Slightly weak with maximal effort
		Appearance: Obvious weakness and/or disfiguring asymmetry
		At rest: Normal symmetry and tone
V	Severe	Forehead motion: None
		Eyelid closure: Incomplete
		Mouth motion: Asymmetric with maximal effort
		Appearance: Only barely perceptible motion
VI	Total	At rest: Asymmetric
		Forehead motion: None
		Eyelid closure: Incomplete
		Mouth motion: Slight movement
VI	Total	No facial function

muscle action potential (CMAP) amplitude was found in relation to the right side.

The patient was initially pharmacologically treated for 5 days with amoxicillin/clavulanic acid. After PCR on EBV was positive, treatment was switched to 5 days ceftriaxone. During the same period, he was treated with glucocorticoids and eardrops consisting hydrocortisone, colistin, and bacitracin (Bacicoline-B by Daleco Pharma BV, Enspijk, The Netherlands).

After 6 weeks, no improvement of FNP was seen, and transmastoidal surgical decompression of the facial nerve from geniculate ganglion to the stylomastoid foramen was performed. During surgery, a pale white facial nerve was observed that regained vascularization after decompression (Video 1. See corresponding video/movie images at <http://www.advanceotology.org>). The postoperative course was complicated by a bacterial mastoiditis that needed surgery. After the second surgery, Patient B recovered to a HB III in 3 weeks and HB II after 6 months, with movement and only slight asymmetry of the mouth. We obtained written informed consent from the parents of the brothers.

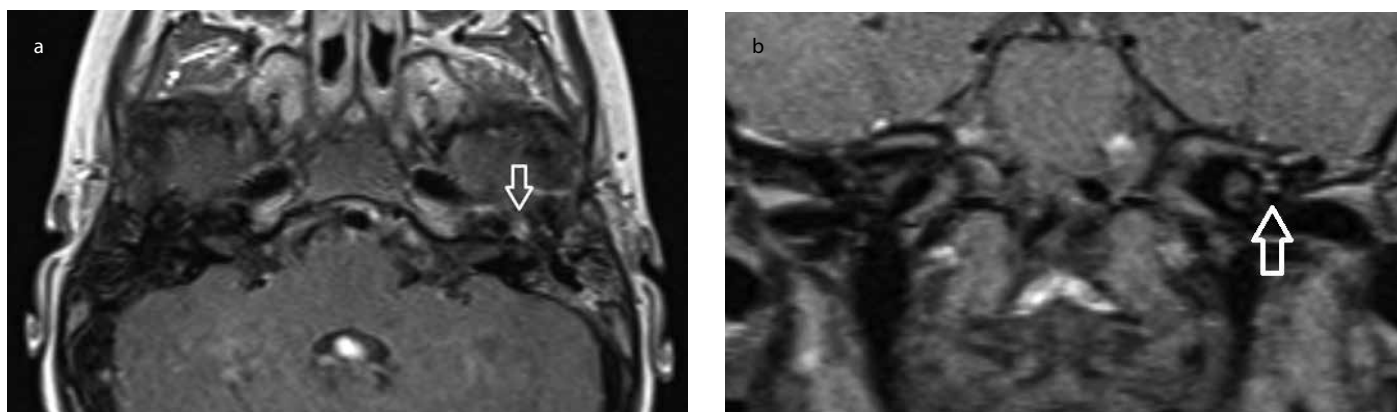


Figure 1. a, b. MRI of the skullbase shows slight enhanced signal at the geniculate ganglion on the left side. A subtle finding found on the axial and coronal slides

DISCUSSION

Epstein-Barr virus is a relatively unknown cause of FNP; it is incidentally reported, and case reports focus on diagnosis rather than treatment. Consequently, literature on treatment of EBV-induced FNP is inconclusive and mainly based on expert opinions. Choosing the most appropriate treatment should be guided by etiology and severity of FNP. Each patient needs an individual approach based on the patient's condition, duration and cause of paralysis, physical finding, EMG, audiogram, anatomical status of the facial nerve, and expectations^[6].

A conservative approach, potentially supplemented with EMG follow-up, could be indicated if the facial nerve is anatomically intact and EMG shows less than a 90% difference in CMAP. Recovery of an infection-derived FNP usually takes less than 1 month. Nearly always substantial (HB II) to complete (HB I) recovery is attained^[1]. In other EBV-associated neurological complications, the prognosis is good; therefore, intervention is not ushered. This could also be the case for EBV-associated FNP^[6].

Pharmacological treatment can be performed using corticosteroids, antibiotics, or antiviral medication. Inflammation and associated edema are considered to be one of causes of FNP. Reducing this edema with corticosteroids accelerates spontaneous clinical improvement of FNP. Controversy remains on the benefit of steroid treatment use in children as clear studies are not available^[7]. If a bacterial infection, such as OM, is the cause of FNP, antibiotics should be administered. OM-associated FNP is less prevalent since the antibiotic era. In the pre-antibiotic era 0.5%–0.7% of OM were complicated by FNP because of persistent inflammation of the fallopian canal. Currently, this complication has become exceptional with an incidence of 0.005%^[8]. When FNP is caused by EBV, treatment with antiviral therapy is questionable. A meta-analysis showed no clinical benefit comparing the treatment of EBV infections with acyclovir and placebo treatment^[9].

Surgical intervention could be indicated when a conservative or pharmacological approach is not sufficient. The rapid improved vascularization of the facial nerve after decompression suggests that a decreased vascular perfusion might be an important factor in the pathogenesis of FNP; therefore, surgical decompression is necessary^[10]. As a guide to determine when decompression is warranted, EMG measurements can be used. Patients with less than 90% reduction are likely to return to a HB grade I or II. If patients have more than 90% reduction of CMAP within 14 days, they are likely to have a HB grade III or IV. In this case, surgical decompression provided significant im-

provement to normal or near-normal recovery. The best results in patients with Bell's palsy with more than 90% reduction in CMAP within 14 days of onset were achieved if surgery was performed within 2 or 3 weeks after onset of FNP^[11].

There are different surgical approaches to establish facial nerve decompression. The different approaches are based on multiple surgical techniques, such as the transmastoid approach reaching the tympanic and mastoid segments and the geniculate ganglion. The middle fossa approach can be added to reach the labyrinthine segment^[7].

The most suitable treatment for the pediatric population with an EBV-derived FNP is still unknown. In our cases, the question remains whether surgical treatment or natural course caused the clinical improvement of FNP. Larger studies comparing the different treatments of FNP with the natural course are needed in order to provide a clear answer.

Informed Consent: Written informed consent was obtained from the parents of the patients who participated in this study.

Peer-review: Externally peer-reviewed.

Author Contributions: Concept - E.V.E., H.F.; Design - E.V.E., H.F.; Supervision - H.F., D.K.; Resources - E.V.E.; Materials - E.V.E.; Data Collection and/or Processing - E.V.E., H.F.; Analysis and/or Interpretation - E.V.E., H.F., D.K.; Literature Search - E.V.E., H.F., D.K.; Writing Manuscript - E.V.E., H.F., D.K.; Critical Review - H.F., D.K.

Acknowledgements: We thank the two brothers and their parents for their permission to use this data.

Conflict of Interest: No conflict of interest was declared by the authors.

Financial Disclosure: The authors declared that this study has received no financial support.

Video 1. Facial nerve decompression.

REFERENCES

1. Lorch M, Teach SJ. Facial nerve palsy: etiology and approach to diagnosis and treatment. *Pediatr Emerg Care* 2010; 26: 763-9. [\[CrossRef\]](#)
2. Cook SP, Macartney KK, Rose CD, Hunt PG, Eppes SC, Reilly JS. Lyme disease and seventh nerve paralysis in children. *Am J Otolaryngol* 1997; 18: 320-3. [\[CrossRef\]](#)
3. Pavlou E, Gkampeta A, Arampatzi M. Facial nerve palsy in childhood. *Brain Dev* 2011; 33: 644-50. [\[CrossRef\]](#)

4. Bolis V, Karadedos C, Chiotis I, Chaliasos N, Tsaouri S. Atypical manifestations of Epstein-Barr virus in children: a diagnostic challenge. *J Pediatr* 2016; 92: 113-21. [\[CrossRef\]](#)
5. House JW, Brackmann DE. Facial nerve grading system. *Otolaryngol Head Neck Surg* 1985; 93: 146-7. [\[CrossRef\]](#)
6. Chu EA, Byrne PJ. Treatment considerations in facial paralysis. *Facial Plast Surg* 2008; 24: 164-9. [\[CrossRef\]](#)
7. Melvin TA, Limb CJ. Overview of facial paralysis: current concepts. *Facial Plast Surg* 2008; 24: 155-63. [\[CrossRef\]](#)
8. Ellefsen B, Bonding P. Facial palsy in acute otitis media. *Clin Otolaryngol Allied Sci* 1996; 21: 393-5. [\[CrossRef\]](#)
9. Torre D, Tambini R. Acyclovir for treatment of infectious mononucleosis: a meta-analysis. *Scand J Infect Dis* 1999; 31: 543-7. [\[CrossRef\]](#)
10. Fukuda T, Sugie H, Ito M, Kikawada T. Bilateral Facial Palsy Caused by Bilateral Masked Mastoiditis. *Pediatr Neurol* 1998; 18: 351-3. [\[CrossRef\]](#)
11. Gantz BJ, Rubinstein JT, Gidley P, Woodworth GG. Surgical management of Bell's palsy. *Laryngoscope* 1999; 109: 1177-88. [\[CrossRef\]](#)