



Original Article

Waardenburg Syndrome: An Unusual Indication of Cochlear Implantation Experienced in 11 Patients

Feda Bayrak, Tolgahan Çatlı, Görkem Atsal, Taşkın Tokat, Levent Olgun

Clinic of Otorhinolaryngology, İzmir Katip Çelebi University Atatürk Training and Research Hospital, İzmir, Turkey (FB)

Clinic of Otorhinolaryngology, Sağlık Bilimleri University Bozyaka Training and Research Hospital, İzmir, Turkey (TÇ, GA, TT, LO)

Cite this article as: Bayrak F, Çatlı T, Atsal G, Tokat T, Olgun L. Waardenburg Syndrome: An Unusual Indication of Cochlear Implantation Experienced in 11 Patients. J Int Adv Otol 2017; 13: 230-2.

OBJECTIVE: The aim of this study was to present the surgical findings of children with Waardenburg syndrome (WS) and investigate speech development after cochlear implantation in this unique group of patients.

MATERIALS and METHODS: A retrospective chart review of the patients diagnosed with WS and implanted between 1998 and 2015 was performed. Categories of auditory performance (CAP) test were used to assess the auditory skills of these patients. CAP is a nonlinear hierarchical scale used to rate a child's developing auditory abilities. Preoperative test results and intraoperative surgical findings of these patients have been presented.

RESULTS: In total, 1835 cases were implanted at our institution, and 1210 of these were children. Among these implantees, 11 were diagnosed with WS (0.59% of all implantees). Four of the 11 patients showed incomplete partition type 2 bony labyrinth abnormality (Mondini deformity) and all patients showed intraoperative gusher during cochleostomy, which was subsided through routine interventions. No other complications occurred during surgery, and all patients showed satisfactory CAP results in the late postoperative period.

CONCLUSION: Our experiences with cochlear implantation in patients with WS showed that the procedure is safe and effective in this group of patients. Surgeons should be aware of possible labyrinth malformations and intraoperative problems such as gusher in these patients. In long term, auditory performances may exhibit satisfactory results with optimal postoperative educational and supportive measures.

KEYWORDS: Waardenburg syndrome, cochlear implantation

INTRODUCTION

Cochlear implantation (CI) has shown considerable improvement in speech and language of congenitally deaf children and is now accepted as a gold standard treatment. However, benefits of CI vary and many determinants such as etiology, implantation age, duration of deafness, and additional comorbidities may play a role on its results. Syndromic cases are not rare among CI patients, and either multiple handicaps or abnormalities of the bony labyrinth may have detrimental effects on satisfactory outcomes. Waardenburg syndrome (WS) is a hereditary syndromic disorder that causes sensorineural hearing loss. It has unique phenotypic characteristics and many specific genotypic mutations. Patients with WS might have any combinations of "dystopia can thorum, eye brow hyperplasia, heterochromia iridis, white forelock, congenital sensorineural hearing loss (SNHL), broad nasal root, affected first degree relative, and skin hypopigmentation" as a clinical picture^[1]. CI may be required if the SNHL is severe. Patients with WS might express specific inner-ear anomalies that might complicate the surgery^[2]. In our retrospective study, we evaluated 1210 children implanted from 1998 to 2015 and reviewed the charts of 11 implanted patients diagnosed with WS. To share our experiences, surgical findings and operative and postoperative complications have been recorded and categories of auditory performance (CAP) test has been performed for the evaluation of auditory skills^[3].

MATERIALS and METHODS

Ethical committee of Sağlık Bilimleri University Bozyaka Training and Research Hospital has approved the study protocol, and written informed consent has been obtained from parents of children. A retrospective chart review of the deaf patients who received CI and were diagnosed with WS between 1998 and 2015 was performed. Findings and family history have been used in establishing a definitive diagnosis of the syndrome according to well-defined criteria^[4]. Preoperative and intraoperative surgical findings of this rare group of patients were assessed. Postoperative complications, if encountered, were recorded.

Corresponding Address: Feda Bayrak E-mail: fedabolat@yahoo.com

Submitted: 25.08.2016 • **Revision Received:** 25.12.2016 • **Accepted:** 08.02.2017 • **Available Online Date:** 17.04.2017

©Copyright 2017 by The European Academy of Otology and Neurotology and The Politzer Society - Available online at www.advancedotology.org

Table 1. The categories of auditory performance (CAP)

Patient number	Type of BLA on implanted side	Type of CI
1	IP-2	MED-EL Pulsar
2	-	Nucleus
3	IP-2	Clarion II
4	IP-2	MED-EL Pulsar
5	-	MED-EL Pulsar
6	-	MED-EL Pulsar
7	-	MED-EL (Combi 40+)
8	-	Nucleus
9	-	Nucleus
10	-	MED-EL Pulsar
11	IP-2	Nucleus Freedom Counter Advance

BLA: bony labyrinth abnormality; IP-2: incomplete partition-2; CI: cochlear implantation

Table 2. Type of the implant and BLA

0	No awareness of environmental sounds
1	Awareness of environmental sounds
2	Response to conversational sounds
3	Identification of environmental sounds
4	Discrimination of some speech sounds without lipreading
5	Understanding of common phrases without lipreading
6	Understanding of conversation without lip reading
7	Calling with a recognized listener

BLA: bony labyrinth abnormality

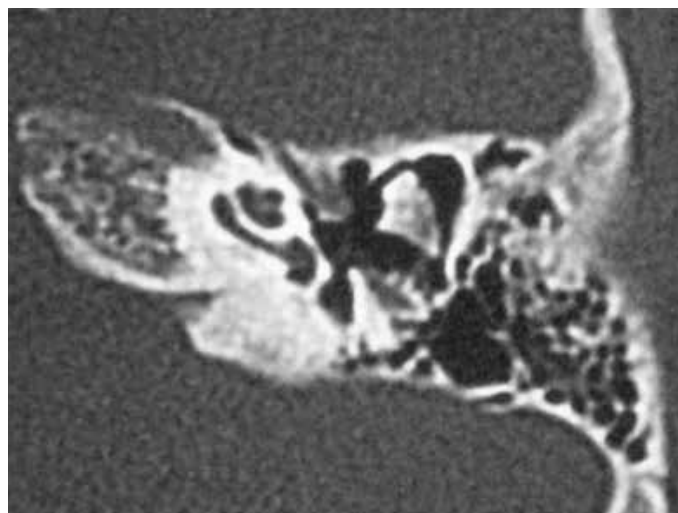
Categories of auditory performance test was used to assess the auditory skills of these patients by the same audiological team preoperatively and postoperatively. The test uses the 8 categories presented below (Table 1). All tests were conducted in a quiet room using a live voice at an approximately 70-dB sound pressure level.

Statistical Analysis

Statistical analysis of the data was conducted with SPSS 21.0.0 (SPSS Inc.; S, Chicago, IL, USA). Preoperative and postoperative CAP scores were compared using the Wilcoxon t-test. A “p” value of <0.05 was considered significant.

RESULTS

In total, 1835 patients with severe to profound levels of SNHL were implanted a tour CI center between January 1, 1998 and May 1, 2015. Of these, 1210 patients were children and 11 met the diagnostic criteria of WS (representing 0.59% of all patients implanted between 1998 and 2015). Three of the 11 patients had at least one or more siblings, and only one of them had hearing loss that needed amplification via a conventional hearing aid (CHA). Two of the patients had consanguineous marriages in their parents, and 1 patient was adopted. Seven of the 11 patients were classified as WS-type I according to their phenotypic characteristics and medical histories. These patients had “SNHL, dystopia cant horum, and pigmentary disturbances.” Others (n: 4) had phenotypic findings identical to those of WS-type 1 but no dystopia can thorum and diagnosed as WS-type II. All patients expressed apparently normal mental development during their sur-

**Figure 1.** Mondini deformity (n: 4).

veys; therefore, additional intelligence quotient (IQ) tests were not administered. Nine of the 11 patients were diagnosed with severe to profound SNHL and received CHA before the surgery. In the remaining 2 patients, the hearing status progressively worsened over years and they received CI when they started to get slightly benefited or showed no benefits with the use of CHA. The age at implantation was 18–77 months (median, 45 months), and length of hearing aid use before implantation was 6–48 months (median, 24 months).

Surgical Findings

Perioperative findings were grouped based on the presence of a cerebrospinal fluid (CSF) gusher, abnormality of the facial nerve, or other malformations around the temporal bone. Classification system of Sennaroğlu and Saatçi^[5] has been used to identify any type of bony labyrinth abnormality (BLA). Electrode insertion was performed via cochleostomy in all patients. A perioperative CSF gusher occurred in 4 of 11 patients who were also diagnosed with incomplete partition type 2 (IP-2) preoperatively (Figure 1). Gusher had managed to seal the fat tissue with fibrin glue via cochleostomy. Head elevation and stool softeners were used postoperatively to avoid any CSF otorrhea. All gushers were stopped from these interventions. In all 11 patients, facial nerve was normal. We have not experienced any late complications. The types of implants [Pulsar® Med-El (Med-El corp., Innsbruck, Austria), Nucleus® (Cochlear®, Sydney, Australia), Clarion II (Advanced Bionics corp., California, USA), Med-El Combi 40+ (Med-El corp, Innsbruck, Austria), Nucleus Freedom Counter Advance (Cochlear®, Sydney, Australia), and BLA] that were observed preoperatively have been listed in Table 2.

CAP Scores

A comparison of the results of the CAP scores before and after implantation has revealed that the scores were significantly higher after the surgery [the median CAP score was 0 (min:0, max:3) and 6 (min:4, max:7) before and after the implantation, respectively; $p < 0.003$].

DISCUSSION

Similar to many other syndromes, WS can express sensorineural hearing loss, and such patients might need CI for acoustic rehabilitation. Our results have revealed that CI is both safe and effective in patients with WS. Parallel to our findings, the retrospective analysis of Andrade et al. showed that this unique group of patients also has a potential to achieve satisfactory speech perception and production abilities after implantation comparable to non-syndromic controls^[6]. In comparison

with other studies, a relatively large number of children participated in our study (7 vs. 11). Similarly, Magalhães et al. [7] in their observational and retrospective study (analysis of 10 cases), concluded that CI in WS “especially via early intervention” resulted in good perceptive auditory and linguistic skills. Another series that studied the outcome of CI in WS demonstrated above average results for both closed- and open-set word standardized tests. For example, Migirov et al. [8] reported an average score of 81% open-set recognition of two-syllable words after a minimum of 1.3-year implant use in a series of 5 children with WS. Our study seems to have significant case numbers. In the literature, WS represents different proportions of all children with hearing loss, and this is not much different than our findings. Although our results represented 0.59% (WS/all implantees), the proportion of the syndrome in a deaf population is approximately 1.4%–2.3% in other centers [9]. Besides the low prevalence of the syndrome, infrequency of severe to profound hearing loss that needs CI during the disease is the main motive for us to state CI as a rare procedure in this group of patients.

Some reports pointed out that patients with WS might express varying degree of mental problems [10]. Our study group had expressed apparently normal mental development during their visits, and no further IQ test was administered. It is a well-known determinant that if a recipient has mental retardation before CI, he tends to progress more slowly in hearing than normal children and even for some authors mental retardation should be accepted as a contraindication for the CI [11].

The basis of SNHL in WS is related to the lack of melanocytes in the stria vascularis of the cochlea and hearing loss is one of the main determinants for the diagnosis of the patient [12]. Since the first description of the syndrome, different genes and their mutations have been related to the different types of the syndrome such as PAX-3 (WS-type I) and MITF (WS-type II) [9]. In our case series, the diagnosis and classification of the patients to a specific sub-type of the syndrome were done according to their phenotypes. However, it is an unknown aspect of the disease that CI outcomes differ between types of WS in the postoperative period. Further studies with larger patient numbers are needed to answer this question.

Although recent studies and our findings have pointed out the effectiveness of CI in WS, it is not a complication-free process and WS might express various inner-ear problems or other malformations of the temporal bone, which might jeopardize the procedure. The most common form of bony labyrinth malformation in WS is related to semicircular canals, and this almost always does not affect a patient’s cochlear implant candidacy [13]. In our patient group, 4 of the 11 patients have had bilateral bony labyrinth malformations. These have been diagnosed as IP-2 according to their preoperative computed tomography scans. Although BLA affects cochlear structure and neural ganglion cell integrity, it is well-known that at least 5000 ganglion cells are necessary to achieve satisfactory speech perception [14]. In particular, IP-2 is known to be the mildest form of the BLA spectrum, and audiological results of this group of patients are optimal or comparable to those of patients having normal cochlea [15]. Our IP-2 patients have achieved satisfactory results similar to patients with WS and normal bony labyrinths.

It is a well-known concern that any CI candidacy with BLA and/or syndrome is more prone to have surgical complications. In our patient group, we had had intraoperative gusher related to IP-2, which was subsided through intraoperative interventions. Fortunately, none of our patients required secondary procedures such as lumbar drainage or surgical re-exploration in the postoperative period. Although facial nerve course in BLA or syndromic cases may be abnormal and can cause problems, none of our patients showed any abnormality of the facial nerve.

CONCLUSION

Our experiences with CI on patients with WS have shown that the procedure is safe and effective in this group of patients. Surgeons should be aware of the possible labyrinth malformations and intra-operative morbidities such as gusher in these patients. In long term, auditory performances may exhibit satisfactory results with optimal postoperative educational and supportive measures.

Ethics Committee Approval: Ethics committee approval was received for this study from the ethics committee of Sağlık Bilimleri University Bozyaka Training and Research Hospital.

Informed Consent: Written informed consent has been obtained from parents of children.

Peer-review: Externally peer-reviewed.

Author Contributions: Concept - T.Ç.; Design - F.B.; Supervision - L.O.; Resources - F.B.; Materials - F.B.; Data Collection and/or Processing - T.T.; Analysis and/or Interpretation - G.A.; Literature Search - F.B., T.Ç., G.A.; Writing Manuscript - F.B.; Critical Review - F.B.

Conflict of Interest: No conflict of interest was declared by the authors.

Financial Disclosure: The authors declared that this study has received no financial support.

REFERENCES

1. Archbold S, Lutman M, Marchall D. Categories of auditory performance. *Ann Otol Rhinol Laryngol* 1995; 166: 312-4.
2. Nayak CS, Isaacson G. Worldwide distribution of Waardenburg syndrome. *Ann Otol Rhinol Laryngol* 2003; 112: 817-20. [CrossRef]
3. Oysu C, Oysu A, Aslan I, Tinaz M. Temporal bone imaging findings in Waardenburg’s syndrome. *Int J Pediatr Otorhinolaryngol* 2001; 58: 215-21. [CrossRef]
4. Waardenburg PJ. A new syndrome combining developmental anomalies of the eyelids, eyebrows and nose root with pigmentary defects of the iris and head hair and with congenital deafness. *Am J Hum Genet* 1951; 3: 195-253.
5. Sennaroğlu L, Saatçi I. A new classification for cochlea vestibular malformations. *Laryngoscope* 2002; 112: 2230-41. [CrossRef]
6. de Sousa Andrade SM, Monteiro AR, Martins JH, Alves MC, Santos Silva LF, Quadros JM, et al. Cochlear implant rehabilitation outcomes in Waardenburg syndrome children. *Int J Pediatr Otorhinolaryngol* 2012; 76: 1375-8. [CrossRef]
7. Magalhães AT, Samuel PA, Goffi-Gomez MV, Tsuji RK, Brito R, Bento RF, et al. Audiological outcomes of cochlear implantation in Waardenburg Syndrome. *Int Arch Otorhinolaryngol* 2013; 17: 285-90.
8. Migirov L, Henkin Y, Hildesheimer M, Muchnik C, Kronenberg J. Cochlear implantation in Waardenburg’s syndrome. *Acta Otolaryngol* 2005; 125: 713-7. [CrossRef]
9. Cullen RD, Zdanski C, Roush P, Brown C, Teagle H, et al. Cochlear implants in Waardenburg Syndrome. *Laryngoscope* 2006; 116: 1273-5. [CrossRef]
10. Yang HM, Lin CY, Chen YJ, Wu JL. The auditory performance in children using cochlear implants: effects of mental function. *Int J Pediatr Otorhinolaryngol* 2004; 68: 1185-8. [CrossRef]
11. Pyman B, Blamey P, Lacy P, Clark G, Dowell R. The development of speech perception in children using cochlear implants: effects of etiologic factors and delayed milestones. *Am J Otol* 2000; 21: 57-61. [CrossRef]
12. Nakashima S, Sando I, Takahashi H, Hashida Y. Temporal bone histopathologic findings of Waardenburg’s syndrome: a case report. *Laryngoscope* 1992; 102: 563-7. [CrossRef]
13. Vivero JR, Fan K, Angeli S, Balkany TJ, Liu XZ. Cochlear implantation in common forms of genetic deafness. *Int J Pediatr Otorhinolaryngol* 2010; 74: 1107-12. [CrossRef]
14. Blamey P. Are spiral ganglion cell numbers important for speech perception with a cochlear implant? *Am J Otol* 1997; 18: 11-2.
15. Catli T, Uckan B, Olgun L. Speech and language development after cochlear implantation in children with bony labyrinth malformations: long-term results. *Eur Arch Otorhinolaryngol* 2015; 272: 3131-6. [CrossRef]