



Original Article

Audiological and Radiological Characteristics in Incomplete Partition Malformations

Merve Özbal Batuk, Betül Çiçek Çınar, Burçe Özgen, Gonca Sennaroğlu, Levent Sennaroğlu

Department of Audiology, Hacettepe University School of Medicine, Ankara, Turkey (MÖB, BÇÇ, GS)

Department of Otorhinolaryngology, Hacettepe University School of Medicine, Ankara, Turkey (LS)

Department of Radiology, Hacettepe University School of Medicine, Ankara, Turkey (BÖ)

Cite this article as: Özbal Batuk M, Çiçek Çınar B, Özgen B, Sennaroğlu G, Sennaroğlu L. Audiological and Radiological Characteristics in Incomplete Partition Malformations. J Int Adv Otol 2017; 13: 233-8.

OBJECTIVE: To compare the audiological and radiological findings of patients with incomplete partition malformations (IPs) and analyze the relationship between the audiological and radiological findings.

MATERIALS and METHODS: The study included 84 patients (168 ears) with IPs as follows: 26 patients with Type I; IP-I (41 ears), 54 patients with Type II; IP-II (108 ears), and 4 patients with Type III; IP-III (8 ears). Remaining 11 ears were diagnosed with other inner ear malformations. Air and bone conduction thresholds were determined with pure tone audiometry, and the air bone gap was recorded in all patients with IPs. Magnetic resonance imaging studies and computerized tomography scans of the temporal bones were analyzed using the PACS system of our university.

RESULTS: It was found that all the ears with IP-I were diagnosed with severe to profound hearing loss. The degree of the hearing loss varied from mild to severe/profound in patients with IP-II. Severe to profound mixed hearing loss (MHL) was determined in all ears with IP-III. The air bone gap was larger in the lower frequencies in the IP-II cases diagnosed with MHL. There was not a significant difference between the air bone gap and the size of the vestibular aqueduct in ears with IP-II ($p>0.05$).

CONCLUSION: Each type of IP has different audiological findings. Depending on the type and degree of the hearing loss, it is possible to choose the appropriate audiological intervention. Patients with IP should be evaluated according to the type of malformation.

KEYWORDS: Incomplete partition, inner ear malformation, hearing loss, radiological evaluation, air bone gap

INTRODUCTION

Inner ear malformations (IEMs) represent about 20%–35% of the etiology of congenital sensorineural hearing loss (SNHL) ^[1-4]. Radiological imaging methods and audiological assessments constitute the key elements in SNHL diagnosis ^[5, 6].

Depending on the embryological development and radiological findings, IEMs are classified into different types. Incomplete partition (IP) malformations with normal external dimensions and abnormal internal cochlear architecture are an important subgroup of IEMs. They are divided into 3 groups: IP-I, IP-II, and IP-III ^[4, 7, 8].

In IP-I malformations, the dimensions of the cochlea and vestibule are normal. There is no modiolus, and the shape of the cochlea is empty, unpartitioned, and cystic ^[9]. Incomplete Partition Type I malformations are also known as cystic cochleovestibular malformations. Because of the defective development of the cochlear aperture and the absence of the modiolus, there is a defect between the internal auditory canal and the cochlea (Figure 1a) ^[4, 8].

In IP-II malformations, the basal part of the modiolus is developed, and the dimensions of the cochlea are normal ^[9]. They are characterized by the absence of the interscalar septum, cystic dilatation of the apical part of the cochlea, and a hypoplastic modiolus. The interscalar defect is at the apex of the cochlea between the middle and apical turns (Figure 1b) ^[4, 8].

In IP-III malformations, the interscalar septum is present, but there is no modiolus in the cochlea. The cochlea is located directly at the lateral ending of the internal auditory canal. Similar to other IP malformations, the external dimensions of the cochlea are normal. IP-III malformations are associated with X-linked deafness (Figure 1c) ^[4].

Corresponding Address: Merve Özbal Batuk E-mail: merveozbal@hotmail.com

Submitted: 02.09.2016

Revision Received: 05.01.2017

Accepted: 25.01.2017

©Copyright 2017 by The European Academy of Otology and Neurotology and The Politzer Society - Available online at www.advancedotology.org

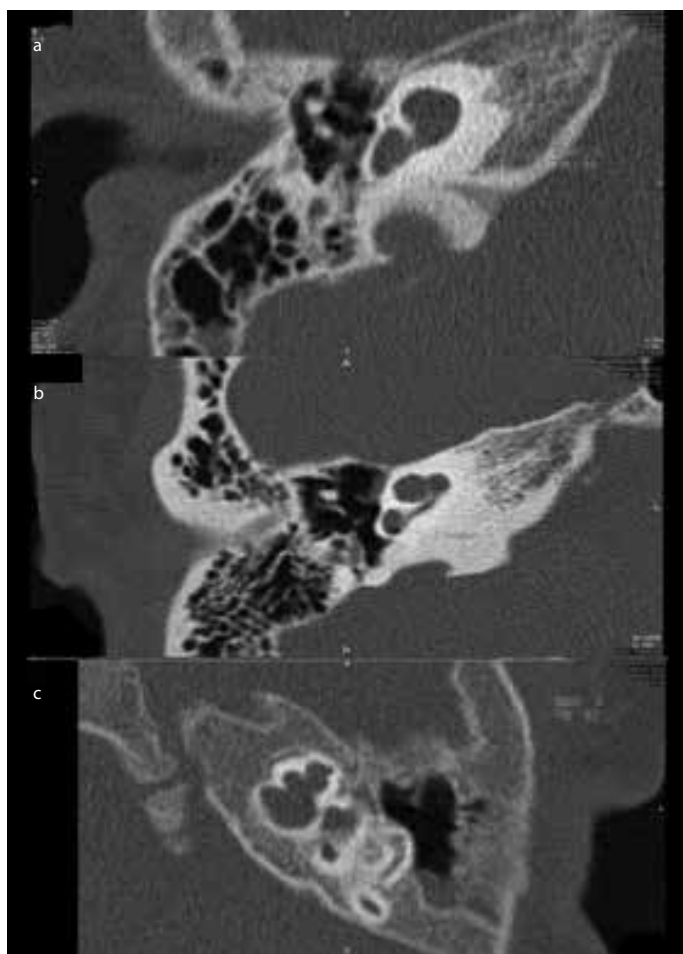


Figure 1. a-c. Incomplete Partition a.Type I, b.Type II, c. Type III

The characteristics of the hearing loss associated with IP malformations vary. Reportedly, IP-I malformations are usually associated with severe to profound hearing loss^[10]. Due to the versatile development of the Corti and auditory neural population in IP-II malformations, the configuration of the hearing loss varies from normal hearing to severe and profound hearing loss^[9]. Patients with IP-III malformations can be diagnosed with conductive hearing loss (CHL), mixed hearing loss (MHL), or, rarely, sensorineural hearing loss (SNHL). Audiological intervention is determined according to the type and degree of hearing loss^[11].

While a literature review found papers related to the audiological findings of patients with IP-I, IP-II, large vestibular aqueduct (LVA), and IP-III malformations separately, no study was found investigating and comparing the audiological findings in IP-I, IP-II, and IP-III patients collectively. The aim of the present study was to investigate the audiological findings in patients with IP malformations. This article will compare the audiological and radiological findings of the patients with IPs and analyze the relationship between the audiological and radiological findings.

MATERIALS and METHODS

The IEM database in our clinic was reviewed following approval from the Non-interventional Clinical Research Ethics (GO 14/196-31) Institutional Review Board.

Participants

According to the IEM database at the clinic, there were 481 patients with different IEMs, and 187 of these patients were diagnosed with an IP malformation (38%). The patients that could not be reached or declined to participate were not included in the study. Of the excluded patients, 5 had follow-up treatments in a different clinic and 3 had active middle ear pathology. The study included 84 patients (168 ears) with malformations as follows: 26 patients with IP-I (age range: 18 months-26 years; mean age: 7.7), 54 patients with IP-II (age range: 9 months-32 years; mean age: 8.6), and 4 patients with IP-III (age range: 2-19 years; mean age: 9.6). Radiological evaluations of the patients were analyzed using the university's PACS imaging system or printed images. Written informed consent was obtained from the patients who participated in this study.

Audiological Evaluation

All subjects underwent an audiological evaluation. All audiological tests were performed under standard clinical procedures in a soundproof room with a calibrated GSI 61 clinical audiometer (Grason-Stadler Inc., Minnesota, MN, USA), headphones (TDH 39P) or insert earphones (3A insert-phone), and a bone vibrator (placed at the mastoid) (BA-71). Middle-ear tympanometry was performed with the GSI TympStar version 2 (Middle-ear Analyzer, Grason-Stadler Inc., Minnesota, MN, USA). Hearing levels were determined by pure-tone audiometry, and the pure-tone average was calculated for each ear. The air conduction maximum output was 120 dB, and the bone conduction maximum output was 80 dB. In the case of "no response" at the bone conduction levels, the air bone gap was calculated as "0". To calculate the mean audiometric thresholds, all thresholds were added to the analyses, including ears with no response at any frequency. In cases with patients under the age of 2, an auditory brainstem response threshold evaluation was also performed as an objective assessment parameter. According to the audiological evaluation results, hearing losses were classified depending on the type (conductive, mixed, or sensorineural) and degree of hearing loss. The hearing level of each ear was calculated by a three-tone average (0.5, 1, and 2 kHz), and the hearing loss was labeled as subtle (16-25 dB), mild (26-40 dB), moderate (41-55 dB), moderate-severe (56-70 dB), severe (71-90 dB), or profound (>90 dB).

Radiological Evaluation

The IP malformations were diagnosed based on the classification performed by Sennaroğlu^[4]. Computerized tomography (CT) scans of the temporal bones were analyzed by an experienced neuroradiologist and neuro-otologist using the axial sections. CT imaging was performed on a 4-channel multidetector CT scanner (SOMATOM Plus 4 Volume Zoom, Siemens, Erlangen, Germany) in the axial plane. The images were obtained with 0.5 mm collimation and 0.5 mm thickness. In the 8 patients with IP-II malformations, the CT imaging was performed with an older-generation helical CT scanner with 1 mm slice thickness, and only hard copy images were available for interpretation. The CT scans of the patients with IP-II malformations were reviewed, and the ventilation of the middle ear, appearance of the semicircular canals, structure of the modiolus, and size of the vestibular aqueduct were examined. The ventilation of the middle ear was defined as normal or opacified. The semicircular canals were evaluated for dehiscence and aplasia. The modiolus in each ear was

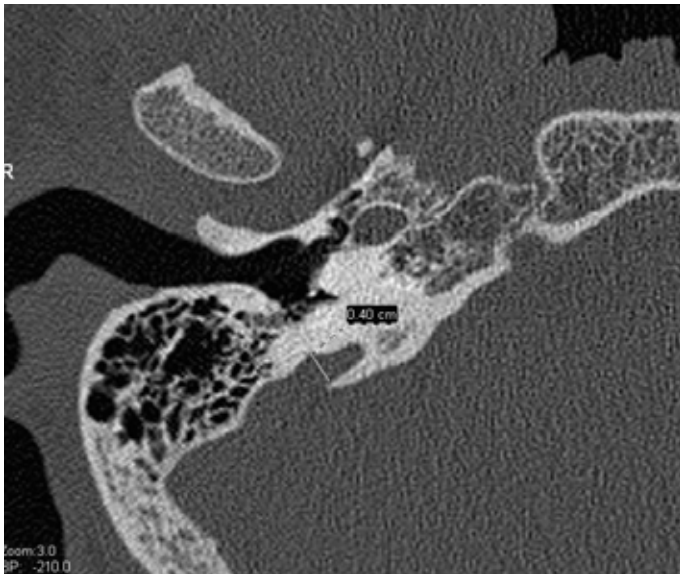


Figure 2. Axial section of the left temporal bone showing how the midpoint diameter was calculated and was indicative of EVA if >1.0 mm

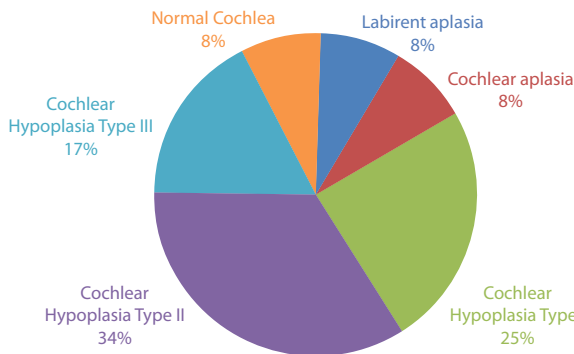


Figure 3. Types of the IEM of the contralateral ears of the patients with unilateral IP-I

assessed and classified as aplastic, dysplastic/hypoplastic, or normal. The midpoint of the vestibular aqueduct was measured and defined in millimeters (Figure 2).

Magnetic Resonance Imaging (MRI) studies of the patients diagnosed with IP-I and IP-III malformations were also reviewed using the PACS system. Magnetic Resonance Imaging examinations were performed with either a 3T (Allegra, Siemens, Erlangen, Germany) or 1.5 T scanner (Symphony, Siemens, Erlangen, Germany) using a standard head coil. The standard temporal bone protocol included transverse T1-weighted imaging (WI), transverse T2-WI, and axial and sagittal oblique three-dimensional (3D) constructive interference in steady-state (CISS) imaging. The cochleovestibular nerves were classified as aplastic, hypoplastic, or normal depending on their size. IP-I cases frequently have cochlear nerve (CN) hypoplasia or aplasia. An MRI was routinely done in IP-I and IP-III cases, and the size of the CN was evaluated in all cases. Due to the rarity of encountering CN aplasia in IP-II cases in the early 2000s, MRIs were not routinely done in IP-II cases.

Statistical Analysis

The results of the present study were assessed with IBM SPSS 21.0 (IBM Corporation, Armonk, NY, USA) for Windows software. In the

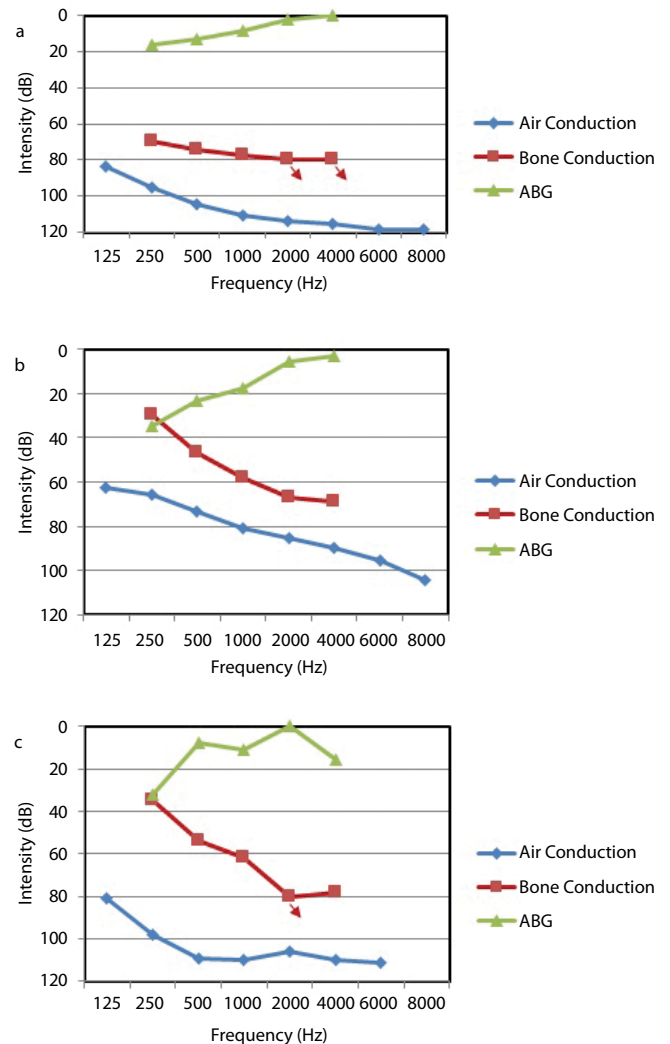


Figure 4. Mean audiometric thresholds of the patients with IP-I (a), IP-II (b), IP-III (c)

descriptive statistics, the numerical values were represented by the average, standard deviation, median, minimum, and maximum values. The categorical variables were represented by the frequency and percentage. The distribution of the air-conducted audiometric thresholds according to the cochleovestibular nerve for IP-I patients and the modiolus for IP-II patients were analyzed using the Kruskal Wallis Test. The relationship between the air-bone gap (ABG) and the size of the vestibular aqueduct was analyzed using the Spearman's rho Test. The criterion for statistical significance was set at $p \leq 0.05$, two-tailed.

RESULTS

Audiological Evaluation

The authors identified 73 IP-I (15%), 106 IP-II (22%), and 8 IP-III (1.5%) patients in the Department of Otorhinolaryngology database. Of the 481 patients with IEM, 39% had IP malformations. The present study included 26 patients (41 ears) with IP-I, 54 patients (108 ears) with IP-II, and 4 patients (8 ears) with IP-III malformations. A total of 67 ears were excluded from the audiological evaluation for having a cochlear implant (53), an auditory brainstem implant (1), atresia of the outer ear (1), normal cochlear anatomy in the contralateral ear (1), or an-

Table 1. Configuration of the degree and type of hearing loss in IP-I, IP-II and IP-III

		IP-I		IP-II		IP-III	
		n	%	n	%	n	%
Degree of the Hearing Loss	Normal			2	2.8		
	Subtle/Mild			1	1.4		
	Moderate/ Moderate-Severe			15	20.2		
	Severe to Profound	22	100	56	75.6	5	100
TOTAL		22	100	74	100	5	100
Type of the Hearing Loss	Conductive			2	2.8		
	Mixed	2	9.1	52	70.2	5	100
	Sensorineural	20	90.9	20	27		
TOTAL		22	100	74	100	5	100
IP-I: Incomplete Partition Type I; IP-II Incomplete Partition Type II; IP-III Incomplete Partition Type III							

IP-I: Incomplete Partition Type I; IP-II Incomplete Partition Type II; IP-III Incomplete Partition Type III

other type of IEM in the contralateral ear (11). Figure 3 indicates the types of IEMs of the contralateral ears of the patients with unilateral IP-I malformations.

Figure 4 shows the results of the tonal audiometric evaluation of the patients with IP-I, IP-II, and IP-III malformations. As can be seen from Figure 4a, IP-I patients usually presented with severe to profound SNHL. The mean bone conduction thresholds in IP-I cases showed that the upper limits of the bone conduction output and ABG were only seen in 2 IP-I patients. Figure 4b illustrates that the audiometric thresholds in cases with IP-II malformation were better than those in IP-I and IP-III patients. Although ABG was only at low frequencies in IP-II patients, ABG was seen at all frequencies, except 2 kHz, in IP-III patients.

Table 1 shows the type and degree of hearing loss according to the type of IP malformation. As can be seen in Table 1, all cases with IP-III malformations showed severe to profound MHL, and most cases with IP-I malformations were diagnosed with severe to profound SNHL. There were only 2 cases with ABG at low frequencies. In patients with IP-II malformations, the degree of the hearing loss varied from normal to severe/profound. The type of the hearing loss also varied in cases with IP-II malformations and included conductive, mixed, or sensorineural.

Radiological Evaluation

The size of the vestibular aqueduct was reviewed from the High Resolution Computed Tomography (HRCT) images in patients with IP-I and IP-III. 13 of 41 ears (32%) with IP-I were diagnosed with enlarged vestibular aqueduct. In all eight ears with IP-III (100%), we noticed that the vestibular aqueduct was more medially located with a different shape and varying degrees of dilatation.

Table 2 shows the radiological findings of the ears with IP-II malformations. On the day of the radiological evaluation of the 20 ears with IP-II malformations (21.7%), there was opacification in the HRCT as follows: 2 ears were diagnosed with semicircular canal dehiscence (2.2%), and the remaining 90 ears had normal semicircular canals (97.8%). Depending on the development of the modiolus, they were

Table 2. Different aspects of IP malformations

Type of malformation	IP-I	IP-II	IP-III
Residual hearing	No	Yes	Yes
Progressivity	No	Yes	No
Type and Degree of HL	Severe to profound SNHL	Normal, mild, moderate, severe, profound, CHL, MHL, SNHL	Severe to profound MHL
ABG	Absent	Usually present at low frequencies	Usually present at all frequencies except 2kHz
Audiological intervention	CI or ABI	HA or CI	Only CI
Cochlear nerve	Normal, Hypoplastic, Aplastic	Normal	Normal
Vestibular aqueduct	Rarely enlarged	Almost always enlarged	Medially located with different shape and varying degrees of dilatation.

IP-I: Incomplete Partition Type I; IP-II Incomplete Partition Type II; IP-III Incomplete Partition Type III; SNHL: Sensorineural hearing loss; CHL: Conductive hearing loss; MHL: Mixed hearing loss; CI: Cochlear implantation; ABI: Auditory brainstem implantation

classified as dysplastic (44 ears; 53.7%), aplastic (6 ears; 7.3%), or normal (32 ears; 39.0%).

Although the results indicate that the development of the modiolus was not significantly associated with the audiometric findings ($p>0.05$), the hearing thresholds of the patients with aplastic modiolus were lower than the patients with dysplastic and normal modioli. When the size of the vestibular aqueduct was measured in IP-II ($n=90$), 83 ears measured >1.0 mm and were defined as having an enlarged vestibular aqueduct (mean: 3.19 mm; range, 1.0 mm to 6.1 mm). The remaining 7 ears were classified as normal. No correlation between the hearing threshold and the size of the vestibular aqueduct was found ($p>0.05$).

The cochlear nerve of the 31 ears with IP-I malformations were analyzed from MRI images and classified according to the size of the cochlear nerve as follows: 14 ears were classified as normal (45%), 8 ears were classified as hypoplastic (26%), and 9 ears were classified as aplastic (29%).

Although the results indicated that the size of the cochleovestibular nerve was not significantly associated with the audiometric findings ($p>0.05$) in IP-I, the hearing thresholds of the patients with aplastic cochlear nerves were lower than patients with normal or hypoplastic cochlear nerves.

The different aspects of the IP malformations are summarized in Table 2 according to the audiological and radiological findings.

DISCUSSION

Many studies have analyzed the audiological findings of IEMs [2, 10, 12-18]. This study, however, is the first paper to compare the audiological and radiological findings of patients diagnosed with IP malformations.

Studies have shown that the audiological performance of patients with IP-I malformations is worse than those with other IP malformations [4, 10, 12, 16, 19]. In this study, all the ears with IP-I malformations were diagnosed with severe to profound SNHL. These results may indicate that the major treatment option for IP-I malformations is cochlear implantation if the cochlear nerve is present. In cases with IP-I patients with an aplastic cochlear nerve, auditory brainstem implantation should be recommended.

In IP-II malformations, the internal organization of the cochlea is more developed than in IP-I malformations. While the modiolus appears to be defective, particularly in the apical parts, the basal part is present. Berrettini et al. [10] reported that residual neural functioning was weak in IP-I malformations due to the non-development of the modiolus and empty cystic cavity. On the other hand, the modiolus can be seen in IP-II patients due to the development of the basal turn, and residual hearing is better than in IP-I patients [10].

A recent histopathological study by Sennaroğlu [7] demonstrated that the three IP anomalies may have different pathophysiological explanations. According to that paper, IP-I malformations may be the result of a defective vascular supply from the internal auditory canal, and therefore, the innermost endosteal layer of the otic capsule is defective. IP-II malformations may be the result of the transmission of high cerebral spinal fluid (CSF) pressure into the inner ear via LVA. Finally, IP-III malformations appear to be the result of a defective vascular supply from the middle ear, and the outer two layers of the otic capsule are defective.

An examination of the literature studies revealed that the hearing loss associated with IP-II and LVA malformations is heterogeneous, and the conductive component is not associated with middle ear pathologies [2, 12, 13, 17, 18, 20-26]. Roesch et al. [25] found that patients with IP-II and isolated LVA malformations were diagnosed not only with severe to profound hearing loss but also with moderate asymmetrical hearing loss. Hence, Ha et al. [2] reported that in IP-II malformations, despite residual hearing at low and mid frequencies, there was hearing loss at high frequencies.

In this study, different types and degrees of hearing loss were observed in patients with IP-II malformations. The rate of the severe/profound hearing loss was high (76%) in IP-II patients. This could be the result of the progressive characteristics of IP-II malformation. In light of these findings, patients with IP-II were usually diagnosed with MHL and, due to the progressive hearing loss during follow-up care, cochlear implantation could be recommended.

In the present study, the ABG was largest for the IP-II patients diagnosed with MHL at lower frequencies (250 Hz: 34.85 dB; 500 Hz: 23.38 dB; 1000 Hz: 17.32 dB). This study confirms previous findings that the ABG was the largest in patients with LVA at lower frequencies [13, 20, 21].

Previous studies investigated the relationship between the size of the vestibular aqueduct and hearing loss, and different results were indicated [22, 27, 28]. Among these studies, Seo et al. [28] found a correlation between the ABG and the size of the vestibular aqueduct. In patients diagnosed with a large vestibular aqueduct, a larger ABG is associated with a larger vestibular aqueduct, especially at lower frequencies (250 Hz and 500 Hz).

In contrast, Madden et al. [27] reported that the measurement of the vestibular aqueduct from the midpoint or operculum was not directly involved with the audiometric threshold and configuration. Although there was not a direct relationship, the vestibular aqueduct was larger in the patients with progressive hearing loss. In this study, radiological evaluations revealed that there was not a significant relationship between the ABG and the size of the vestibular aqueduct ($p>0.05$). Considering this finding, the size of the vestibular aqueduct is not associated with the degree of hearing loss and the ABG. When the progressive nature of the disease is accounted for, it is very difficult to find a correlation between the radiological and audiological results in IP-II patients. While hearing thresholds can change over time, the radiological characteristics remain the same in IP-II patients.

In accordance with Giesemann et al. [29] the present study found that IP-I malformations can be associated with hypoplastic/aplastic cochlear nerves. Hence, the diameter of the cochlear nerve was normal in all patients with IP-II and IP-III malformations in this study. This outcome can be explained by the histopathological study. An IP-I malformation is the result of a defective vascular supply coming from the internal acoustic canal (IAC), which may also affect the cochlear nerve. In IP-II and IP-III patients, the IAC does not appear to cause the pathology, and therefore, the cochlear nerve is normal in IP-II and IP-III patients [7].

Consistent with previous studies, the present study noted the presence of severe to profound MHL in all IP-III patients [12, 14, 15]. Among these studies, Choi et al. [14] stated that the conductive component found in IP-III malformations is related to the pathologic third window. A recent paper by Sennaroğlu [7], suggested that the thinner otic capsule was responsible for the ABG in IP-III malformations. As they have an excellent cochlear nerve, it may be possible to obtain better thresholds as a result of the thinner otic capsule. This result may imply that IP-III malformation is characterized by MHL and ABG.

According to this study's findings, the most common IEM was cochlear hypoplasia type II (34%) in cases with unilateral IP-I. According to the histopathological study, this was explained by changes in the vascular supply of the modiolus and the greater magnitude of the vascular insult in IP-I [7].

CONCLUSION

These results may indicate that each type of IP malformation has different audiological findings. The audiological findings showed poorer auditory responses in IP-I patients compared to other IP malformation types. Although these results show a high rate of severe to profound hearing loss in cases with IP-II malformation, long-term follow-up care should be taken into account in future studies involving a higher number of ears. Depending on the type and degree of the hearing loss, it is possible to choose the appropriate audiological intervention, such as hearing aid, cochlear implant, or auditory brainstem implant. In conclusion, patients with IP malformations should be evaluated according to the type of the malformation.

Ethics Committee Approval: Ethics committee approval was received for this study from the ethics committee of Hacettepe University, the Non-Interventional Clinical Research Ethics (GO 14/196-31) Institutional Review Board.

Informed Consent: Written informed consent was obtained from patients and the parents of the patients who participated in this study.

Peer-review: Externally peer-reviewed.

Author Contributions: Concept - M.Ö.B., G.S., L.S.; Design - M.Ö.B., L.S.; Supervision - G.S., L.S.; Resources - M.Ö.B.; Materials - M.Ö.B., B.Ö., G.S.; Data Collection and/or Processing - M.Ö.B.; Analysis and/or Interpretation - M.Ö.B., B.Ç.Ç., B.Ö., L.S.; Literature Search - M.Ö.B.; Writing Manuscript - M.Ö.B.; Critical Review - M.Ö.B., L.S.

Conflict of Interest: No conflict of interest was declared by the authors.

Financial Disclosure: The authors declared that this study has received no financial support.

REFERENCES

- Chadha NK, James AL, Gordon KA, Blaser S, Papsin BC. Bilateral cochlear implantation in children with anomalous cochleovestibular anatomy. *Arch Otolaryngol Head Neck Surg* 2009; 135: 903-9. [\[CrossRef\]](#)
- Ha JF, Wood B, Krishnaswamy J, Rajan GP. Incomplete Cochlear Partition Type II Variants as an Indicator of Congenital Partial Deafness: A First Report. *Otol Neurotol* 2012; 33: 957-62. [\[CrossRef\]](#)
- McClay JE, Tandy R, Grundfast K, Choi S, Vezina G, Zalzal G, et al. Major and minor temporal bone abnormalities in children with and without congenital sensorineural hearing loss. *Arch Otolaryngol Head Neck Surg* 2002; 128: 664-71. [\[CrossRef\]](#)
- Sennaroglu L. Cochlear implantation in inner ear malformations—a review article. *Cochlear Implants Int* 2010; 11: 4-41. [\[CrossRef\]](#)
- Chi DH and Arjmond E. Congenital Inner Ear Anomalies. In: Bluestone C, Simons, JP, Healy, GB editor. *Pediatric Otolaryngology*. 5 ed., USA: People's Medical Publishing House; 2014. p. 532-42.
- Zarandy MM, Rutka J. *Diseases of the Inner Ear: A Clinical, Radiologic, and Pathologic Atlas*: Springer Science & Business Media; 2010. [\[CrossRef\]](#)
- Sennaroglu L. Histopathology of inner ear malformations: Do we have enough evidence to explain pathophysiology? *Cochlear Implants Int* 2016; 17: 3-20. [\[CrossRef\]](#)
- Sennaroglu L, Saatci I. A new classification for cochleovestibular malformations. *Laryngoscope* 2002; 112: 2230-41. [\[CrossRef\]](#)
- Swartz JaM, SK. The Inner Ear and Otodystrophies. In: Swartz JaL, LA editor. *Imaging of the Temporal Bone*, USA: Thieme; 2009. p. 298-401.
- Berrettini S, Forli F, De Vito A, Bruschini L, Quaranta N. Cochlear implant in incomplete partition type I. *Acta Otorhinolaryngol Ital* 2013; 33: 56-62.
- Jeong S-W, Kim L-S. A new classification of cochleovestibular malformations and implications for predicting speech perception ability after cochlear implantation. *Audiol Neurotol* 2015; 20: 90-101. [\[CrossRef\]](#)
- Sennaroglu G, Sennaroglu L. Hearing Loss in Inner Ear Malformations. *Encyclopedia Otolaryngol Head Neck Surg* 2013; 1143-50. [\[CrossRef\]](#)
- Boston M, Halsted M, Meinzen-Derr J, Bean J, Vijayasekaran S, Arjmand E, et al. The large vestibular aqueduct: a new definition based on audiologic and computed tomography correlation. *Otolaryngol Head Neck Surg* 2007; 136: 972-7. [\[CrossRef\]](#)
- Choi BY, An YH, Park JH, Jang JH, Chung HC, Kim AR, et al. Audiological and surgical evidence for the presence of a third window effect for the conductive hearing loss in DFNX2 deafness irrespective of types of mutations. *Eur Arch Otorhinolaryngol* 2013; 270: 3057-62. [\[CrossRef\]](#)
- Kang WS, Shim BS, Lee KS. Audiologic performance after cochlear implantation in children with X-linked deafness: comparison with deaf children with a normal inner ear structure. *Otol Neurotol* 2013; 34: 544-8. [\[CrossRef\]](#)
- Kontorinis G, Goetz F, Giourgias A, Lenarz T, Lanfermann H, Giesemann AM. Radiological diagnosis of incomplete partition type I versus type II: significance for cochlear implantation. *Eur Radiol* 2012; 22: 525-32. [\[CrossRef\]](#)
- Mamikoğlu B, Bentz B, Wiet RJ. Large vestibular aqueduct syndrome presenting with mixed hearing loss and an intact mobile ossicular chain. *Otorhinolaryngol Nova* 2000; 10: 204-6. [\[CrossRef\]](#)
- Nakashima T, Ueda H, Furuhashi A, Sato E, Asahi K, Naganawa S, et al. Air-bone gap and resonant frequency in large vestibular aqueduct syndrome. *Otol Neurotol* 2000; 21: 671-4.
- Sennaroglu L, Ziyal I. Auditory brainstem implantation. *Auris Nasus Larynx* 2012; 39: 439-50. [\[CrossRef\]](#)
- Attias J, Ulanovski D, Shemesh R, Kornreich L, Nageris B, Preis M, et al. Air-bone gap component of inner-ear origin in audiograms of cochlear implant candidates. *Otol Neurotol* 2012; 33: 512-7. [\[CrossRef\]](#)
- Clark JL, Roeser RJ. Large vestibular aqueduct syndrome: a case study. *J Am Acad Audiol* 2005; 16: 822-8. [\[CrossRef\]](#)
- Gopen Q, Zhou G, Whittemore K, Kenna M. Enlarged vestibular aqueduct: review of controversial aspects. *Laryngoscope* 2011; 121: 1971-8. [\[CrossRef\]](#)
- Hirai S, Cureoglu S, Schachern PA, Hayashi H, Paparella MM, Harada T. Large vestibular aqueduct syndrome: a human temporal bone study. *Laryngoscope* 2006; 116: 2007-11. [\[CrossRef\]](#)
- Pritchett C, Zwolan T, Huq F, Phillips A, Parmar H, Ibrahim M, et al. Variations in the cochlear implant experience in children with enlarged vestibular aqueduct. *Laryngoscope* 2015; 125: 2169-74. [\[CrossRef\]](#)
- Roesch S, Moser G, Rasp G, Toth M. CT-scans of cochlear implant patients with characteristics of Pendred syndrome. *Cell Physiol Biochem* 2013; 32: 166-72. [\[CrossRef\]](#)
- Wu CC, Chen YS, Chen PJ, Hsu CJ. Common clinical features of children with enlarged vestibular aqueduct and Mondini dysplasia. *Laryngoscope* 2005; 115: 132-7. [\[CrossRef\]](#)
- Madden C, Halsted M, Benton C, Greinwald J, Choo D. Enlarged vestibular aqueduct syndrome in the pediatric population. *Otol Neurotol* 2003; 24: 625-32. [\[CrossRef\]](#)
- Seo YJ, Kim J, Choi JY. Correlation of vestibular aqueduct size with air-bone gap in enlarged vestibular aqueduct syndrome. *Laryngoscope* 2016; 126: 1633-8. [\[CrossRef\]](#)
- Giesemann AM, Kontorinis G, Jan Z, Lenarz T, Lanfermann H, Goetz F. The vestibulocochlear nerve: aplasia and hypoplasia in combination with inner ear malformations. *Eur Radiol* 2012; 22: 519-24. [\[CrossRef\]](#)