



## Letter to Editor

# Implementation of the “EAONO/JOS Definitions and Classification of Middle Ear Cholesteatoma” – from STAM to STAMCO

**Paul Merkus, Fleur A. ten Tije, Mariska Stam, Frederique M.L. Tan, Robert Jan Pauw**

Department of Otolaryngology-Head and Neck Surgery, section Ear & Hearing, VUmc Amsterdam Public Health Research Institute, Amsterdam, Netherlands (PM, FT, MS)

Department of Otolaryngology-Head and Neck Surgery, Erasmus MC Rotterdam, Rotterdam, Netherlands (FT, RJP)

**Cite this article as:** Merkus P, Ten Tije FA, Stam M, Tan FML, Pauw RJ. Implementation of the “EAONO/JOS Definitions and Classification of Middle Ear Cholesteatoma” from STAM to STAMCO. J Int Adv Otol 2017; 13: 272-5.

Dear Editor,

Recently, EAONO/JOS's joint consensus paper on definitions, classification, and staging of middle ear cholesteatoma was published<sup>1</sup>. As it is the era of collection of and report on uniform and comparable data, this is a welcome consensus statement. Currently, we are setting up a new nationwide multicenter study in the Netherlands, entitled Dutch Cholesteatoma Data, in which we would like to implement this guideline. To inform colleagues about our local experiences and choices so far, we are writing this letter.

Although the EAONO/JOS consensus statements are clearly presented, we encountered some difficulties with the classification. First, we believe that the divisions of the middle ear space need further specifications. The anatomical sites as presented in the figure and the text of the consensus statements<sup>1</sup> can be variously interpreted and show some “blank spots.” For instance, the borders used for the anterior epitympanic space are unclear, which, in addition to the variation in anatomy and exposition in this area (canal wall up, canal wall down, microscopic, and endoscopic), will most likely result in a non-uniform registration. Second, we strongly believe that there is a primary need to elaborate on the classification rather than simplify it with a staging system. Gathering classification data on extent, complication, and ossicular state, using an easy format will make it possible to monitor surgical outcomes. This will allow comparisons of data among different hospitals, publications, and classifications. When large numbers of data on outcomes in relation to classification become available, results can be used to propose different stages. To improve the practical applicability of the EAONO/JOS joint statement in our national study, we have proposed to our participating ENT surgeons the following modifications:

### **1. The borders of divisions of the middle ear and mastoid are further defined, and consequently, the figure of the consensus paper is refined<sup>[1]</sup>.**

In the EAONO/JOS consensus statement, the middle ear and mastoid spaces are divided into four sites to classify the extent of the cholesteatoma: difficult access sites (S), tympanic cavity (T), attic (A), and mastoid and antrum (M). The difficult access sites (S) further include S1 (the supratubal recess) and S2 (the sinus tympani). We propose to define the anatomical divisions of the middle ear and mastoid in more detail using surgical and anatomical landmarks. These landmarks based on a selection of published papers on this topic are highly likely to be identified both on CT scans and during all types of surgical approaches and are thus less prone to various interpretations<sup>[2-4]</sup>.

Table 1 summarizes our suggestions for further specification of borders between the different sites of the middle ear and mastoid. In addition, Figure 1 shows the updated illustration based on those refined borders.

An advantage of a more detailed description of these borders can be illustrated by the following examples that describe the difference between A and S1 anterior. In case a cholesteatoma extends to the head level of the malleus, but not further anteriorly,

**Corresponding Address:** Fleur A. ten Tije E-mail: dcd@vumc.nl

**Submitted:** 20.05.2017 • **Accepted:** 09.06.2017 • **Available Online Date:** 17.07.2017

©Copyright 2017 by The European Academy of Otolology and Neurotology and The Politzer Society - Available online at [www.advancedotology.org](http://www.advancedotology.org)

**Table 1.** STAMCO cholesteatoma classification system: registration of the extent of cholesteatoma (STAM), complications (C) and ossicular chain status (O) during surgery based on STAM system as presented by EAONO/JOS.

Letter	Explanation	Further classified as	To be defined by anatomical landmarks as
S	Difficult access sites	S1: Difficult anterior area (anterior epitympanic space/supratubal recess)  S2: Difficult posterior area (sinus tympani)	The area anterior/antero-inferior to one of the following: • Malleus head • Cog • Tendon of the tensor tympani • Cochleariform process • Virtual plane drawn through the anterior margin of the tympanic annulus  The area posterior to an imaginary line between posterior boundaries of the round and oval window, medial and caudal to the pyramidal process, and medial to the vertical portion of the facial nerve.
T	Tympanic cavity		
A	Attic/epitympanic space		This is the area between: • Anterior: malleus head (part of the epitympanum) • Posterior: fossa incudis or tip of the short process of the incus • Superior: the tegmen middle fossa • Lateral: the scutum and Shrapnell's membrane at the level of the tympanic annulus • Medial: the labyrinth bone, facial nerve (tympanic portion) The attic/epitympanic space contains the malleus head, body of the incus, and short process of the incus.
M	Mastoid & antrum		The anterior border of the mastoid & antrum starts posterior to the fossa incudis/short process of the incus.
C	Complication status	Cn: No complication C1: Extracranial complication C2: Intracranial complication	Remark: Cerebrospinal fluid leak may be considered as an extracranial complication.
O	Ossicular status at the beginning of the surgery	On: No ossicles missing or destroyed (intact ossicular chain) O1: One ossicle missing or destroyed, malleus present, stapes present, incus missing or (partially) destroyed O2: Two ossicles missing or destroyed, malleus present, incus missing or partially destroyed, stapes suprastructure destroyed O3: Three ossicles missing or destroyed or any situation with a fixed stapes footplate Ox: Unknown status of the ossicles	Remark: Add "p" behind when a prosthesis is present (for instance, O2p).

We also recommend the registration of the location of cholesteatoma as follows:

- STAM1CO=1 location
  - STAM2CO=2 locations
  - STAM3CO=3 or more locations, or one of the S locations involved
- Add "r" when a revision surgery in front is performed: rSTAMCO

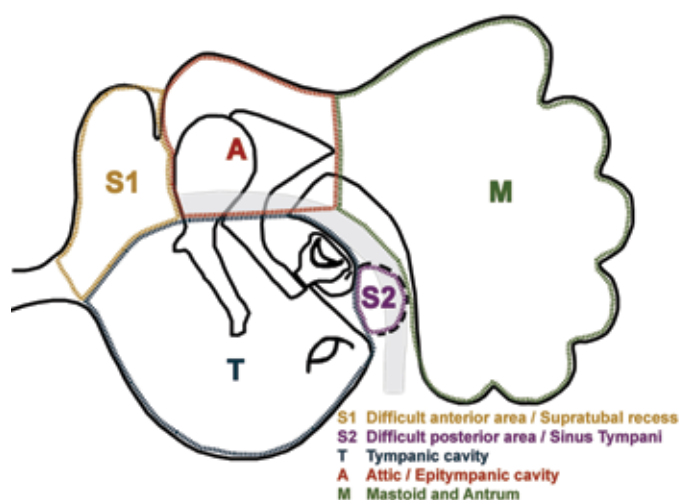
A should be reported. In case a cholesteatoma extends anteriorly to the head of the malleus, S1 should be reported too. The head of the malleus is the most prominent landmark and likely to be visible on CT images with a microscope or endoscope. Further, the other borders are refined following this line of reasoning.

## 2. STAM system is elaborated to STAMCO by inclusion of the status of complications (C) and ossicular chain (O).

Classifications are designed to improve outcome comparison. One of the most important postoperative outcome measures is residual or recurrence of cholesteatoma, in which the location of the cholesteatoma will probably be the most important perioperative parameter. This is perfectly registered in the STAM system. Still, two other postoperative outcome measures, including complications and hearing, are not directly related to the perioperative extent of the cholesteatoma (STAM). As shown in Table 1, we propose including the alphabetic

character C for the presence of pre or perioperative complications. The consensus statement does take complications into account by directly staging them as stage III or IV, but by doing so, information on the perioperative extent of the disease is lost. It is yet to be determined whether the presence of a complication is related to worse postoperative outcome. By omitting the information on the extent of the disease, it may not be possible to demonstrate such a relationship. A better solution is to first implement a standard monitoring option of intracranial and/or extracranial complications, such as our intention with the letter C. It should be noted that cerebrospinal fluid leak (not mentioned in the consensus paper) may be considered an extracranial complication.

In line with the presentation by the Swiss Society of Otolaryngology–Head & Neck Surgery on their proposed classification during the 10<sup>th</sup> International Conference on Cholesteatoma in Edinburgh, 2016, we



**Figure 1.** Further specification of the divisions of the middle ear and mastoid space. See table for further explanation of borders.

additionally suggested including the alphabetic character O for ossicular chain status in the classification during surgery [5]. The status of the ossicular chain is important to report because this represents the impact of the cholesteatoma, and certain ossicles are more important in hearing reconstruction. Extending the classification contributes to correlating hearing-related outcomes with the primary disease process [6]. The relevant aspects of existing classifications, as proposed in a recent review, are in our opinion better represented by the STAMCO system [7].

### 3. To currently postpone staging.

Based on the extent of the cholesteatoma and on the presence of extracranial or intracranial complications, the EAONO/JOS consensus statement proposed to classify cholesteatoma into four stages [1]. This staging system implies a correlation between higher stage and worse outcome. As this correlation has yet to be demonstrated, it seems premature to currently implement this staging system. Therefore, we would like to propose the postponement of staging. In the future, when the classification system is widely implemented and has led to uniformity in reported case series, outcome data can be correlated to the classification. This can serve as the basis of a staging system. This is comparable to the way the internationally accepted TNM classification for malignant tumors has been implemented: first, the TNM classification by anatomical extent of the disease was adopted in 1952. After several years of research, outcomes were published and consensus meetings were held to stage the disease based on classification and outcome (for up-to-date version check [www.uicc.org/resources/tnm](http://www.uicc.org/resources/tnm)).

All in all, we would like to acknowledge the European and Japanese societies for their effort and great work on the classification and staging of middle ear cholesteatoma. It is a big step forward, and we are keen on implementing the classification in our national cholesteatoma study. To facilitate its implementation as a national standard, we propose further refining the borders of divisions by anatomical landmarks and to modify the classification from STAM into STAMCO (S: difficult access Sites; T: Tympanic cavity; A: Attic/epitympanic space; M: Mastoid and antrum; C: Complication status; O: Ossicular chain status).

**Peer-review:** Externally peer-reviewed.

**Conflict of Interest:** Paul Merkus, Robert Jan Pauw, Fleur A. ten Tije and Mariska Stam all disclose that they received financial support from ZonMw.

**Financial Disclosure:** This study was supported by ZonMw (The Netherlands Organisation for Health Research and Development).

### References

1. Yung M, Tono T, Olszewska E, Yamamoto Y, Sudhoff H, Sakagami M, et al. EAONO/JOS Joint Consensus Statement on the Definitions, Classification and Staging of Middle Ear Cholesteatoma. *J Int Adv Otol* 2017; 13: 1-8.
2. Mansour S, Magnan J, Haidar H, Louryan S. Comprehensive and clinical anatomy of the Middle Ear. 1<sup>st</sup> ed. Berlin Heidelberg: Springer-Verlag; 2013.
3. Marchioni D, Molteni G, Presutti L. Endoscopic Anatomy of the Middle Ear. *Indian J Otolaryngol Head Neck Surg* 2011; 63:101-13.
4. Palva T, Ramsay H, Northrop C. Color Atlas of the Anatomy and Pathology of the Epitympanum. Basel: Karger; 2001.
5. Huber A, Caversaccio M, Linder T, Rösli C. "Classification of cholesteatoma" CHOLE2016 congress, Swiss Society of Otolaryngology United Kingdom: Edinburgh; 2016.
6. Meyerhoff WL, Truelson J. Cholesteatoma staging. *Laryngoscope* 1986; 96: 935-9.
7. Rutkowska J, Özgür N, Olszewska E. Cholesteatoma Definition and Classification: A literature review. *J Int Adv Otol* 2017; DOI: 10.5152/iao.2017.3411.

### Authors' Reply

The EAONO/JOS classification and staging system is based on consensus rather than evidence. The staging system is designed to reflect the difficulty in cholesteatoma eradication. In theory, stage 1 disease should have a lower recurrent/residual rate than stage 2 or 3 disease. The value of the JOS staging system has already been published in a multi-center study [1]. There are other outcome parameters that are important for patients, such as dry ear rate, waterproofing rate, and hearing gain. Each of these is its own risk factors, e.g., dry ear and waterproofing are related to the cavity size in relation to the meatus size, postoperative hearing level is related to the ossicular status, mucosa status, and presence of otorrhea at the time of surgery [2]. Designing a single staging system that will encompass all these outcome parameters can only be done by evolution, even if it is possible. It is for the similar reason that cancer staging in general is based on survival rate rather than a multitude of outcome parameters such as quality of life.

The EAONO/JOS steering group designs the current EAONO/JOS system to make it user-friendly and convenient. When surgeons audit their cholesteatoma surgery outcome data, they should include other parameters, such as age, primary vs. revision, mucosal status, ossicular status, reconstruction type, and hearing levels in addition to the EAONO/JOS classification and staging system. The advantage of the current EAONO/JOS staging system is that it is simple and intuitive as well as easy to use in conjunction with other parameters. For example, one can classify a cholesteatoma as occurring in the pars tensa, stage 2, M+I-S-. The proposed STAMCO appears to offer a code describing the extent of the cholesteatoma and ossicular status, rather than an alternative staging system. This is not in conflict with the current EAONO/JOS staging system. I welcome and encourage the

Dutch Cholesteatoma multicenter trial. It is relatively straight forward to translate the STAMCO data to the EAONO/JOS staging system. The EAONO/JOS steering group plans to set up an International Otology Outcome Group as a subcommittee of the Politzer Society to guide the further development of the staging system and encourage international collaboration. When we have a large dataset, we can add or delete certain parameters in the current EAONO/JOS staging system using factor analysis (updated version). We prefer the approach of building on the current staging system to avoid having many parameters to start with and then to remove the redundant ones. It is a project in progress.

I like the anatomical definition of the STAM and the improved diagram provided in the Letter to Editor, which I endorse.

**Matthew Yung, Tetsuya Tono, Ewa Olszewska, Yutaka Yamamoto, Holger Sudhoff, Masafumi Sakagami, Jef Mulder, Hiromi Kojima, Armağan İncesulu, Franco Trabalzini, Nuri Özgirgin**

The Ipswich Hospital NHS Trust, Heath Road, Suffolk, United Kingdom IP4 5PD (MY)  
Department of Otolaryngology-Head and Neck Surgery, University of Miyazaki 5200 Kihara, Kiyotake, Miyazaki 889-1692, Japan (TT)  
Department of Otolaryngology, Medical University of Białystok ul. Skłodowskiej 24 A, 15-276 Białystok, Poland (EO)

Department of Otorhinolaryngology, Jikei University School of Medicine, 3-25-8 Nishi-shinbashi, Minato-ku, Tokyo 105-8461, Japan (YY)

Department of Otorhinolaryngology, Bielefeld Academic Teaching Hospital, Bielefeld, Germany (HS)

Department of Otolaryngology, Hyogo College of Medicine, Hyogo, Japan (MS)

Philip van Leydenlaan 15 Radboud University Hospital, 6500 HB Nijmegen, Netherlands (JM)

Department of Otorhinolaryngology, Jikei University School of Medicine, 3-25-8 Nishishinbashi, Minatoku, Tokyo 105-8461, Japan (HK)

Department of Otolaryngology-Head and Neck Surgery, Eskişehir Osmangazi University School of Medicine, Eskişehir, Turkey (Al)

Department of Otolaryngology, Meyer Children's Hospital, Florence, Italy (FT)

Department of Otolaryngology, Bayındır Hospital, Ankara, Turkey (NÖ)

**Corresponding Address:** Matthew Yung

**E-mail:** matthewyung@btconnect.com

## REFERENCES

1. Matsuda K, Tono T, Kojima H, Yamamoto Y, Sakagami M, Mishiro Y, et al. Practicality Analysis of the Staging System Proposed by the Japan Otological Society for Acquired Middle Ear Cholesteatoma: A Multicenter Study of 446 surgical cases in Japan. *Auris Nasus Larynx* 2017; pii: S0385-8146(16)30528-4. doi: 10.1016/j.anl.2017.02.005. [\[CrossRef\]](#)
2. Yung M. Long-term results of ossiculoplasty: reasons for surgical failure. *Otol Neurotol* 2006; 27: 20-6. [\[CrossRef\]](#)