



## Case Report

# Repair of Tegmen Tympani Defect Presenting with Spontaneous Cerebrospinal Fluid Otorrhea Using the Middle Cranial Fossa Approach

Said Sönmez , Bayram Şahin , Beldan Polat , Şenol Çomoğlu , Kadir Serkan Orhan

Department of Otolaryngology Head and Neck Surgery, İstanbul University School of Medicine, İstanbul, Turkey

ORCID IDs of the authors: S.S. 0000-0003-1982-0386; B.Ş. 0000-0002-3886-4432; B.P. 0000-0002-7908-8329; Ş.Ç. 0000-0003-4632-9218; K.S.O. 0000-0002-8069-940X

Cite this article as: Sönmez S, Şahin B, Polat B, Çomoğlu Ş, Orhan KS. Repair of Tegmen Tympani Defect Presenting with CSF Otorrhea using the Middle Cranial Fossa Approach. J Int Adv Otol 2017; 13: 430-3.

Spontaneous cerebrospinal fluid (CSF) otorrhea frequently occurs without temporal bone trauma, fracture, surgery, or any identifiable causes. It is usually associated with tegmen tympani defects of the temporal bone in adults. The congenital origin theory and the arachnoid granulation theory have been accepted to explain the tegmen tympani defect. Magnetic resonance imaging (MRI) and computed tomography (CT) are used to show the defects, brain tissue, and the meninges. We recently encountered three cases of spontaneous CSF otorrhea with a defect on the tegmental plate of the temporal bone. High-resolution CT (HRCT) scan of the temporal bones showed the tegmen tympani defects. The defects were successfully repaired with temporal muscle fascia or fascia lata graft and fibrin glue using the middle cranial fossa approach via craniotomy.

**KEYWORDS:** Cerebrospinal Fluid otorrhea, tegmen tympani defect, middle cranial fossa, craniotomy

## INTRODUCTION

Cerebrospinal fluid (CSF) otorrhea frequently occurs as a result of trauma, surgery, neoplasm, or congenital malformations <sup>[1, 2]</sup>. Trauma history and meningitis may provide clues for the suspected CSF leakage in patients who report aural fullness, hearing loss, tinnitus, and imbalance <sup>[3]</sup>. Conversely, spontaneous CSF containing middle ear effusion/otorrhea (MEE/OTO) can occur without temporal bone trauma or any prior meningitis episode. There is an important association between spontaneous CSF otorrhea, obesity, and increased intracranial hypertension in adults <sup>[4-6]</sup>. A correct diagnosis can easily be missed, particularly in adult and geriatric patients <sup>[3, 7]</sup>.

Spontaneous adult-onset CSF otorrhea is often associated with tegmen tympani defects. Defects may be congenital or due to aberrant arachnoid granulations <sup>[3, 8]</sup>. According to the arachnoid theory, some arachnoid granulations may not find venous terminations and penetrate the dura mater, which results in defects in the bony tegmental plate of the tympani <sup>[8]</sup>. Otorrhea with tegmen tympani defects can cause hearing loss and predispose to meningitis.

Although symptoms of spontaneous CSF otorrhea are rare, autopsy studies showed that single defects of the tegmen tympani were present in 15%-34% of specimens, and multiple defects occurred in less than 1% of them <sup>[3]</sup>. Some authors reported that 15% of tegmen tympani had fewer than five defects, 6% had between 5 and 10 defects, and 16% had very thin cortical bony plate of the tegmen tympani <sup>[8]</sup>.

Middle ear effusion with conductive hearing loss is the most common presenting symptom in CSF otorrhea. Diagnosis is usually made through ongoing, clear odorless, watery type otorrhea after ventilation tube application or myringotomy in suspected cases. The leakage may vary with various maneuvers that increase intracranial pressure (ICP), such as Valsalva maneuver and jugular vein compression. The diagnosis can be supported by  $\beta$ 2-transferrin, glucose, and  $\beta$ -trace protein analysis in the suspected fluid <sup>[7, 9]</sup>.

**Corresponding Address:** Said Sönmez E-mail: dr.saidsonmez@gmail.com**Submitted:** 15.12.2016 • **Revision Received:** 12.03.2017 • **Accepted:** 04.10.2017 • **Available Online Date:** 14.12.2017

©Copyright 2017 by The European Academy of Otolaryngology and Neurotology and The Politzer Society - Available online at www.advancedotology.org

A radiographic examination greatly helps in achieving the diagnosis. Magnetic resonance imaging (MRI) and computed tomography (CT) are the most common imaging modalities used to determine defect locations [3, 7]. High-resolution CT (HRCT) is used to reveal the bone anatomy and the temporal bone defect, and MRI may be useful if the suspected cause of leak is an encephalocele or meningoencephalocele, but it has the significant disadvantage of poor bone detail. High signal on T2-weighted images (T2WI) and low signal on T1-weighted images (T1WI) within the middle ear or mastoid cavity are compatible with the diagnosis of meningocele; in addition, soft tissue that has an isointensity parallel with the temporal lobe parenchyma is highly suspicious with encephalocele [8]. MRI also allows differentiation of the brain tissue from other common causes of opacification particularly from cholesteatoma [8]. MRI with 3D fast spin-echo (FSE) T2WI and 3D fast imaging employing steady-state acquisition (FIESTA) sequencing is useful in the assessment of patients with CSF fistulae; it is noninvasive, offers excellent anatomic detail, and has no radiation risk [10].

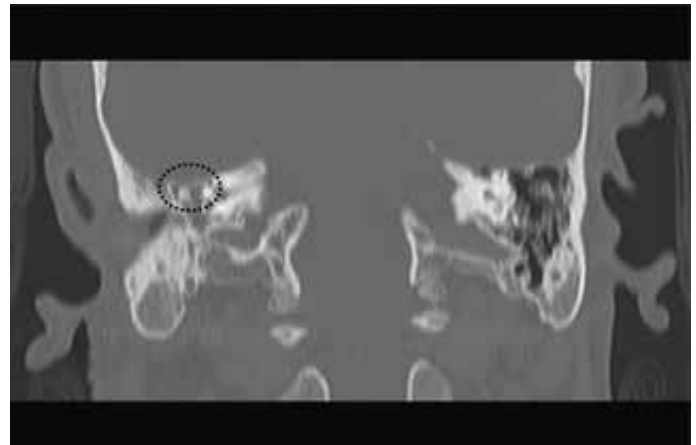Three surgical approaches have been described for the repair of CSF otorrhea. The surgical approaches vary according to the size, location of the defect, hearing status of ear, and the surgeon's experience. Surgical approaches include the transmastoid approach, middle fossa craniotomy, or a combined approach. The transmastoid approach is most suitable for isolated tegmen and posterior fossa defects. However, the anterior and medial sites are not accessible through this approach if hearing is to be preserved. The most widely accepted approach for small defects is the transmastoid approach, which is less invasive. However, more invasive surgical approaches may be needed for large or multiple defects. Middle fossa craniotomy allows a wide exposure for dural and bony defect repair. Wide exposure becomes more important in multiple defects that may be otherwise missed through a transmastoid approach. However, this approach carries the risk of iatrogenic tears of the dura. Many surgeons prefer the combined approach for repair of CSF otorrhea. Identification through the mastoid approach and repair through craniotomy sometimes becomes a better choice. No consensus exists on the optimal procedure and repair technique; however, there is a general agreement that multilayer closure with graft materials significantly reduces the recurrence rate. CSF diversion is a controversial issue in CSF otorrhea treatment. Patients with high ICP can also be managed using CSF diversion [6].

We present three cases of spontaneous CSF otorrhea with defects on the tegmental plates of the temporal bone. The defects were successfully repaired with temporal muscle fascia or fascia lata graft and fibrin glue using the middle cranial fossa approach via craniotomy.

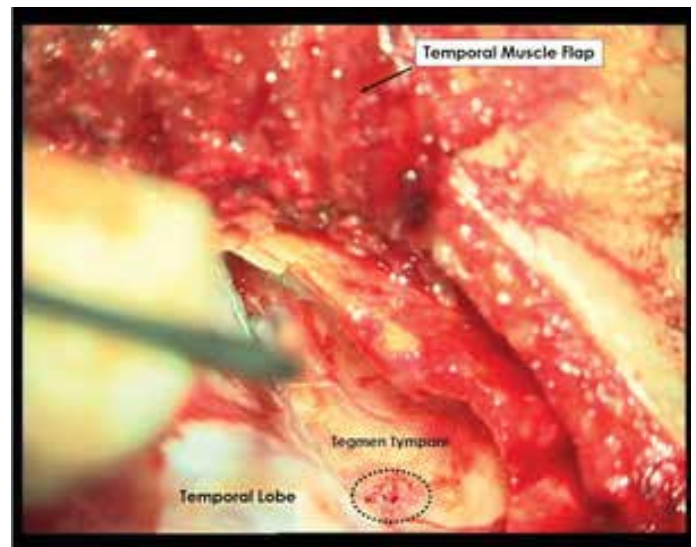
## CASE PRESENTATIONS

### Case 1

A male aged 70 years presented with right-sided otorrhea and hearing loss. He had experienced ear fullness and hearing loss for 4 years. Unsuccessful treatments with oral antibiotics were prescribed several times after being misdiagnosed as having otitis media with effusion. Myringotomy resulting in pulsatile otorrhea and  $\beta$ -2 transferrin positivity of fluid had been suggestive of CSF. The patient had been referred to a neurosurgery clinic, and lumbar drainage was applied



**Figure 1.** Coronal section HRCT. Dashed lines indicate the right-sided tegmen tympani defect

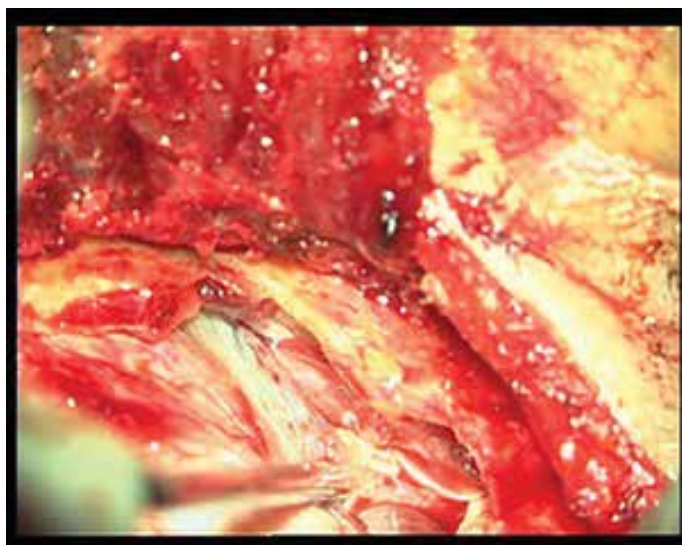


**Figure 2.** Intraoperative view. Dashed lines indicate multiple millimetric bony defects of the tegmen tympani

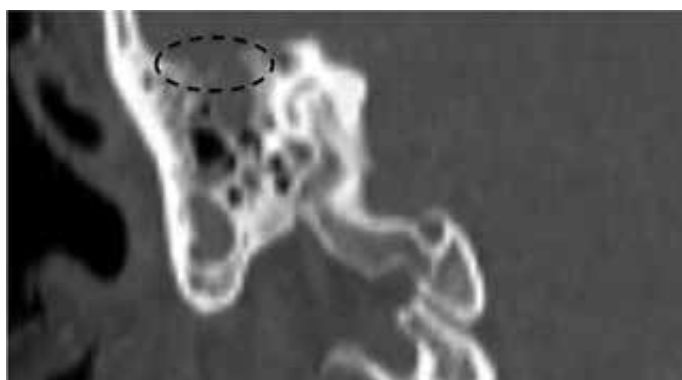
for 15 days with a 15 cm H<sub>2</sub>O CSF opening pressure, but no improvement had been observed.

The patient was referred to our clinic and a physical examination revealed a dull and opaque tympanic membrane on the right side. The tympanogram was type B on the same side and there was a conductive hearing loss. He had no history of trauma or ear surgery. An HRCT scan of the temporal bone revealed a suspected tegmen tympani defect on the right side (Figure 1).

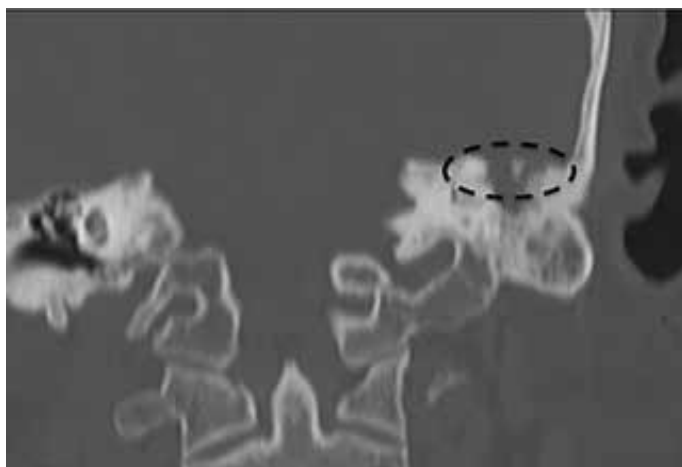The repair of the CSF leak was planned using a middle cranial fossa approach with craniotomy but without CSF diversion because of normal CSF pressure. First, a reverse question mark-shaped incision was made, and the squamous part of the temporal bone was revealed. The dura was exposed by removing a 5×4-cm bony plate. The petrous portion of temporal bone was exposed by proceeding elevation in the extradural space. There was a dural defect near the middle meningeal artery. A bony spine was observed on the temporal bone that corresponded with the location of the dural defect, which was removed by drilling. We also observed other millimetric bony defects on the tegmen tympani (Figure 2). We considered that CSF had



**Figure 3.** Intraoperative view. Defect repair with temporal fascia and autogenous fibrin glue via the middle cranial fossa approach



**Figure 4.** Coronal section HRCT. Dashed lines indicate right-sided tegmen tympani defect



**Figure 5.** Coronal section HRCT. Dashed lines indicate left-sided tegmen tympani defect

reached the middle ear through these defects. The dural and tegmen defects were reconstructed using a temporal muscle fascia graft and autogenous fibrin glue (Figure 3). The removed bone window was then replaced. A temporal muscle flap was constructed and sutured over the bone. A CSF diversion was not performed. We observed no complications during or after surgery. The patient was discharged 4

days after surgery with improvement in his hearing loss. Preoperatively, the pure-tone audiometry threshold in the right ear was measured 45 dB with air conduction and 22 dB with bone conduction, while the postoperative threshold was 30 dB with air conduction and the bone conduction threshold was the same.

### Case 2

A 48-year-old female was admitted to the emergency room with headache and fever. The patient had neck stiffness and was diagnosed as having meningitis by lumbar puncture and CSF examination. After treatment of meningitis in the infectious diseases department, the patient was referred to our clinic because of a suspected right-sided mastoiditis in cranial CT examination. She was diagnosed as having a right-sided tegmen tympani defect through temporal HRCT and underwent operation via the middle cranial fossa approach (Figure 4). Multiple bone defects, with the largest being 1 cm in diameter, were detected on the tegmen tympani. The dural and tegmen defects were repaired by using tensor fascia lata, auricular conchal cartilage grafts, and autogenous fibrin glue. We observed no complications during or after surgery. After the surgery, the patient was followed up for 5 days at the service and was discharged later. Preoperatively, the pure-tone audiometry threshold in the right ear was 43 dB with air conduction and 21 dB with bone conduction, while the postoperative threshold was 23 dB with air conduction and 20 dB with bone conduction.

### Case 3

A 71-year-old female with a history of an operation due to CSF rhinorrhea 3 months ago experienced left ear fullness and otorrhea. The patient had no history of trauma or additional disease other than hypertension and diabetes mellitus. Temporal HRCT revealed a 0.5-cm defect in the tegmen tympani of the left ear (Figure 5).

The patient underwent surgery through the middle cranial fossa approach with the same procedure. The dural and tegmenal defects were repaired using a galeal graft, fat removed from the abdomen and autogenous fibrin glue. The removed bone window was then replaced. Preoperatively, the patient underwent CSF drainage and it was terminated 2 days after surgery. We observed no complications during or after surgery. After the operation, the patient was followed up for 4 days and was discharged with no problems, such as infection and hearing loss. No otorrhea or rhinorrhea was detected in the patient's 1-year follow-up. Preoperatively, the pure-tone audiometry threshold in the left ear was 38 dB with air conduction and 18 dB with bone conduction, while the postoperative threshold was 21 dB with air conduction and the bone conduction threshold was the same.

We obtained written informed consent from the patients.

### DISCUSSION

Spontaneous cerebrospinal fluid leakage usually depends on trauma, surgery, chronic ear disease, or neoplasms. Spontaneous CSF otorrhea is rarely encountered. Persistent MEE, hearing loss, recurrent meningitis, or pulsatile otorrhea after myringotomy may indicate CSF leakage. Although the pathophysiology is not clear, defects are most frequently detected in the tegmen tympani (middle cranial fossa) in patients with CSF otorrhea and less frequently in the posterior fossa<sup>[1]</sup>.



Two theories may explain tegmen tympani defects of the temporal bone without trauma, which include the congenital theory and arachnoid granulations theory. The congenital theory suggests that the tiny openings that occur within the tegmen are due to abnormal embryonic development. These spontaneous tegmen defects typically appear bilaterally [1, 3]. The theory is supported by the knowledge that bony pathways present at birth can persist after birth and become a pathway for pathogens to enter the CSF space. A widely patent cochlear aqueduct, a tympanomeningeal fissure of Hyrtl, or internal auditory canal communication with vestibule are the possible pathways [3].

The arachnoid theory by Gacek et al. [11] suggests that some arachnoid granulations that have failed to find venous terminations during embryonic development may penetrate the dura mater. With advancing age, the granulations enlarge and cause defects in the bony surfaces [1, 3, 8]. This is a way between the CSF space and mastoid air cells. The otorrhea with tegmen tympani defects can cause conductive hearing loss and predispose to meningitis.

In contrast, some demographic characteristics are associated with CSF otorrhea. Middle-aged and obese (body mass index [BMI] >30 kg/m<sup>2</sup>) women with increased ICP or patients with idiopathic intracranial hypertension are affected more than others [1].

MRI and CT are two main imaging modalities for CSF otorrhea. HRCT is the most suited imaging methods for bone anatomy and morphology of the otic capsule [8]. If otorrhea is diagnosed with  $\beta$ 2-transferin, glucose, and  $\beta$ -trace protein analysis, the CT can generally shows bone defects [2, 3]. Stone et al. [12] determined that HRCT showed defects in 30 of 42 patients (71%) with otorrhea. CT cisternography and radionuclide cisternography can be used if a defect is not detected on CT. However, if the leak is with low volume or is intermittent, imaging will give false-negative results; comorbidities of lumbar puncture and radioactive materials should be considered.

MRI is useful to demonstrate dural defects and herniated brain tissue, but it is not adequate for bone defects. High signal on T2WI and low signal on T1WI in the middle ear cavity confirms CSF leakage. Whereas low signal may be due to the herniation of dura through the defect, it is surrounded with a high signal of CSF on T2WI. MRI with gadolinium contrast can demonstrate herniation of an encephalocele through the tegmen on T1WI [5, 8]. As such, MRI is useful for operation planning.

Surgical approaches vary according to the size and location of the tegmental defect and the experience of the surgeon. The most widely accepted approach to small defects is the transmastoid approach, which is minimally invasive. However, posterior fossa leaks can only be approached through the mastoid, and cavity obliteration is usually necessary. For large, multiple or posterior defects, a more invasive surgical approach may be needed. Some defects in tegmen tympani can be repaired through a combined approach without disturbing the ossicular chain. However, more medially and anteriorly located defects makes ossicular disruption inevitable. Hence, the decision is made regarding the hearing status of the surgical ear and healthy ear. Irrespective of the surgical approach preferred, multilayer closure is accepted by many neurotologists [1, 3, 7]. CSF diversion can be an additional management option with surgery, particularly in patients with high BMI and ICP [6, 10]. Diversion or shunting of CSF is not recommended before primary closure of the defect, since this can

predispose to bacterial contamination from the temporal bone and/or mastoid, which may result in meningitis [6].

## CONCLUSION

Spontaneous cerebrospinal fluid (CSF) is rarely seen in adults and it is usually associated with tegmen tympani defects. HRCT is used to show bone anatomy and defects, and MRI is useful to demonstrate dural defects and herniated brain tissue. Transmastoid approach, middle fossa craniotomy, or combined approach are the options of the surgical approach. We operated three patients who had spontaneous CSF otorrhea, using the middle cranial fossa approach via craniotomy.

**Informed Consent:** Written informed consent was obtained from patients who participated in this study.

**Peer-review:** Externally peer-reviewed.

**Author contributions:** Concept - S.S., B.Ş., B.P.; Design - S.S., B.Ş.; Supervision - S.S., B.Ş., B.P.; Resource - S.S., B.Ş., B.P.; Materials - S.S., B.Ş., K.S.O.; Data Collection and/or Processing - S.S., B.Ş., B.P.; Analysis and/or Interpretation - S.S., B.Ş., Ş.Ç.; Literature Search - S.S., B.Ş., B.P.; Writing - S.S., B.P., Ş.Ç.; Critical Reviews - Ş.Ç., K.S.O.

**Conflict of Interest:** No conflict of interest was declared by the authors.

**Financial Disclosure:** The authors declared that this study has received no financial support.

## REFERENCES

1. Boo SH, Goh YB, Han CS. Repair of Spontaneous Cerebrospinal Fluid Otorrhea from Defect of Middle Cranial Fossa. *Korean J Audiol* 2013; 17: 148-51. [CrossRef]
2. Kutz JW Jr, Husain IA, Isaacson B, Roland PS. Management of spontaneous cerebrospinal fluid otorrhea. *Laryngoscope* 2008; 118: 2195-9. [CrossRef]
3. Brown NE, Grundfast KM, Jabre A, Megerian CA, O'Malley BW Jr, Rosenberg SI. Diagnosis and management of spontaneous cerebrospinal fluid-middle ear effusion and otorrhea. *Laryngoscope* 2004; 114: 800-5. [CrossRef]
4. Stucken EZ, Selesnick SH, Brown KD. The role of obesity in spontaneous temporal bone encephaloceles and CSF leak. *Otol Neurotol* 2012; 33: 1412-7. [CrossRef]
5. Brainard L, Chen DA, Aziz KM, Hillman TA. Association of benign intracranial hypertension and spontaneous encephalocele with cerebrospinal fluid leak. *Otol Neurotol* 2012; 33: 1621-4. [CrossRef]
6. Vivas EX, McCall A, Raz Y, Fernandez-Miranda JC, Gardner P, Hirsch BE. ICP, BMI, surgical repair, and CSF diversion in patients presenting with spontaneous CSF otorrhea. *Otol Neurotol* 2014; 35: 344-7. [CrossRef]
7. Marchioni D, Bonali M, Alicandri-Ciufelli M, Rubini A, Pavesi G, Presutti L. Combined approach for tegmen defects repair in patients with cerebrospinal fluid otorrhea or herniations: Our experience. *J Neurol Surg B Skull Base* 2014; 75: 279-87. [CrossRef]
8. Raine C. Diagnosis and management of otologic cerebrospinal fluid leak. *Otolaryngol Clin North Am* 2005; 38: 583-95. [CrossRef]
9. Dutt SN, Mirza S, Irving RM. Middle cranial fossa approach for the repair of spontaneous cerebrospinal fluid otorrhea using autologous bone plate. *Clin Otolaryngol Allied Sci* 2001; 26: 117-23. [CrossRef]
10. Tyagi, I, Syal R, Goyal A. Cerebrospinal fluid otorhinorrhoea due to inner-ear malformations: clinical presentation and new perspectives in management. *J Laryngol Otol* 2005; 119: 714-8. [CrossRef]
11. Gacek RR. Arachnoid granulation cerebrospinal fluid otorrhea. *Ann Otol Rhinol Laryngol* 1990; 99: 854-62. [CrossRef]
12. Stone JA, Castillo M, Neelon B, Mukherji SK. Evaluation of CSF leaks: high-resolution CT compared with contrast-enhanced CT and radionuclide cisternography. *Am J Neuroradiol* 1999; 20:706-12.