
CASE REPORT

Verrucous carcinoma of the auricula: An uncommon lesion

M. Zafer Uguz, MD; Veli Aydogdu, MD; Bilge Turk, MD; Demet Etit, MD

From the First Ear, Nose, and Throat Clinic (M.Z. Uguz, V. Aydogdu, B. Turk) and the Department of Pathology (D. Etit), Izmir Ataturk Training and Research Hospital, Izmir, Turkey

Corresponding author:

Veli Aydogdu, MD,
Basinsitesi M. 172/2 sok. no:3/11
Konak/Izmir, Turkey
Tel: +90 232 2441714
Fax: +902322431530
E-mail: aydogdu.md@gmail.com

Submitted: 19 November 2006
Accepted: 12 August 2007

Mediterr J Otol 2007; 3: 173-175

Copyright 2005 © The Mediterranean

Verrucous carcinoma is a locally invasive and nonmetastasizing variant of squamous cell carcinoma that is characterized by distinct clinical and histologic features. It develops most frequently on the mucous membranes of the oral cavity and larynx. The development of this tumor in the ear is particularly rare. We report a 45-year-old woman who presented with an enlarging malodorous mass on her right auricula. Physical examination revealed a round, lobulated, infected, necrotic mass (5 x 5 x 3 cm) on the anterior surface of the auricula from the helix to the antitragus. The entire mass was surgically removed. The results of histopathologic examination confirmed the diagnosis of verrucous carcinoma, a lesion that rarely develops within the auricula. A full-thickness biopsy is necessary to ensure the correct diagnosis, and surgery is the treatment of choice; the use of radiotherapy remains controversial. A diagnosis of verrucous carcinoma should be considered in any patient with an auricular mass.

Verrucous carcinoma is a locally invasive nonmetastasizing variant of squamous cell carcinoma that is characterized by distinct clinical and histologic features. This lesion must not be confused with conventional squamous cell carcinoma, from which it differs in structural characteristics and prognosis ^[1]. Verrucous carcinoma most frequently develops on the mucous membranes of the oral cavity and larynx ^[2]. It is particularly uncommon for this tumor to develop in the ear.

The clinical presentation of verrucous carcinoma of the ear is similar to that of a conventional squamous cell carcinoma with 1 critical difference: Verrucous carcinomas develop without sex-related predominance in individuals aged 50 to 80 years. A full-thickness biopsy is necessary to ensure the correct diagnosis. The treatment of choice is surgical excision because verrucous carcinomas are less radiosensitive than are typical squamous cell carcinomas ^[2]. In this report, we describe a patient with a verrucous carcinoma of the auricula.

CASE REPORT

A 45-year-old female patient presented with an enlarging malodorous mass on her right auricula. Physical examination revealed a round, lobulated, necrotic, infected mass approximately 5 x 5 x 3 cm in diameter on the auricula from the helix to antitragus (Figure 1). The results of an otoscopic examination and audiologic tests were within normal limits, and no pathologic conditions were noted. Oropharyngeal findings were unremarkable, and the patient exhibited neither cranial nerve deficits nor lymphadenopathy.

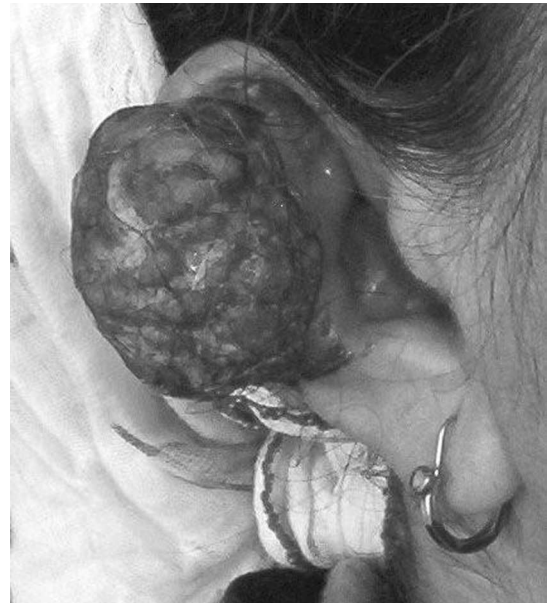

Figure-1: The clinical presentation of a multilobulated necrotic mass at the helix of the right auricula.

Incisional biopsies were performed twice, and histopathologic examination of the biopsy samples revealed seborrheic keratosis. The entire mass was surgically removed, and the results of histopathologic analysis confirmed the diagnosis of verrucous carcinoma (Figure 2).

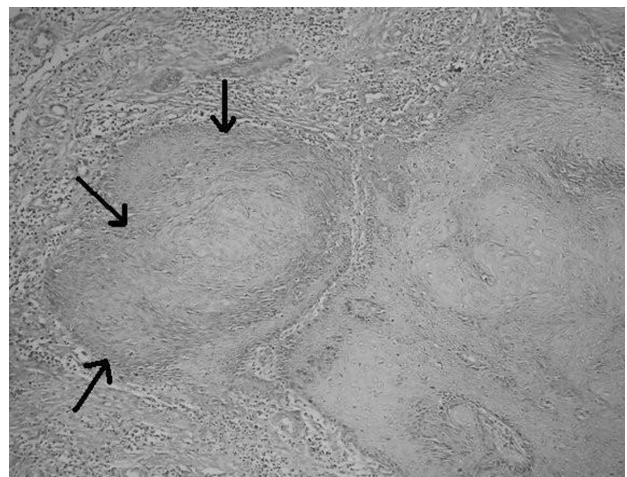


Figure-2: The warty appearance of a verrucous carcinoma with extensive keratinization. The growth pattern, which has well-defined borders, extends into the deep portion of the epidermis (hematoxylin-eosin, original magnification X20).

The patient experienced no postsurgical complications, and at the time of this writing she has been free of disease for more than 9 months

DISCUSSION

The auriculae, which consist primarily of cartilage and skin, are often exposed to excessive sun and extremes of temperature because of their anatomic location. Auricular neoplasms usually present as painless growths^[4]. Verrucous carcinomas are rare tumors with contradictory benign histology but markedly invasive clinical behavior^[2]. Ferlito and colleagues reported that the oral cavity (in particular the buccal mucosa, mandibular alveolar ridge, hard and soft palate, oral tongue, lip, and alveolar ridge) and the larynx (glottis) are the most common sites at which verrucous carcinomas develop^[5]. Carcinomas of the middle ear and mastoid are rare, and a verrucous carcinoma that occurs at those sites is exceptionally rare^[2]. Verrucous carcinomas usually develop without sex-related predominance in individuals aged 50 to 80 years^[1]. The most frequently cited symptoms are chronic discharge, deafness, and otalgia^[2]. Our patient complained of a malodorous mass on the right auricula but not of hearing loss or otalgia.

Repetitive mechanical trauma (a poorly fitting hearing aid, the result of picking at the ear) may contribute to the development of a verrucous carcinoma^[2]. Our patient experienced frequent auricular itching. To our knowledge, no previous report of verrucous carcinoma of the ear has mentioned cigarette smoking or tobacco use in the patients described, but chewing tobacco seems to be strongly associated with the development of verrucous carcinoma at other sites^[2]. Microscopically, these tumors are composed of islands and solid cords of highly differentiated epithelial squamous cells. Anaplasia is absent. The outer aspect of a typical verrucous carcinoma usually consists of a thick layer of keratinized cells arranged in invaginating bulbous acanthotic folds^[2,5].

A full-thickness biopsy, the results of which reveal both the exophytic superficial component and the locally invasive endophytic component of verrucous

carcinomas, is an absolute diagnostic necessity^[1,2]. When viewed via light microscopy, a verrucous carcinoma can be misdiagnosed as a senile keratosis, a hyperkeratosis, a parakeratosis, or a squamous papilloma or as pseudoepitheliomatous or verrucous hyperplasia^[1,6]. Our patient underwent 2 incisional biopsies, the histopathologic examination of which revealed seborrheic keratosis. Surgery is the mainstay of treatment for verrucous carcinomas^[1-3]; the use of radiotherapy remains controversial^[1,2]. In our patient, the entire mass was surgically removed, and the results of histopathologic analysis confirmed the diagnosis of verrucous carcinoma.

CONCLUSION

Verrucous carcinoma of the ear is unusual, and the accurate diagnosis of that tumor depends on the results of full-thickness biopsy. Surgery is the treatment of choice; the role of radiotherapy remains controversial. A diagnosis of verrucous carcinoma should be considered in all patients with an auricular mass.

REFERENCES

1. Rinaldo A, Devaney KO, Ferlito A. Verrucous carcinoma of the ear: an uncommon and difficult lesion. *Acta Otolaryngol* 2004;124:228-30.
2. Pleat JM, Bradley M, Orlando A, Rigby H. Verrucous carcinoma of the temporal bone: a wolf clothed in wool. *Skull Base* 2004;14:39-46.
3. Yeung P, Bridger A, Smee R, Baldwin M, Bridger GP. Malignancies of the external auditory canal and temporal bone: a review. *ANZ J Surg* 2002;72:114-20.
4. Cassisi NJ. Neoplasms of the auricle. In: Cummings CW, editor. *Otolaryngology—head and neck surgery*. 2nd ed. St. Louis, MO: Mosby-Year Book; 1993. p. 2965.
5. Ferlito A, Devaney KO, Rinaldo A, Putzi MJ. Papillary squamous cell carcinoma versus verrucous squamous cell carcinoma of the head and neck. *Ann Otol Rhinol Laryngol* 1999;108:318-22.
6. Konishi E, Nakashima Y, Manabe T, Mazaki T, Wada Y. Irritated seborrheic keratosis of the external ear canal. *Pathol Int* 2003;53:622-6