



Original Article

Cochlear Implant Electrode Array From Partial to Full Insertion in Non-Human Primate Model

Raquel Manrique-Huarte , Diego Calavia , Maria Antonia Gallego , Manuel Manrique

Department of Otorhinolaryngology, University of Navarra Clinic, Pamplona/Navarra, Spain

ORCID IDs of the authors: R.M.H 0000-0003-0781-9679; D.C. 0000-0002-9311-3017; M.A.G. 0000-0002-8726-6017; M.M. 0000-0003-3713-3168

Cite this article as: Manrique-Huarte R, Calavia D, Gallego MA, Manrique M. Cochlear Implant Electrode Array From Partial to Full Insertion in Non-Human Primate Model. J Int Adv Otol 2018; 14(1): 5-9.

OBJECTIVES: To determine the feasibility of progressive insertion (two sequential surgeries: partial to full insertion) of an electrode array and to compare functional outcomes.

MATERIAL and METHODS: 8 normal-hearing animals (Macaca fascicularis (MF)) were included. A 14 contact electrode array, which is suitably sized for the MF cochlea was partially inserted (PI) in 16 ears. After 3 months of follow-up revision surgery the electrode was advanced to a full insertion (FI) in 8 ears. Radiological examination and auditory testing was performed monthly for 6 months. In order to compare the values a two way repeated measures ANOVA was used. A p-value below 0.05 was considered as statistically significant. IBM SPSS Statistics V20 was used.

RESULTS: Surgical procedure was completed in all cases with no complications. Mean auditory threshold shift (ABR click tones) after 6 months follow-up is 19 dB and 27 dB for PI and FI group. For frequencies 4, 6, 8, 12, and 16 kHz in the FI group, tone burst auditory thresholds increased after the revision surgery showing no recovery thereafter. Mean threshold shift at 6 months of follow-up is 19.8 dB ranging from 2 to 36dB for PI group and 33.14dB ranging from 8 to 48dB for FI group. Statistical analysis yields no significant differences between groups.

CONCLUSION: It is feasible to perform a partial insertion of an electrode array and progress on a second surgical time to a full insertion (up to 270°). Hearing preservation is feasible for both procedures. Note that a minimal threshold deterioration is depicted among full insertion group, especially among high frequencies, with no statistical differences.

KEYWORDS: Hearing preservation, full insertion, partial insertion, depth of insertion, cochlear implant

INTRODUCTION

The protection of residual hearing has recently become an important aspect of the cochlear implant (CI) surgery ^[1,2]. This was facilitated by the CI technological progress, development of minimally-traumatic “soft surgery” techniques ^[3], and extension of CI candidacy ^[4]. In fact, hearing preservation improves speech perception of CI users both in quiet and noise as well as the appreciation of music and sound localization ^[5]. In addition, combined electrical and acoustical stimulation has been developed for patients with significant low frequency acoustic hearing ^[6,7]. For the latter, a partial insertion CI may be performed.

Experience has shown that it is possible to preserve residual hearing in up to 90% of patients at the time of activation, reducing to 60%–80% at one year of follow-up ^[8,9]. Although there are still unanswered questions, there are several mechanisms are considered as responsible for immediate or delayed auditory impairment after the insertion of a CI: the early-onset damage, triggered by the insertion trauma ^[10], is followed by a chronic, late-onset inflammatory response as well as vascular pathology in the lateral wall, and this may impact the stria vascularis function ^[11,12].

In cases where hearing deterioration happens after PI and entails a deterioration in hearing performance, some authors pose the need to perform a full insertion in order to improve hearing performance. Therefore, this paper aims to analyze the feasibility and hearing results of progressive insertion from partial to full insertion, in two surgical times, of the same electrode array.

MATERIAL AND METHODS

Experimental Groups

Ten healthy, normal hearing, *Macaca fascicularis* weighing between 2.5 and 4.06 Kg were used in this study. Hearing levels were confirmed preoperatively by measurement of auditory brainstem responses (ABR). Animals were divided into two experimental groups. The group labelled as "partial insertion" (PI) where 8 ears were included (Mf 1-8). In this group a partial insertion of an electrode array (7 electrodes) and followed-up for 6 months. The second group was labelled as "full insertion" (FI) where 8 ears were included (Mf 1-8 contralateral ear). Initially in this group, a partial insertion of an electrode array (7 electrodes) was performed and followed-up for 3 months. Then, a second surgery took place to perform a full insertion of the previous electrode array (14 electrodes in total). Follow-up ended up three months later. Monthly audiological measurements were performed for both groups.

The study was conducted in compliance with European Union Regulation 86/609, and in accordance with protocols approved by the Animal Care and Use Committee of the University of Navarra (005/15).

CI Electrode Array

The electrode array is a preclinical research array^[13], HL14, manufactured by Cochlear Ltd. Specifically, it has 14 electrodes and is 10.5 mm long from the most basal electrode to the distal tip of the array; the tip diameter of the HL14 array is 0.35 mm, increasing to 0.5 mm at the basal electrode that is located 6 mm from the tip of array. Figure 1 shows the HL14 electrode array, including its characteristics and depth reached in case of full insertion of 11.5 mm. It is outlined over the total cochlear length of one of the animals investigated in this study with the animal's tonotopic distribution according to Moody^[14].

Surgical Procedure

Implantation surgery was performed in sixteen ears in the following steps: 1) incision in the region behind the ear and elevation of the musculocutaneous flap; exposure of the cortical mastoid bone located behind the external ear canal, 2) identification of anatomical landmarks: superiorly, linea temporalis, inferiorly, mastoid process; anterior, external auditory canal; posterior, lateral sinus, 3) cortical

mastoidectomy preserving the walls of the external auditory canal intact; first drilling maneuver sought to expose the antrum and identify the incus and the lateral semicircular canal. A suction-irrigation system was used; similar to the system used in humans, 4) posterior tympanotomy to obtain visual control of the round window niche and the promontory, 5) the round window membrane was opened with the beveled edge of a hypodermic needle, 6) insertion of the electrode array was made slowly through the round window. The electrode lead of the implant was placed in the attic-mastoid region. No obliteration of middle ear spaces took place.

For the full insertion group, a revision surgery was performed 3 months later through the same surgical approach. In case middle ear spaces were full of fibrous or ossification tissue it was removed. Once visual control of the electrode array through posterior tympanotomy and round window was achieved, full insertion of the electrode was performed with forceps.

X-ray Analysis

Adequate electrode insertion and depth of insertion was confirmed using a plain X-ray after each surgery and at the end of follow-up.

Animal Anesthesia

Animal immobilization to facilitate its transport to the experimental operating room was induced by an intramuscular injection of ketamine (10 mg/kg), midazolam (1 mg/kg), and atropine sulfate (0.1 mg). For the auditory tests, the animals were intubated with a laryngeal mask and anesthetized using sevoflurane (2%–3 %) mixed with air and oxygen (60%) during the procedure. During the surgical procedure, general anesthesia was induced with propofol (1 mg/kg). Ten micrograms of intravenous fentanyl was administered before the first incision and anesthesia was maintained during the surgical procedure by nitric oxide and oxygen (50%), sevoflurane (2%–3%), and a fentanyl perfusion during surgical procedure (2–4 mg/kg/h) or Ultiva (0.5–0.9 µg/kg/min).

Auditory Evaluation

ABR thresholds were measured before implantation surgery, right after implantation surgery and after light sedation at two weeks after surgery, and each following month up to 6 months in total. SmartEP system (Intelligent Hearing System, Miami, FL, USA) was used with two stimuli: click stimulus and tone burst stimuli. Click stimulus was presented at 1,024 sweeps and rarefaction mode ranging in intensity from 100 to 20 dB SPL. ER2 insert earphones (Etymotic Research, Inc. IL 60007, USA) were located on the right (red for the ear we wanted to study) and left mastoid (blue for the contralateral ear) and the grounding electrode on the forehead. Reference parameters for ABR have been described previously^[15]. The presence or absence of a M4 waveform (equivalent to wave V in humans) determined the auditory threshold. Similar conditions were used to perform ABR thresholds with tone burst stimuli. In this case, stimuli were presented at tone sweeps of 1, 2, 4, 6, 8, 12 kHz, every 20 dB in descending order from 100 dB SPL to 20 dB SPL. The maximum intensity at 16 kHz was 90 dB SPL. Stimuli lasted 12 milliseconds, in rarefaction mode and consisted in 1024 sweeps. The same interpretation criterion was used as in the click stimuli-the presence of M4 wave-and the analysis was double-blinded (performed by two otorhinolaryngology specialists independently and compared by a third).

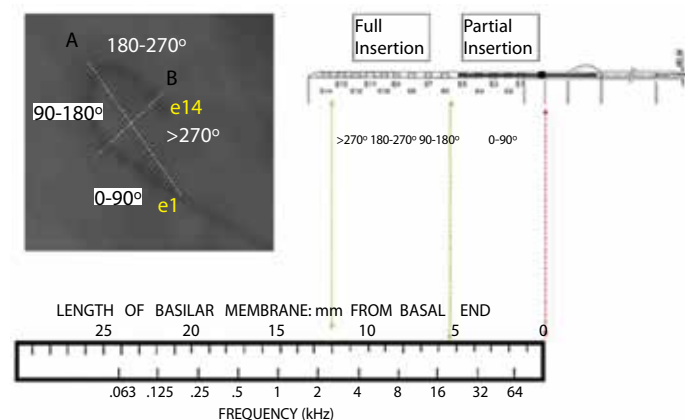


Figure 1. Pure tone auditory (PTA) thresholds for each frequency before and 2 years after CI for the MD and control groups. Mean PTA thresholds are higher for the control group. No statistically significant differences were observed between the MD and control groups.

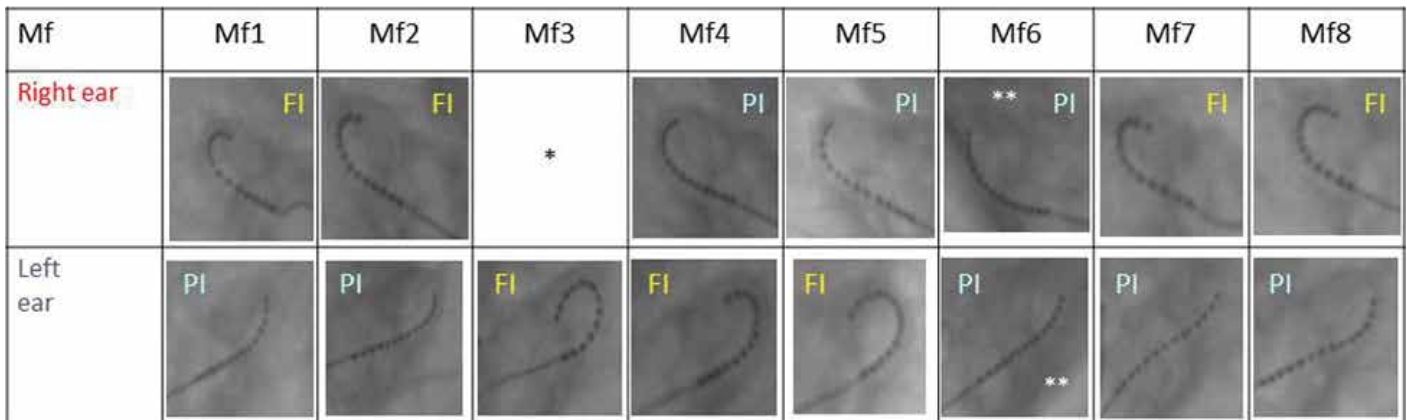


Figure 2. X-rays corresponding to the 16 ears after six months of follow-up.

*Wound dehiscence and macaca removed the electrode array itself. ** Sacrifice before planned follow-up. Abbreviations: FI: full insertion; Mf: macaca fascicularis; PI: partial insertion.

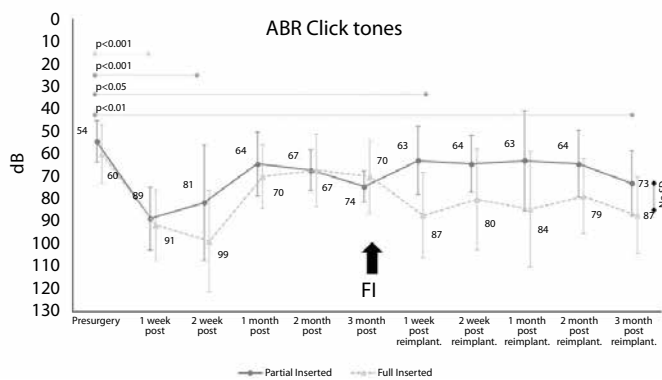


Figure 3. ABR click tones graph shows thresholds at different time points.

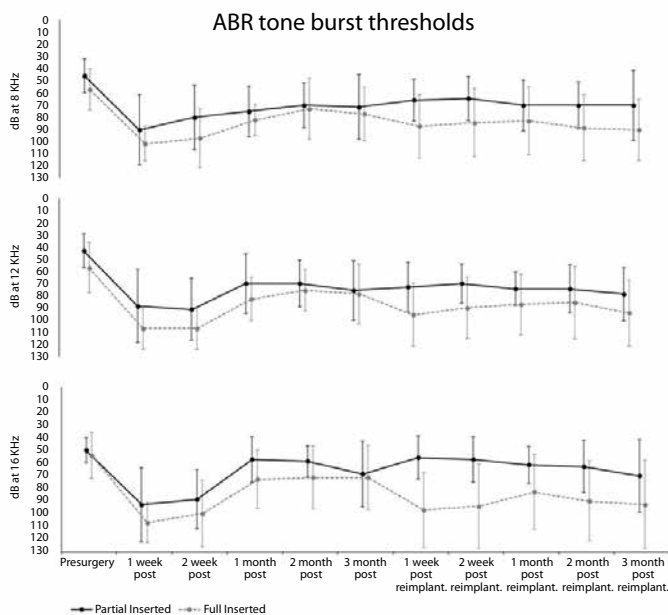


Figure 4. ABR tone burst for frequencies 8, 12 and 16 kHz at different time points.

Statistical Analysis

Data were analyzed using a two-way repeated measures ANOVA with time and ear (PI or FI) as within-subject factors. In case of significant interaction, simple effects (differences between times inside each

group and vice versa) were checked by adjusting p values using Bonferroni's adjustment or Fisher's LSD, respectively. As a post-hoc, the HDSTukey's method was computed to verify the main effects of time.

A p value of <0.100 was considered statistically significant for the interaction, and a p value of <0.050 was considered statistically significant for the main and simple effects. Statistical analyses were conducted using Statistical Packages for Social Sciences 22.0 program (IBM Corp., Armonk, NY, USA).

RESULTS

Surgical Procedure

Surgical procedures were uneventful for all eight macaque (Mf1-8). The only complication observed throughout the 6 month post implant follow-up period was that of Mf3 (left ear partial insertion group), who removed the electrode array itself after 3 months follow-up due to wound dehiscence.

The first phase of the study included implanting the 16 ears of the 8 macaques. Depth of insertion was 5.75 mm in all 16 cases, until electrode#7 reached the round window niche.

The second phase of the study included unilateral complete insertion of 8 ears in the eight macaques, following the same surgical approach. Fibrous tissue occupying the mastoid and posterior tympanostomy was removed so as to identify the round window. Also, a thin layer of fibrosis surrounding the electrode array outside of the cochlea is usually found and removed prior to full insertion. Depth of insertion was 11.5 mm in all 8 cases. No resistance was found in any case.

Figure 2 shows the X-rays corresponding to the 16 ears after six months of follow-up. No migration of the electrode array was observed. Note that Mf6 did not achieve 3 months follow-up, thus just partial insertion was performed in both ears.

Auditory Testing

Normal hearing was confirmed preoperatively using ABR. Results from ABR tests with click tones are shown in Figure 3 and demonstrate the mean thresholds for each group (ear PI group and FI group) and standard deviation at each time point over the study duration.

Mean (SD) threshold shift for PI and FI at 2 weeks after surgery was 27 dB (24.7) and 39 dB (24.8), respectively. The threshold shift at 1-month followup diminishes to 10 dB for each group from the preoperative measurement. For the 16 ears after partial insertion surgery and 3 months follow-up, threshold shift varies from 10 to 20 dB. Once full insertion surgery takes place at 3-month follow-up, threshold for FI group increases to 17 dB more with no recovery for the following three months. Despite this difference, the comparison between the PI and FI groups at 6 months of follow-up showed no statistical differences ($p=0.789$). The difference on time respect to the presurgery values in both the FI and PI groups were statistically significant after the first 2 weeks from first partial insertion surgery ($p<0.001$), after second surgery ($p=0.044$), and at the end of follow-up ($p=0.002$).

Results from the ABR test using tone bursts are shown in Figure 4 for 8, 12, and 16 kHz (mean and SD). Generally, the FI group showed a larger shift after second surgery that remained stable for 3 months of follow-up. After 6 months of follow-up, the mean threshold shifts were lower for the PI group at frequencies 2, 4, 6, 8, 12, and 16 kHz. A comparison between the PI and FI groups did not show significant differences.

DISCUSSION

In the present study, *Macaca fascicularis* was used to acknowledge functional auditory effects of electrode array insertion in different conditions. This experience shows that following soft surgery principles, with no obliteration of middle ear spaces and doing an insertion through the round window, it is feasible to perform a partial insertion of an electrode array (less than 180°) and progress on a second surgical time to a full insertion (up to 270°). This statement entails several assumptions. Firstly that after partial insertion, a 10 to 20 dB hearing deterioration takes place, suggesting that surgical maneuvers and the insertion of an electrode array provoke minimal changes within the cochlea. Secondly, full insertion was performed in all cases with no complications, suggesting that hearing preservation is possible even after a sequential surgery to achieve full insertion. In agreement with our findings, Helbig et al. [16] demonstrated that hearing preservation after reimplantation of 21 to 24 mm electrode array is feasible, even deeper in one case, being able to preserve hearing in all the 3 cases presented. Also, Dunn et al. [17] reported a case of successful hearing preservation after a failed hybrid cochlear implant, suggesting that inner ear might be more robust than once thought.

Another phenomenon observed is threshold deterioration within the first 2 weeks after partial insertion recovering after 1 month. Such changes may be attributed to the presence of liquid in the middle ear that could affect ABR recordings. O'Leary et al. [18] has also described this temporary deterioration within the first 1–2 weeks in guinea pigs, being higher for frequencies 8–32 kHz. However, in our study, again deterioration is depicted within the first 2 weeks after full insertion surgery, with no recovery afterwards. The presence of liquid in middle ear spaces may not justify these findings. Thus, it might be an inflammatory reaction on the first place and a stabilization of such after the revision surgery. In agreement with our findings, Pfingst et al. [19] described a temporary disability on ECAP recordings after cochlear implantation on guinea pigs. Several potential mechanisms are described: an inflammatory reaction that grows over time and then dissipates. Previous studies have described such mechanisms on the macroscopic level or on the molecular level (apoptosis secondary to

oxidative stress or inflammation from the insertion of the cochlear implant) [20]. Trauma due to insertion provokes a weakness or disability of spiral ganglion neurons (SGN) that recovers afterwards. Possible mechanisms underlying this temporary disability include changes in the membrane properties, changes in myelination of the neurons, or die-back and regeneration of the SGN peripheral processes [21]. Immunological reaction to the implant surgery could also contribute to the observed post-surgical changes [22]. Further research is needed to examine the possible biochemical and anatomical changes associated with the observed functional changes.

Once the second surgery took place, full insertion of the electrode entailed a mean hearing deterioration of 17 dB. It may be due to a traumatic insertion related to inflammation and thus molecular injury of the Corti organ, micromechanical changes from contact between electrodes and basilar membrane or fluid displacement [23]. In any case, hearing deterioration affects mainly to higher frequencies, meaning that there might not be a correlation between depth of insertion and such changes. Clinical studies have investigated the relationship of electrode length of insertion on hearing preservation. Results vary between groups. Suhling et al. [24] stated that a shorter electrode resulted in more hearing preservation. While Kisser et al. [25] show hearing preservation for low frequencies with full insertion in a minority of cases. On the contrary Eshraghi et al. [26] and Erixon et al. [27] support that hearing preservation is not associated to depth of insertion, showing that insertion angle and depth of insertion were not correlated to hearing loss.

Results from our study support that is feasible to perform a partial insertion of a conventional electrode array and a progressive insertion to full insertion of the electrode in case needed.

CONCLUSION

It is feasible to perform a PI of an electrode array (less than 180°) and progress on a second surgical time to a FI (up to 270°). Hearing preservation is feasible for both procedures. Note that a minimal threshold deterioration is depicted among the FI group, particularly among high frequencies, with no statistical differences.

Ethics Committee Approval: The study was conducted in compliance with European Union Regulation (86/609) and in accordance with protocols approved by the Animal Care and Use Committee of the University of Navarra (005/15).

Informed Consent: N/A.

Peer-review: Externally peer-reviewed.

Author Contributions: Concept – M.M.; Design – M.M.; Supervision – M.M.; Resource – M.A.G.; Materials – D.C., M.A.G.; Data Collection and/or Processing – D.C., M.A.G.; Analysis and/or Interpretation – R.M.H., M.M.; Literature Search – R.M.H.; Writing – R.M.H.; Critical Reviews – M.M.

Acknowledgements: The authors thank to Yolanda Azcona and Magdalena Zoco anesthesia nurses of the experimental animal house of the University of Navarra.

Conflict of Interest: No conflict of interest was declared by the authors.

Financial Disclosure: The authors declared that this study has received financial support by Cochlear AG.

REFERENCES

- Huarte R.M., Roland Jr JT. Toward hearing preservation in cochlear implant surgery. *Curr Opin Otolaryngol Head Neck Surg* 2014; 22: 349-52. [\[CrossRef\]](#)
- Rask-Andersen H, Liu W, Erixon E, Kinnefors A, Pfaller K, Schrott-Fischer A, et al. Human cochlea: Anatomical characteristics and their relevance for cochlear implantation. *The Anatomical Rec (Hoboken)* 2012; 295: 1791-851. [\[CrossRef\]](#)
- Lehnhardt E. Intracochlear placement of cochlear implant electrodes in soft surgery technique. *HNO* 1993; 41: 356-9.
- Arnoldner C, Lin VY. Expanded selection criteria in adult cochlear implantation. *Cochlear implants Int* 2013; 14: 10-3. [\[CrossRef\]](#)
- Turner CW, Gantz BJ, Karsten S, Fowler J, Reiss LA. The impact of hair cell preservation in cochlear implantation: combined electric and acoustic hearing. *Otol Neurotol* 2010; 31: 1227. [\[CrossRef\]](#)
- Gantz B J, Turner C, Gfeller KE, Lowder MW. Preservation of hearing in cochlear implant surgery: Advantages of combined electrical and acoustical speech processing. *Laryngoscope* 2005; 115: 796-802. [\[CrossRef\]](#)
- Wilson B, Lawson D, Müller J, Tyler RS, Kiefer J. Cochlear implants: some likely next steps. *Annu Rev Biomed Eng* 2003; 5: 207-49. [\[CrossRef\]](#)
- Lenarz T, Verhaert N, Desloovere C, Desmet J, D'hondt C, Gonzalez JC, et al. A comparative study on speech in noise understanding with a direct acoustic cochlear implant in subjects with severe to profound mixed hearing loss. *Audiol Neurotol* 2014; 19: 164-74. [\[CrossRef\]](#)
- Gantz BJ, Dunn C, Oleson J, Hansen M, Parkinson A, Turner C. Multicenter clinical trial of the Nucleus Hybrid S8 cochlear implant: final outcomes. *Laryngoscope* 2016; 126: 962-73. [\[CrossRef\]](#)
- O'Leary SJ, Monksfield P, Kel G, Souter MA, Chang A, Marovic P, et al. Relations between cochlear histopathology and hearing loss in experimental cochlear implantation. *Hear Res* 2013; 298: 27-35. [\[CrossRef\]](#)
- Wright Ch, Roland P. Vascular trauma during cochlear implantation: A contributor to residual hearing loss? *Otol Neurotol* 2013; 34: 402-7. [\[CrossRef\]](#)
- Tanaka Ch, Nguyen-Hyunh A, Loera K, Stark G. Factors associated with hearing loss in a normal hearing guinea pig model of hybrid cochlear implants. *Hear Res* 2014; 316: 82-93. [\[CrossRef\]](#)
- Shepherd T, Verhoeven K, Xu J, Risi F, Fallon J, Wise A. An improved cochlear implant electrode array for use in experimental studies. *Hear Res* 2011; 277: 20-7. [\[CrossRef\]](#)
- Moody D B, Winger G, Woods JH, Stebbins WC. Effect of ethanol and of noise on reaction time in the monkey: Variation with stimulus level. *Psychopharmacology* 1980; 69: 45-51 [\[CrossRef\]](#)
- Alegre M, Gurtubay I, Iriarte J, Ciordia E, Manrique M, Artieda J. Brainstem auditory evoked potentials (baeps) in the cynomolgus macaque monkey: Equivalence with human {BAEPs} and proposal of a new nomenclature. *Hear Res* 2001; 151: 115-20. [\[CrossRef\]](#)
- Helbig S, Rajan GP, Stover T, Lockley M, Kuthubutheen J, Green KM. Hearing preservation after cochlear reimplantation. *Otol Neurotol* 2013; 34: 61-5. [\[CrossRef\]](#)
- Dunn CC, Etler C, Hansen M, Gantz BJ. Successful hearing preservation after reimplantation of a failed hybrid cochlear implant. *Otol Neurotol* 2015; 36: 1628-32. [\[CrossRef\]](#)
- O'Leary SJ, Monksfield P, Kel G, Connolly T, Souter MA, Chang A, et al. Relations between cochlear histopathology and hearing loss in experimental cochlear implantation. *Hear Res* 2013; 298: 27-35. [\[CrossRef\]](#)
- Pfingst B, Hughes A, Colesa D, Watts M, Strahl S, Raphael Y. Insertion trauma and recovery of function after cochlear implantation: evidence from objective functional measures. *Hear Res* 2016; 330: 98-105. [\[CrossRef\]](#)
- Eshraghi AA, Gupta C, Van De Water TJ, Bohorquez J, Granham C, Bas E, et al. Molecular mechanisms involved in cochlear implantation trauma and preservation of hearing and sensory cells by an inhibitor of JNK signal cascade. *Laryngoscope* 2013; 123: 1-4. [\[CrossRef\]](#)
- Pfingst BE, Colesa DJ, Watts MM, Strahl SB, Garadat SN, Schwartz-Leyzac KC, et al. Importance of cochlear health for implant function. *Hear Res* 2015; 322: 77-88. [\[CrossRef\]](#)
- Anderson JM, Rodriguez A, Chang DT. Foreign body reaction to biomaterials. *Semin Immunol* 2008; 20: 86-100. [\[CrossRef\]](#)
- Lo J, Bester C, Collins A, Newbold C, Hapson A, Chambers S, et al. Intraoperative force and electrocochleography measurements in an animal model of cochlear implantation. *Hear Research* 2017
- Suhling MC, Majdani O, Salcher R, Leifholz M, Buchner A, Lesinski-Schiedat A, et al. The impact of electrode array length on hearing preservation in cochlear implantation. *Otol Neurotol* 2016; 37:1006-15. [\[CrossRef\]](#)
- Kisser U, Wunsch J, Hempel JM, Adderson-Kisser C, Stelter K, Krause E, et al. Residual hearing outcomes after cochlear implant surgery using ultra-flexible 28 mm electrodes. *Otol Neurotol* 2016; 37: 878-81. [\[CrossRef\]](#)
- Eshraghi AA, Ahmed J, Krysiak E, Ila K, Ashman P, Telischi F, et al. Clinical, surgical and electrical factors impacting residual hearing in cochlear implant surgery. *Acta Oto Laryngologica* 2017; 137: 384-8. [\[CrossRef\]](#)
- Erixon E, Köbler S, Rask-Andersen H. Cochlear implantation and hearing preservation: results in 21 consecutively operated patients using the round window approach. *Acta Otolaryngol* 2012; 132: 923-31. [\[CrossRef\]](#)