



Original Article

Efficacy of Platelet-Rich Plasma on Fat Grafts in the Repair of Tympanic Membrane Perforations: An Experimental Study

Mehmet Akif Aksoy , Mustafa Fuat Açıkalın , Melek Kezban Gürbüz , Erkan Niyazi Özudoğru , Funda Canaz , Ercan Kaya , Mehmet Özgür Pınarbaşı , Armağan İncesulu, Hamdi Çaklı , Cemal Cingi

Department of Ear Nose and Throat, Gökçöy State Hospital, Ordu, Turkey (MAA)

Department of Ear Nose and Throat, Eskişehir Osmangazi University School of Medicine, Eskişehir, Turkey (MKG, ENÖ, EK, MÖP, AI, HÇ, CC)

Department of Pathology, Eskişehir Osmangazi University School of Medicine, Eskişehir, Turkey (MFA, FC)

ORCID IDs of the authors: M.A.A. 0000-0002-7222-8819; M.F.A. 0000-0003-1708-467X; M.K.G. 0000-0001-7446-9547; E.N.Ö. 0000-0003-4941-4733; F.C. 0000-0002-5642-3876; E.K. 0000-0002-9961-0313; M.Ö.P. 0000-0003-1486-9551; H.Ç. 0000-0002-9345-5527; C.Ç. 0000-0003-3934-5092

Cite this article as: Aksoy MA, Açıkalın MF, Gürbüz MK, Özudoğru EN, Canaz F, Kaya E, et al. Efficacy of Platelet-Rich Plasma on Fat Grafts in the Repair of Tympanic Membrane Perforations: An Experimental Study. J Int Adv Otol 2018; 14(1): 58-62.

OBJECTIVE: We investigated the use of autologous platelet-rich plasma (PRP) to improve the success rate of fat graft myringoplasty in perforated tympanic membranes of rats.

MATERIALS and METHODS: A total of 20 healthy Wistar albino female rats were divided into two groups. In Group 1, the left tympanic membranes were perforated and grafted with a fat graft that was harvested from the inguinal region. In Group 2, the left tympanic membranes were perforated, and a fat graft was also harvested from the inguinal region. Then, the fat was soaked in 0.5 mL PRP and grafted at the perforation. After the procedure, the rats were examined, and the graft situation was assessed at 3, 5, 7, 10, and 14 days. All of the rats were sacrificed 21 days after perforation, and a histopathological examination was made.

RESULTS: We compared fat graft histopathological and otomicroscopic findings between the groups. While we did not observe graft rejections in Group 2, we saw 1 case of graft rejection in Group 1. In the histopathological examination, PRP prevents fat graft resorption by the terms of the adipocyte area, granulation tissue area, and vacuolization area.

CONCLUSION: This study demonstrated the efficacy of fat grafts prepared with PRP on rat tympanic membranes. The fat graft with PRP did not statistically improve the success rate compared to the graft without PRP. Histopathologic findings of the study showed that PRP prevents fat graft resorption. Further studies are needed to further examine the advantages of the graft with PRP.

KEYWORDS: Myringoplasty, fat graft, platelet-rich plasma, tympanic membrane

INTRODUCTION

Perforation of the tympanic membrane is frequently seen with various causes, including trauma and infections. When not completely healed, a perforation can result in serious problems such as recurrent otitis media and, ultimately, hearing loss. Most perforations close spontaneously if they do not present with chronic inflammation; however, in the case of chronic perforations, the tympanic membrane is generally repaired with surgery ^[1, 2]. Today, myringoplasty is considered the most effective and reliable method of healing tympanic membrane perforations. It has been and continues to be used with numerous materials, various surgical techniques, and with different rates of success in healing tympanic membrane perforations ^[3].

The application of fat tissue in the healing of perforations was first described by Ringenberg ^[4]. Since then, it has been frequently used, particularly in small perforations, because fat can be readily obtained from the patient, and this is a minimally invasive procedure ^[5, 6]. However, because the fat graft tissue contains no vessels and is fed through revascularization, improvements in the

This study was presented at the 15th International Meeting of the Mediterranean Society of Otology and Audiology (MSOA), 28-30 April 2016, Cappadocia, Turkey.

Corresponding Author: Mehmet Akif Aksoy; mehmetakifaksoyent@gmail.com

Submitted: 13.04.2017 • **Revision Received:** 23.07.2017 • **Accepted:** 20.09.2017 • **Available Online Date:** 14.12.2017

©Copyright 2018 by The European Academy of Otology and Neurotology and The Politzer Society - Available online at www.advancedotology.org

post-operative period and the connected closing of the perforation depends on local factors in the area where the procedure is undertaken [7].

Platelet-rich plasma (PRP) is the part of the blood plasma derived from a small volume of whole blood subjected to a special centrifugation procedure, and it contains a high concentration of platelets. After it has been activated, growth factors are present with the degranulation of the platelets, and the process of wound healing begins. These growth factors include platelet-derived growth factor (PDGF), insulin-like growth factor (IGF), and vascular endothelial growth factor (VEGF). Because of this, PRP is frequently used today in craniofacial, orthopedic, and neurological surgery [8-11]. PRP increases the success of grafting when fat grafts are applied in various regions of the body [11-14]. Moreover, Erkilet et al. [15] showed positive effects of PRP when used on its own on the tympanic membrane. Given this background, we considered that the combination of PRP with fat graft in repairing tympanic membrane perforations may increase the success rate of grafting.

In this study, we assessed the effects of PRP together with fat grafts in the repair of tympanic membrane perforations and on healing of the tympanic membrane in a rat model. To the best of our knowledge, no previous study has examined PRP mixed with fat for graft myringoplasty.

MATERIALS and METHODS

A total of 20 adult female Wistar albino rats, weighing 250g-300 g, were used. Following anesthesia consisting of intraperitoneal 50 mg/kg ketamine hydrochloride (Ketalar, Pfizer Warner Lambert, ABD) and 5 mg/kg xylazine hydrochloride (Rompun, Bayer, Istanbul, Turkey) injection, 20 rats that had normal tympanic membranes and external auditory canals bilaterally with a microscopic inspection were included. Study protocol had been approved by the IRB, and the animals were handled in accordance with the guidelines prepared by the Animal Use Committee of our institution.

Study Groups

The 20 rats were randomly divided into two groups.

Group 1. Rats were grafted with fat following the myringotomy (control group). An hourglass-shaped graft was applied to the left ear of the 10 rats in this group, immediately after the myringotomy, using fat taken from the inguinal region.

Group 2. Rats were grafted with a combination of PRP+fat following the myringotomy. The fat graft was also taken from the inguinal region for the 10 rats in this group. Immediately after the myringotomy, the fat was soaked in 0.5 mL PRP for 5 minutes. PRP+fat graft was placed in the perforation area and whole area covered with gelfoam.

Obtaining PRP from the Rats

After taking 2 mL intra-cardiac blood from the rats which were to undergo tympanic membrane repair with PRP, the blood was placed in tubes containing sodium citrate (anticoagulant). The anticoagulated blood was subjected to centrifugation (1200 g, 5 min). Three layers were formed: red blood cells at the bottom, the section con-

taining the platelets and the white blood cells in the middle, and platelet-poor plasma at the top. Once the platelet-poor plasma was removed, further centrifugation was performed (1200 g, 10 min). The red blood cells were separated following the second centrifugation, and ~0.5 mL PRP was obtained.

Obtaining Fat Grafts from Rats

The inguinal area of the rats from where the fat grafts were to be removed was shaved, and an incision of ~2 cm was made. Fat grafts at a minimum double size of the perforation (~0.5 g) were removed, and the incision was closed with 5.0 monofilament absorbable sutures.

Myringotomy Procedure

A standard 2 mm myringotomy was applied to the anterior inferior quadrant of the membrane using a paracentesis knife (Trautmann ear knife, Storz, Germany) under microscopic examination.

Follow-Up

The animals were left for a 21-day healing period following the surgical procedure. Water and food (pellets) were available *ad libitum* under standard laboratory conditions. Microscopic control examinations were performed in rats from each group on the 3rd, 5th, 7th, 10th, and 14th days, and the status of the grafts was assessed. Following a lethal dose of intraperitoneal pentothal (Pental sodium, I. E. Ulagay Ilac Sanayi, Istanbul, Turkey; 80 mg/kg) on the 21st day of the microscopic assessment, the animals were decapitated. The bulla of the rats was removed following decapitation, and once opened, the tympanic membranes were removed under direct observation. The tympanic membranes were dissected under microscopic observation and removed with the bone annulus surrounding them, as well as the 1-2 mm external auditory canal.

Histopathological Examination

All of the histopathological evaluations were performed by two expert pathologists. The tympanic membrane was fixed in 10% formalin. The tissues were divided into two sections at the appropriate axis, followed by sampling. Sections of 4 µm were obtained with a microtome. An automatic staining machine (Leica Autostainer XL) was used for hematoxylin and eosin staining procedures. The sections were evaluated by two pathologists under a light microscope (Nikon Eclipse E600). The normal adipocyte area of the fat grafts, granulation tissue area, vacuolization area, and necrotic area were calculated histopathologically as percentages, and the number of mature vessels was determined. Following the histopathological assessment, measurements (such as the area of normal adipocytes) and photographing procedures were performed with the Nikon DSFi2 digital imaging system.

Statistical Analysis

All of the data analyses were performed using the Statistical Package for Social Sciences version 21.0 software (IBM Corp.; Armonk, NY, USA). Continuous quantitative data are expressed as *n*, mean, and standard deviation, whereas qualitative data are expressed as *n*, median, and the 25th and 75th percentiles. The Mann-Whitney U-test was used for variables from independent measurements and which did not display a normal distribution. P values < 0.05 were considered statistically significant.

RESULTS

Otitis media was not observed in any rat. Graft rejection was observed in 1 rat from Group 1 on the 14th day. The grafts in all the rats from Group 2 were intact. The rats in both the groups were decapitated on the 21st day, and their tympanic membranes were removed, followed by histopathological examinations. We examined whether there was an epithelial and mucosal cover on the front and back of the graft. Figure 1-5 show the typical morphology of grafted fat at the 21st day.

There were qualitative differences between the PRP and control groups. In the histomorphometric analyses, Groups 1 and 2 showed different morphology. The degree of normal adipocyte area and

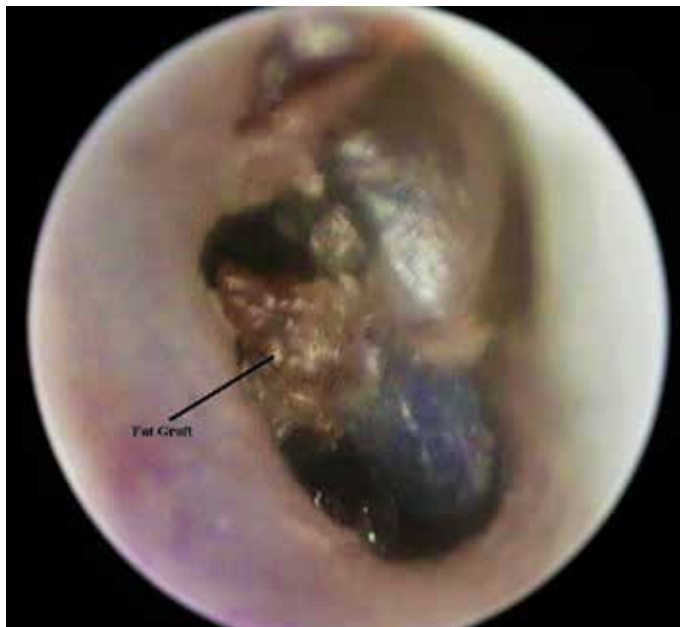

Figure 1. Seventh-day endoscopic image of an ear in which PRP + a fat graft was applied

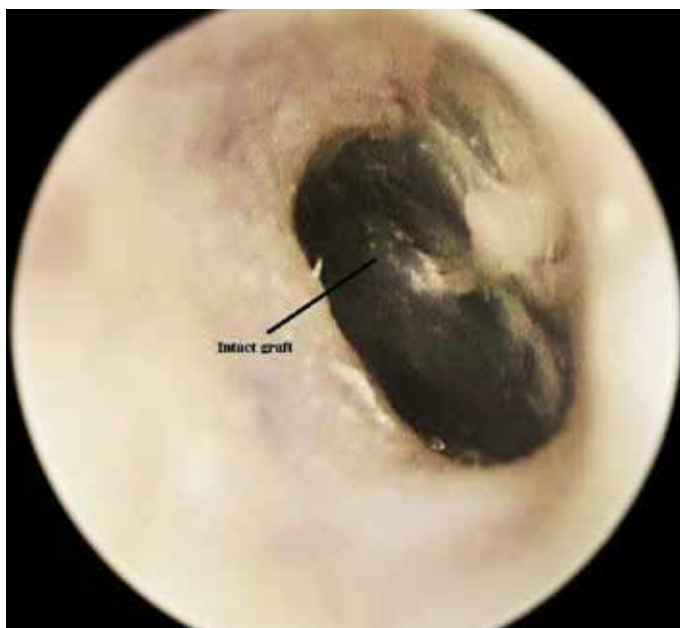

Figure 2. Twenty-first-day endoscopic image of an ear in which PRP + a fat graft was applied. The graft is fully intact

number of mature vessels in PRP group were significantly higher than in the control group. Group 1 showed higher results in terms of granulation tissue area and vacuolization area. Although necrotic areas were lower in PRP group than control group, there was no statistical significance ($p>0.05$; Table 1). Data were compared using the Man-Whitney U-test.

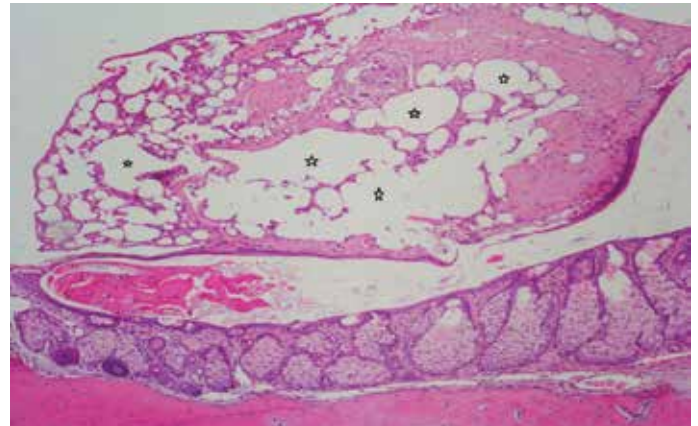


Figure 3. A thick layer consisting of fat cells between the normal external epithelium and internal mucosa is seen in the group subjected to the repair by myringotomy + fat graft (Group 1). Vacuolization (containing ruptured adipocytes) and fibrosis centers (H&E 100x) are present in extensive areas in the fat tissue. The areas marked * show ruptured adipocytes

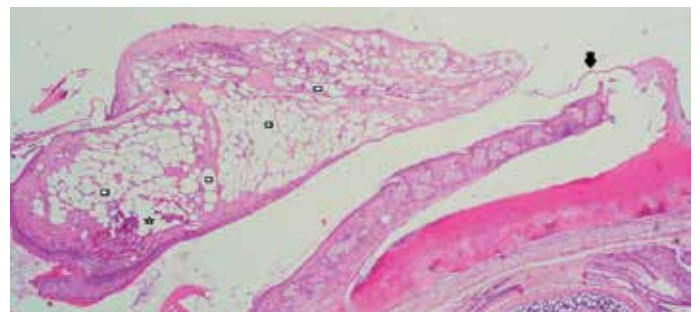


Figure 4. A thick layer consisting of fat cells between the normal external surface epithelium and the internal mucosa is seen in the tympanic membrane of a rat in the group subjected to the repair with PRP + a fat graft following myringotomy (Group 2). Minimal amount of vacuolization (* marked areas) is present in the fat tissue. The black arrow shows tympanic membrane. White squares show normal adipocyte areas. (H&E 40x)

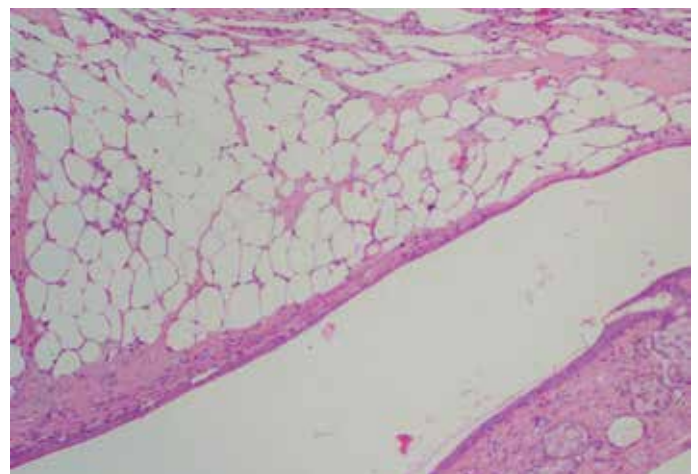


Figure 5. The tympanic membrane of the same rat (Figure 4) at higher magnification (H&E 100x). In this area, there was no vacuolization

Table 1. Comparison of histopathological findings of the tympanic membranes in Groups 1

Area of Fat Graft	Group 1 (Control) (Fat)	Group 2 (Fat+PRP)	p
	Mean+SD* (%)	Mean+SD (%)	
Normal adipocyte area	63.11+29.86	90.81+12.96	0.009
Granulation tissue area	2.94+3.93	0.00+0.00	0.022
Vacuolization area (Ruptured adipocytes)	24.61+29.00	3.29+7.59	0.017
Necrotic area	9.34+12.27	5.90+8.76	0.471
Number of mature vessels	4.22+2.44	6.70+2.67	0.044
*Standard deviation			

DISCUSSION

Tympanic membrane perforations occur frequently, secondary to infections or trauma. Longstanding tympanic membrane perforations may cause hearing loss and middle ear infection, even if they are small in size. Although regeneration and the healing abilities of the tympanic membrane have been shown, chronic perforations are widespread, and there is a need to use grafts to repair them [16]. Ringenber [4] was the first surgeon to use fat tissue at myringoplasty in 1962. After Ringenber, many authors reported good myringoplasty results with the fat graft [17]. The effect of the perforation size has been one of the most important topics for discussion in this report. Many authors believed that the perforation size is the most important factor for the success of FGM procedure [18, 19]. Today, one of the most frequently used graft materials for the repair of small central perforations is fat [20].

When using fat grafts to repair tympanic membrane perforations, it is important to take an amount of fat that is at least double that of the intended graft, because with fat grafts in any region of the body, unexpected graft resorption may occur [21]. Continued dissatisfaction with the survival of independent fat grafts has resulted in the implementation of many different pharmacological efforts together with fat grafts. Many studies have shown positive effects of the application of local growth factors on the volume and survival of the fat graft [22-25]. Insulin, steroids, lidocaine, epinephrine, and selective $\beta 1$ blockers have been used with fat grafts for this purpose, and positive effects on survival of the graft have been shown [26]. Mestre et al. [27] stated in their review that partial resorption occurs in the adipocyte tissue in the first month, due to local hypoxia, following a fat graft, and that the resorption area becomes filled with dermatocysts and fibrous tissues. In our study, the percentage of normal adipocyte area was decreased to 63.11% in the control group. This finding suggested that resorption occurred in the adipocyte tissue consistent with literature reports. We showed the effects on healing when using PRP together with fat grafts in the closure of central perforations. PRP prevents fat graft resorption, and it showed positive effects on the success of the fat graft.

Nakamura et al. [28] created subcutaneous dorsal pockets in their empirical study on rats to show the effects of PRP on fat graft resorption. This study involved two groups, where a fat graft was placed on its own or in combination with PRP. The study looked at the normal adipocyte area, the granulation tissue area, the vacuolization area, the necrotic area, and capillary formation. The authors found that a nor-

mal adipocyte area and capillary formation were significantly higher in the PRP group. We looked at similar parameters in our study, and found that the normal adipocyte area and number of mature vessels were significantly higher in the PRP+fat group (Group 2). However, in contrast to Nakamura et al. [28], we found significantly lower values in the PRP+fat group compared to Group 1 with regard to the granulation tissue area and vacuolization area parameters. We believe that this may have been due to differences in the areas where the grafts were placed (tympanic membrane vs. subcutaneous dorsal pocket).

Studies conducted on fat grafts have revealed that angiogenic factors play an important role in the revascularization of the graft, reducing the apoptosis of fat cells and increasing the survival rate of the graft [29, 30]. It has been found in these studies that VEGF is the most important factor in angiogenesis [26]. When we compared the results between the rats to which we applied fat grafts and the rats to which we applied PRP+fat grafts, we also determined a significant difference in the number of mature vessels. This difference, in favor of the rats that received PRP+fat grafts (Group 2), could be due to the VEGF contained in the PRP.

When examining the literature, it can be seen that PRP is used in craniofacial and orthopedic surgeries, particularly in chronic wounds. According to searches that we performed with Pubmed and Google Scholar, our study is the first to show the positive effects of using PRP together with fat grafts in repair of the tympanic membrane. Our study was conducted by creating acute perforations and showed tympanic membrane and graft improvements. In their review, Wang et al. [31] argued that there was a need to create chronic perforations in empirical studies related to the tympanic membrane. However, Gold et al. [32] stated that when a resection is performed starting from the edges of the remaining membrane during the repair of chronic perforations, the healing process is similar to that of acute perforations. We have a similar view and conducted our study by creating acute perforations. Different information may be obtained on this subject from other studies in the future, conducted by creating chronic perforations.

CONCLUSION

We demonstrated the positive effects of using PRP with fat grafts in the repair of tympanic membrane perforations in a rat model with histopathological findings. We believe that these findings warrant the need for additional experimental studies, as well as clinical trials, in the future.

Ethics Committee Approval: Ethics committee approval was received for this study from Eskişehir Osmangazi University Ethical Committee for Animal Studies (Approval Date: 27.03.2013/Approval No: 334).

Peer-review: Externally peer-reviewed.

Author contributions: Concept - M.A.A., E.N.Ö.; Design - M.A.A., E.N.Ö., Ş.A.İ.; Supervision - H.Ç., C.C.; Resource - M.A.A., M.F.A., E.N.Ö.; Materials - M.A.A., M.K.G., E.K.; Data Collection and/or Processing - M.A.A., E.N.Ö., M.K.G., E.K., M.Ö.P.; Analysis and/or Interpretation - M.F.A., F.C., E.N.Ö., H.Ç.; Literature Search - M.A.A.; Writing - M.A.A., E.N.Ö.; Critical Reviews - H.Ç., C.C., E.N.Ö., Ş.A.İ.

Conflict of Interest: No conflict of interest was declared by the authors.

Financial Disclosure: The authors declared that this study has received no financial support.

REFERENCES

- Villar-Fernandez MA, Lopez-Escamez JA. Outlook for tissue engineering of the tympanic membrane. *Audiol Res* 2015; 5: 117. [\[CrossRef\]](#)
- Saliba I, Knapik M, Froehlich P, Abela A. Advantages of hyaluronic acid fat graft myringoplasty over fat graft myringoplasty. *Arch Otolaryngol Head Neck Surg* 2012; 138: 950-5. [\[CrossRef\]](#)
- Shen Y, Redmond SL, Teh BM, Yan S, Wang Y, Zhou L, et al. Scaffolds for tympanic membrane regeneration in rats. *Tissue Eng Part A* 2013; 19: 657-68. [\[CrossRef\]](#)
- Ringenberg JC. Fat graft tympanoplasty. *Laryngoscope* 1962; 72: 188-92. [\[CrossRef\]](#)
- Dursun E, Dogru S, Gungor A, Cincik H, Poyrazoglu E, Ozdemir T. Comparison of paper-patch, fat, and perichondrium myringoplasty in repair of small tympanic membran perforations. *Otolaryngol Head Neck Surg* 2008; 138: 353-6. [\[CrossRef\]](#)
- Koç S, Akyüz S, Gürbüzler L, Aksakal C. Fat graft myringoplasty with the newly developed surgical technique for tympanic membrane perforation. *Eur Arch Otorhinolaryngol* 2013; 270: 1629-33. [\[CrossRef\]](#)
- Harrison BL, Malafa M, Davis K, Rohrich RJ. The discordant histology of grafted fat: a systematic review of the literature. *Plast Reconstr Surg* 2015; 135: 542-55. [\[CrossRef\]](#)
- Jin R, Zhang L, Zhang YG. Does platelet-rich plasma enhance the survival of grafted fat? An update review. *Int J Clin Exp Med* 2013; 6: 252-8.
- Boyapati L, Wang HL. The role of platelet-rich plasma in sinus augmentation: a critical review. *Implant Dent* 2006; 15: 160-70. [\[CrossRef\]](#)
- Floryan KM, Berghoff WJ. Intraoperative use of autologous platelet-rich and platelet-poor plasma for orthopedic surgery patients. *AORN J* 2004; 80: 675-8. [\[CrossRef\]](#)
- Cervelli V, Gentile P, Scioli MG, Grimaldi M. Application of platelet-rich plasma in plastic surgery: clinical and in vitro evaluation. *Tissue Eng Part C Methods* 2009; 15: 625-34. [\[CrossRef\]](#)
- Pires Fraga MF, Nishio RT, Ishikawa RS, Perin LF, Helene A Jr, Malheiros CA. Increased survival of free fat grafts with platelet-rich plasma in rabbits. *J Plast Reconstr Aesthet Surg* 2010; 63: 818-22. [\[CrossRef\]](#)
- Oh DS, Cheon YW, Jeon YR, Lew DH. Activated platelet-rich plasma improves fat graft survival in nude mice: a pilot study. *Dermatol Surg* 2011; 37: 619-25. [\[CrossRef\]](#)
- Salgerello M, Visconti G, Rusciani A. Breast fat grafting with platelet-rich plasma: a comparative clinical study and current state of the art. *Plast Reconstr Surg* 2011; 127: 2176-85. [\[CrossRef\]](#)
- Erkilet E, Koyuncu M, Atmaca S, Yarim M. Platelet-rich plasma improves healing of tympanic membrane perforations: experimental study. *J Laryngol Otol* 2009; 123: 482-7. [\[CrossRef\]](#)
- Lee SH, Jin SM, Lee KC, Kim MG. Paper-patch myringoplasty with CO2 laser for chronic TM perforation. *Eur Arch Otorhinolaryngol* 2008; 265: 1161-4. [\[CrossRef\]](#)
- Mitchell RB, Pereira KD, Lazar RH. Fat graft myringoplasty in children - a safe and successful day-stay procedure. *J Laryngol Otol* 1997; 111: 106-8.
- Deddens AE, Muntz HR, Lusk RP. Adipose myringoplasty in children. *Laryngoscope* 1993; 103: 216-9. [\[CrossRef\]](#)
- Terry RM, Bellini MJ, Clayton MI, Gandhi AG. Fat graft myringoplasty-a prospective trial. *Clin Otolaryngol Allied Sci* 1988; 13: 227-9. [\[CrossRef\]](#)
- Özgürsoy OB, Yorulmaz M. Fat graft myringoplasty: a cost-effective but underused procedure. *J Laryngol Otol* 2005; 119: 277-9. [\[CrossRef\]](#)
- Konstantinidis I, Malliari H, Tsakirpoulou E, Constantinidis J. Fat myringoplasty as an office based procedure. *Otorhinolaryngol Head Neck Surg* 2010; 42: 25-8.
- Eppley BL, Siders RA, Platis JM, Sadove AM. Bioactivation of free-fat transfers: a potential new approach to improving graft survival. *Plast Reconstr Surg* 1992; 90: 1022-30. [\[CrossRef\]](#)
- Eppley BL, Snyders RV, Winkelmann T, Delfino JJ. Autologous facial fat transplantation: improved graft maintenance by microbead bioactivation. *J Oral Maxillofac Surg* 1992; 50: 477-82. [\[CrossRef\]](#)
- Eppley BL, Sadove AM. A physicochemical approach to improving free fat survival: preliminary observations. *Aesthetic Plast Surg* 1991; 15: 215-8. [\[CrossRef\]](#)
- Yuksel E, Weinfeld AB, Cleek R, Wamsley S, Jensen J, Boutros S, et al. Increased free fat-graft survival with the long-term, local delivery of insulin, insulin-like growth factor-I, and basic fibroblast growth factor by PLGA/PEG microspheres. *Plast Reconstr Surg* 2000; 105: 1712-20. [\[CrossRef\]](#)
- Seyhan N, Alhan D, Ural AU, Gunal A, Avunduk MC, Savacı N. The effect of combined use of platelet-rich plasma and adipose-derived stem cells on fat graft survival. *Ann Plast Surg* 2015; 74: 615-20. [\[CrossRef\]](#)
- Serra-Mestre JM, Serra-Renom JM, Martinez L, Almadori A, D'Andrea F. Platelet-rich plasma mixed-fat grafting: a reasonable pro-survival strategy for fat grafts? *Aesthetic Plast Surg* 2014; 38: 1041-9. [\[CrossRef\]](#)
- Nakamura S, Ishiara M, Takikawa M, Murakami K, Kishimoto S, Nakamura S, et al. Platelet-Rich Plasma (PRP) Promotes Survival of Fat-Grafts in Rats. *Ann Plast Surg* 2010; 65: 101-6. [\[CrossRef\]](#)
- Nishimura T, Hashimoto H, Nakanishi I, Fukurawa M. Microvascular angiogenesis and apoptosis in the survival of free fat grafts. *Laryngoscope* 2000; 110: 1333-8. [\[CrossRef\]](#)
- Hausman GJ, Richardson RL. Adipose tissue angiogenesis. *J Anim Sci* 2004; 82: 925-34. [\[CrossRef\]](#)
- Wang AY, Shen Y, Wang JT, Friedland PL, Atlas MD, Dilley RJ. Animal models of chronic tympanic membrane perforation: a "time out" to review evidence and standardize design. *Int J Pediatr Otorrhinolaryngol* 2014; 78: 2048-55. [\[CrossRef\]](#)
- Gold SR, Chaffoo RA. Fat myringoplasty in the guinea pig. *Laryngoscope* 1991; 101: 1-5. [\[CrossRef\]](#)