

ORIGINAL ARTICLE

A New Staging System for Tympano-mastoid Cholesteatoma

Aziz Belal, Mahmoud Reda, Ahmed Mehana, Yousef Belal

Alexandria Ear Hospital – Alexandria – Egypt (AB, MR, AM, YB)

Objective: Objective: To present a new staging system of tympano-mastoid cholesteatoma that is based on the primary site of pathology in the middle ear (T), its spread to the mastoid (M), and to the surrounding structures either cranial, intra- or extracranial, i.e. presence of complications (C). The TMC staging system is based on correlation of preoperative otoscopy findings with CT examination of the temporal bone.

Setting: Tertiary Care Center.

Patients: We included 120 patients of tympano-mastoid cholesteatoma diagnosed preoperatively, staged and correlated with intraoperative findings.

Results: Preoperative findings has also been correlated with intraoperative findings in 120 consecutive cases operated in the last five years. In 87 percent, pre-operative and intra-operative staging correlated well.

Conclusion: The TMC staging system of cholesteatoma paves the way to a logical roadmap for functional surgery of the middle ear and mastoid, as well it makes the comparison of clinical studies about cholesteatoma meaningful.

Submitted : 06 October 2011

Accepted : 01 January 2012

Introduction

Surgical strategy of tympano-mastoid cholesteatoma may be based on factors related to the patient, surgeon, or disease. Patient's factors include general factors like age, general medical status, occupation, and availability for follow ups. Local factors like status of hearing, only hearing ear, bilateral cholesteatoma, mastoid pneumatization, eustachian tube function, etc. Surgeon's factors include preference and training of the surgeon at a particular time, ie. surgeon's choice. Factors related to the disease include the anatomical site of origin, paths of spread inside and outside the temporal bone, histological characteristics and biological behavior of cholesteatoma. Pathology seems to be the most logical way to outline a surgical strategy for cholesteatoma.^[1,2,3]

Why Staging Cholesteatoma?

Reviewing the techniques used to manage middle ear cholesteatoma showed that priority was often given to

the mastoid, rather than the middle ear.^[3,4,5,6] Furthermore, most of temporal bone dissection courses around the world emphasizes mastoidectomy as the key for chronic ear surgery. As a result, most of the ENT residents and trainees can do an excellent mastoidectomy and less than acceptable middle ear dissection. However, histopathologic and clinic-operative studies has shown that the involvement of middle ear is much higher than the mastoid in primary and revision cholesteatoma cases.^[7,8,9,10,11] Thus, we need a new concept that is based on tailoring the surgical technique according to the site of the pathology and its extensions. Comparison of clinical and operative studies about tympano-mastoid cholesteatoma always had the problem of finding a "standard" to make a meaningful comparison. Terms of small, big, and huge cholesteatomas made comparison between the different studies like comparing apples to oranges. A standard staging system will definitely solve this problem.

Corresponding address:

Alexandria Ear
Lomomba St. – Al-Shalalat – Alexandria - Egypt
Phone: 0020123363987
E-mail: mahmouredda99@yahoo.com

Attempts to stage tympano-mastoid cholesteatoma:

The classical etiological classification^[7] into congenital, primary acquired, and secondary acquired cholesteatoma is an etio-pathological classification and describes well the site of origin of cholesteatoma, its paths of spread and histological behavior, but has little clinical significance.

Tos^[8] otoscopically classified cholesteatoma into attic type in the pars flaccida of the ear drum, sinus cholesteatoma starting as a postero-superior retraction or perforation of the pars tensa and extending to the tympanic sinus, posterior tympanum and beyond, and tensa cholesteatoma presenting as retraction and adhesion of the entire pars tensa involving the tympanic orifice of the Eustachian tube (may also extend further into the attic). Tos^[12] latter modified his classification into: attic, pars tensa I (Marginal disease), and pars tensa II (Central disease) cholesteatomas. Meyerhoff and Truelson^[13] classified cholesteatoma into primary acquired, secondary acquired, tertiary acquired, and congenital.

Saleh and Mills^[14] introduced the Site-Ossicles-Complications (SOC) classification System . It can be summarized in the following:

S1: if the cholesteatoma is restricted to the site where it had started

S2: when the disease extends to the other site

S3: if it affects three sites

S4: if it is installed in four sites

S5 : cases in which the primary site is affected plus four or more are also involved

Authors distinguished seven sites used to this classification: attic and antrum, middle ear, mastoid, auditory tube, labyrinth and middle fossa.

O0: if the ossicle chain is intact

O1: if incus is eroded and without chain discontinuity

O2: if incus and stapes suprastructures are eroded

O3: if the malleus head and incus are absent and stapes superstructure if eroded.

C0: when there is no complications

C1: if there is one complication

C2: if there are two or more complications.

As to complications, the authors considered lateral semicircular canal fistula, facial palsy, total sensorineural auditory loss, sinus thrombosis and intracranial invasion.

We thought we still need an easy reliable clinical staging system that can be applied to every case of tympano-mastoid cholesteatoma, can be correlated with intraoperative findings, can work as a roadmap for functional surgery of the middle ear and mastoid, can objectively compare clinical studies about cholesteatoma.

New Staging System for Tympano-mastoid Cholesteatoma:

We designed a staging system of tympano-mastoid cholesteatoma from stage 1 to stage 5 depending on the site of disease in the tympanic cavity (T) the mastoid cavity (M), and the presence of any complication (C). Staging of any case is made according to the office clinical (otoscopic \ microscopic\ endoscopic) examination, the radiologic study (axial, coronal, and sagittal reconstruction views of high definition CT Petrous bone), and the clinico-radiological correlation. (Table 2, Fig. 1)

Case Reports

Case 1:

40 years old patient presented with recurrent discharging from the right ear.

Otосcopy: attic cholesteatoma and small polyp on one side of the head of malleus, and normal meso-tympanum (T1a)

CT scan: showed attic cholesteatoma with involvement of the mastoid cavity only in the antrum (M1) (Fig.2)

There was no clinical or radiological manifestation of complications (C0)

Staging: T1M1C0 = Stage 3, intra-operative findings were corresponding to TMC staging.

Table 1. TMC Staging system of tympano-mastoid cholesteatoma.

(T) Tympanic cavity involvement:

T0: No tympanic cavity involvement

Trp: Retraction pocket (precholesteatoma)

T1: cholesteatoma involving one side of one region

T1a: one side of epitympanum

T1b: one side of mesotympanum

T2: cholesteatoma involving both sides of one region

T1a: both sides of epitympanum

T1b: both sides of mesotympanum

T3: Cholesteatoma extending from one region of the middle ear to another (vertical spread)

T4: Holotympanic cholesteatoma filling the whole middle ear

Regions (epity- or meso- , and hypotympanum)

Sides (anterior or posterior in relation to a line along handle of malleus)

(M) Mastoid cavity involvement:

M0: No mastoid cavity involvement

M1: Cholesteatoma extending to the mastoid antrum only

M2: Cholesteatoma extending to mastoid cavity

(C) Presence of complications:

C0: uncomplicated Cholesteatoma

C1: cranial or extracranial complication

C2: intracranial complications

Stages

| 1 | 2 | 3 | 4 | 5 |
|-------------|----------|-------------------------|---|----------------|
| Trp-1 M0 C0 | T2 M0 C0 | T3 M0 C0 Trp-3 M1 C0 | T4 M0 C0 Any T M2 C0 Any T Any M C1 | Any T Any M C2 |

T= Tympanic M= mastoid C= complication rp = retraction pocket

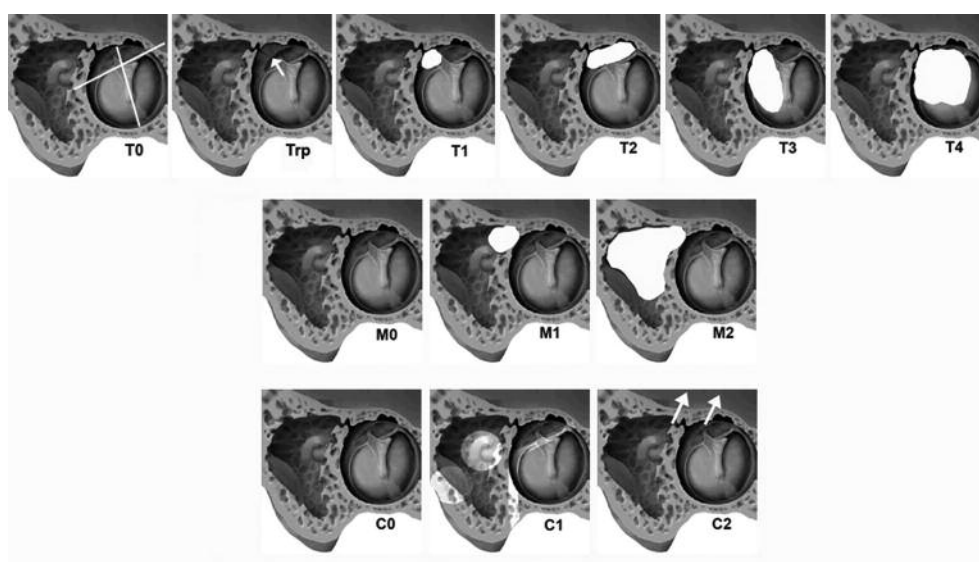


Figure 1. Staging system of tympano-mastoid cholesteatoma.

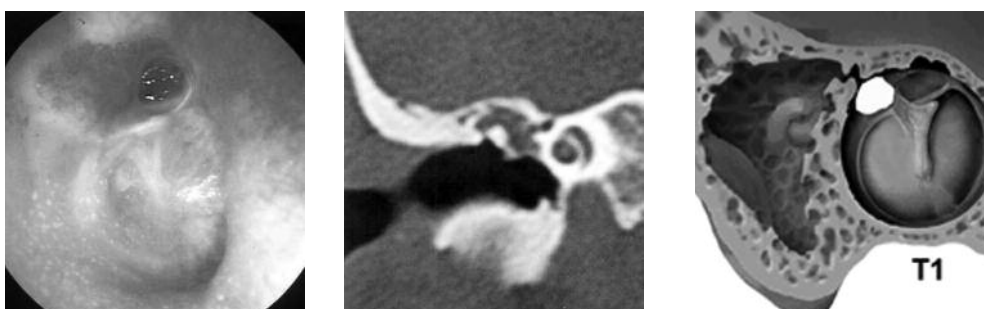


Figure 2. Otoloscopic and CT findings of case 1.

Case 2:

24 years old male patient presented with right hearing loss and occasional ear discharge.

Otology: showed a white pearly mass behind an intact tympanic membrane (T3)

CT scan: showed a soft tissue mass in the tympanic cavity, with well aerated mastoid (M0). The mass was eroding the basal turn of the cochlea (C1). (Fig.3)

Staging: T3M0C1 = Stage 4, intra-operative findings were corresponding to TMC staging.

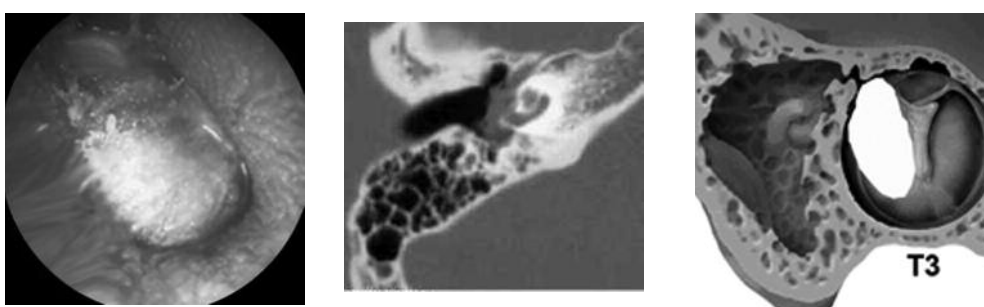


Figure 3. Otoloscopic and CT findings of case 2.

Case 3:

35 years old male patient presented with persistent foul-smelling intermittent discharge from the right ear.

Otology: showed cholesteatoma involving the whole tympanic cavity (T4)

CT scan: showed cholesteatoma filling the whole mastoid cavity (M2)

There was no clinical or radiologic manifestation of complications (C0) (Fig.4)

Staging: T4M2C0 = Stage 4, intra-operative findings were corresponding to TMC staging.

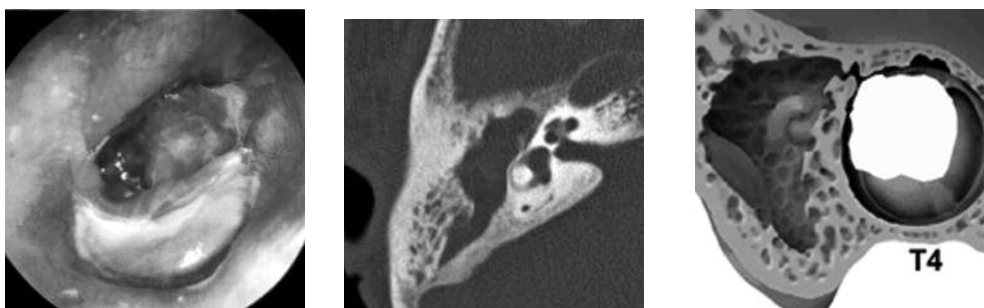


Figure 4. Otoloscopic and CT findings of case 3.

Correlation of pre- and intra-operative findings:

120 cases of tympano-mastoid cholesteatoma examined and operated at Alexandria Ear Hospital, Egypt in the period 2005 – 2010 were included in this study. Cases were examined pre-operatively (otoscopy, microscopy, and endoscopy), CT scanned (coronal and sagittal views), then pre-operatively staged according to the TMC staging system. Cases were operated upon

then staged again according to the intra-operative findings. Staging correlated well in 87 percent of cases. Pre-operative staging under-estimated the size of cholesteatoma in 11 percent of cases, and over-estimated it in one percent of cases. Table 2 summarizes the pre- and intra-operative findings in these cases. Our study has been performed in comply with the ethical principles of Alexandria Faculty of Medicine board.

Table 2. Comparison of pre- and intra-operative findings.

| Stage | No. of Cases | Good Correlation | Under-estimated Cases | Over-estimated Cases | % Correlation | Average Correlation |
|---------------------------|--------------|------------------|-----------------------|----------------------|---------------|---------------------|
| T1 | 5 | 5 | - | - | 100% | 87.3% |
| T2 | 42 | 40 | 2 | - | 95% | |
| T3 | 58 | 40 | 16 | 2 | 68% | |
| T4 | 15 | 13 | 1 | 1 | 86.5% | |
| MO | 37 | 18 | 9 | - | 66.6% | 77.7% |
| M1 | 39 | 20 | 9 | 1 | 74% | |
| M2 | 54 | 50 | - | 4 | 92.5% | |
| C0 | 115 | 104 | 11 | - | 90% | 96.6% |
| C1 | 3 | 3 | - | - | 100% | |
| C2 | 2 | 2 | - | - | 100% | |
| Total No. of Cases | 120 | 87% | 11% | 1% | | |

Conclusion

There are many advantages to the TMC staging system. It is a simple clinico-radiological system that can be applied by any clinician or resident. Because there is high correlation between pre- and intra-operative findings, TMC staging can be easily used to plan a roadmap of functional surgery in cases of tympano-mastoid cholesteatoma. Furthermore, it standardizes and simplifies the terminology used to describe a case of tympano-mastoid cholesteatoma. Thus, it facilitates a reliable type-specific comparison of published data reporting the results of tympano-mastoid surgery.

References

- Graham M, Delap T. Closed tympanomastoidectomy. *Otolaryngol Clin North Am.* 1999, 32:547-55.
- Syms M, Luxford W. Management of cholesteatoma: status of the canal wall. *Laryngoscope.* 2003,113:443-8.

- Kapur R. Causes of failure of combined approach tympanoplasty in the treatment of acquired cholesteatomas of the middle ear and the mastoid. *J Laryngol Otol.* 1995, 109:710-2.
- Reddy T, Dutt S, Sangeeta M. Transcanal atticoidotomy and transcortical mastoidectomy for cholesteatoma: the farrior-olaizola technique revisited. *Ann Otol Rhinol Laryngol.* 2001,110:739-45.
- Uzun C, Yagiz R, Tas A, Adali M, Koten M, Karasalihoglu A. Combined Heermann and Tos (CHAT) technique in cholesteatoma surgery: surgical technique and preliminary results. *J Laryngol Otol.* 2005, 119:429-35.
- Dornhoffer J. Retrograde mastoidectomy with canal wall reconstruction: a follow-up report. *Otol Neurotol* 2004, 25:653-60.
- Belcadhi M. Predictive factors of recurrence in pediatric cholesteatoma surgery. *J Int. Adv. Otol.* 2008, 4:118-24.

8. Lau T, Tos M. Long-term Results and Recurrence Rate. *Arch Otolaryngol Head Neck Surg.* 1988; 114:1428-34.
9. Sethom A, Akkari K, Dridi I. Preoperative CT Scan in middle ear cholesteatoma. *Tunis Med.* 2011; 89(3):248-53.
10. Alzoubi F, Odat HA, Al-Balas H. The role of preoperative CT scan in patients with chronic otitis media. *Eur Arch Otorhinolaryngol.* 2009; 266:807-9.
11. Williams M, Ayache D. Imaging in adult chronic otitis. *J Radiol.* 2006; 87:1743-55.
12. Tos M, Lau T. Late results of surgery in different cholesteatoma types. *ORL J Otorhinolaryngol Relat Spec.* 1989; 511:33-49.
13. Meyerhoff WL, Truelson J. Cholesteatoma staging. *Laryngoscope.* 1986; 96:935-9.
14. Saleh H, Mills R. Classification and staging of cholesteatoma. *Clin Otolaryngol Allied Sci.* 1999; 24:355-9.